

EMBRYOLOGY PRACTICAL LECTURE - 13 - DEVELOPMENT OF THE CVS & DIGESTIVE SYSTEM

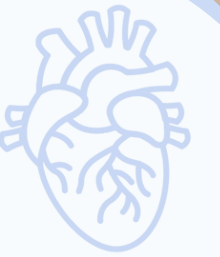EDITED BY



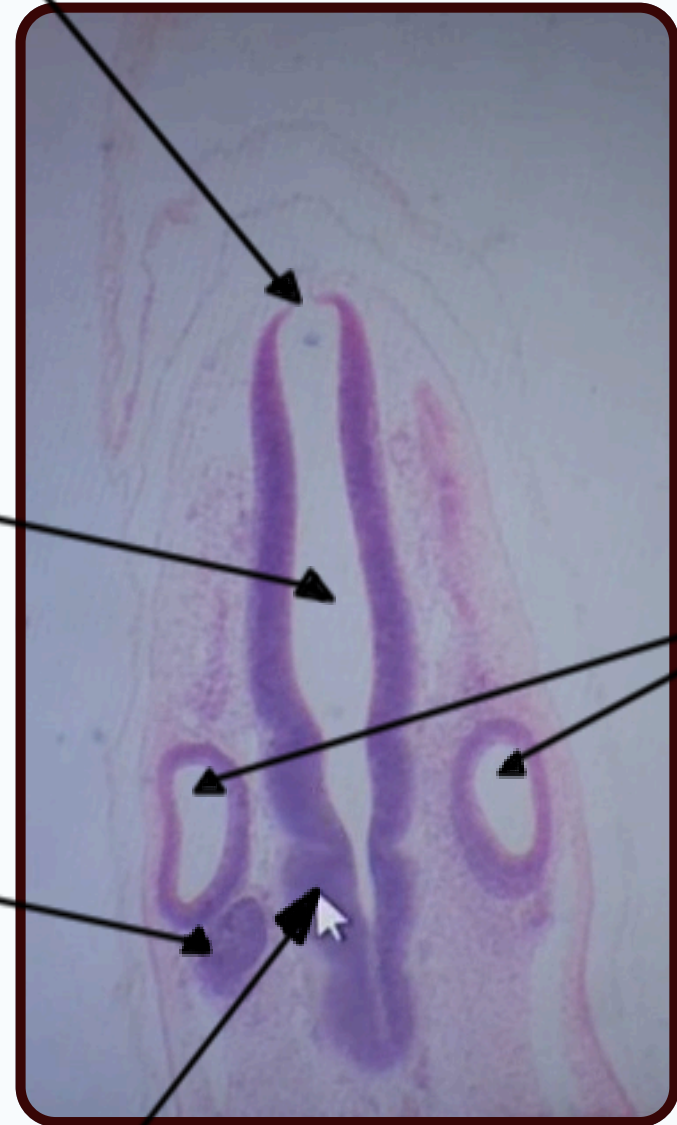
© ALL COPYRIGHT ARE RESERVED FOR
SATURN MEDIC AND ARECH

WWW.SATURNMEDIC.COM

DEVELOPMENT OF THE CVS & DIGESTIVE SYSTEM



Tela choroidea



Neural tube

Ear (auditory) vesicles (otocysts)

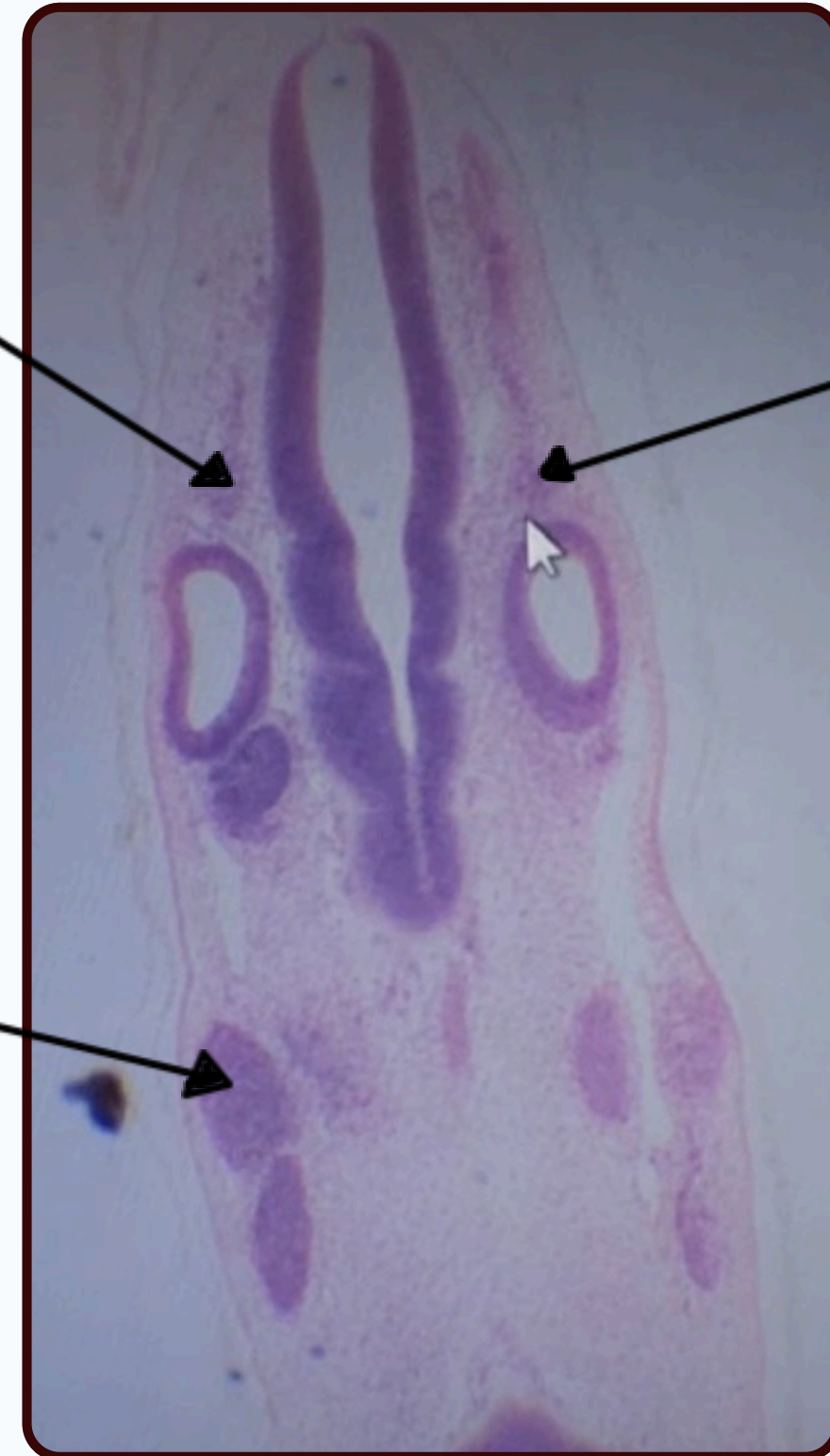
Acoustico facialis ganglion

Myelecephalon

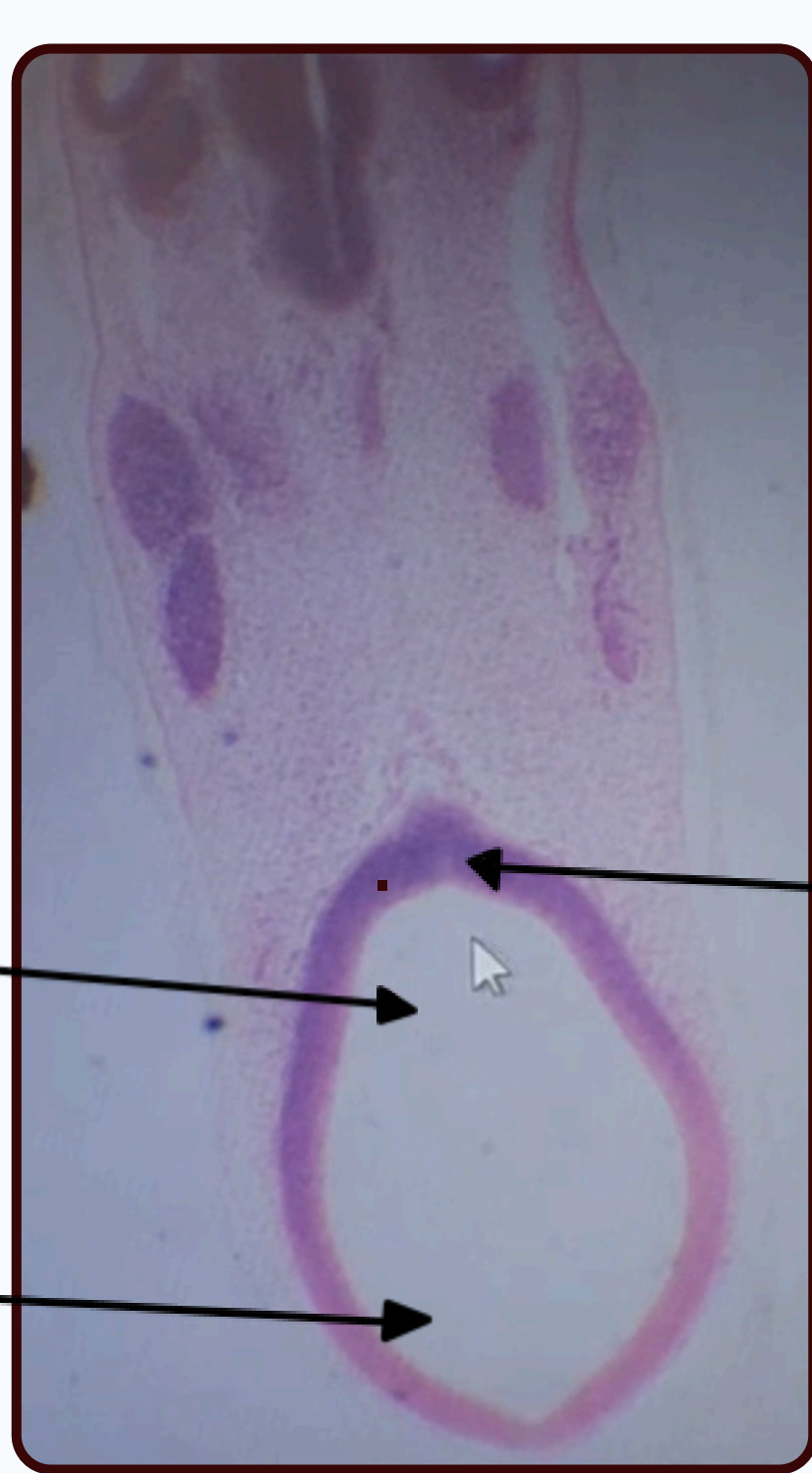10th cranial nerve ganglion

9th cranial nerve ganglion

Trigeminal ganglion



DEVELOPMENT OF THE CVS & DIGESTIVE SYSTEM



Diencephalon

Telencephalon

Infundibulum

Neural tube

sclerotomes
Loose C.T

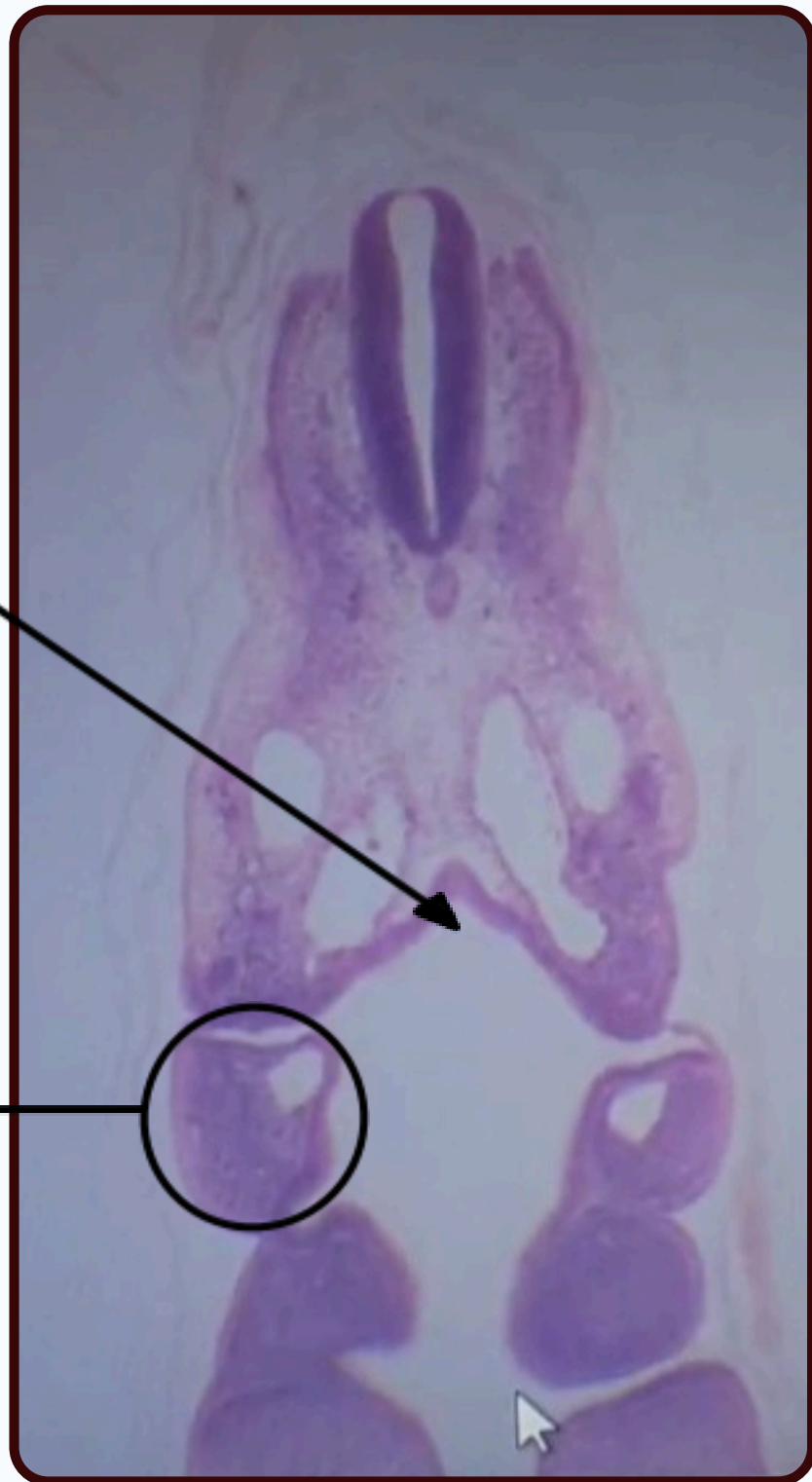Notocord

Dermomyotome
Dense C.T.

Cardinal veins

Bilateral dorsal Aorta

DEVELOPMENT OF THE CVS & DIGESTIVE SYSTEM



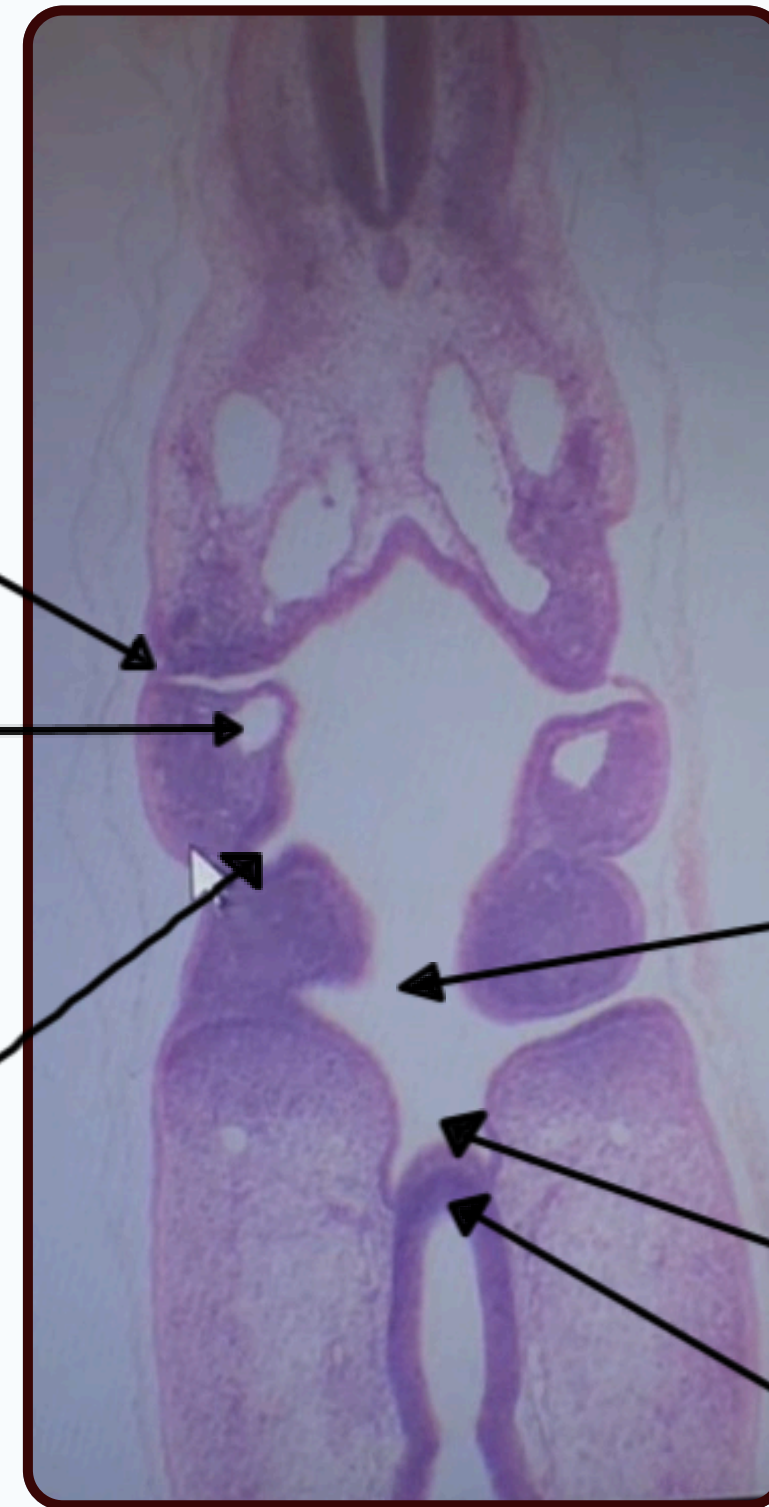
Pharynx
Beginning of
gut tube

**Pharyngeal
arch with
aortic arch**

Pharyngeal cleft

Aortic arch

Pharyngeal Pouch
Surrounded each core of
the pharyngeal arch and
it's Endodermal layer



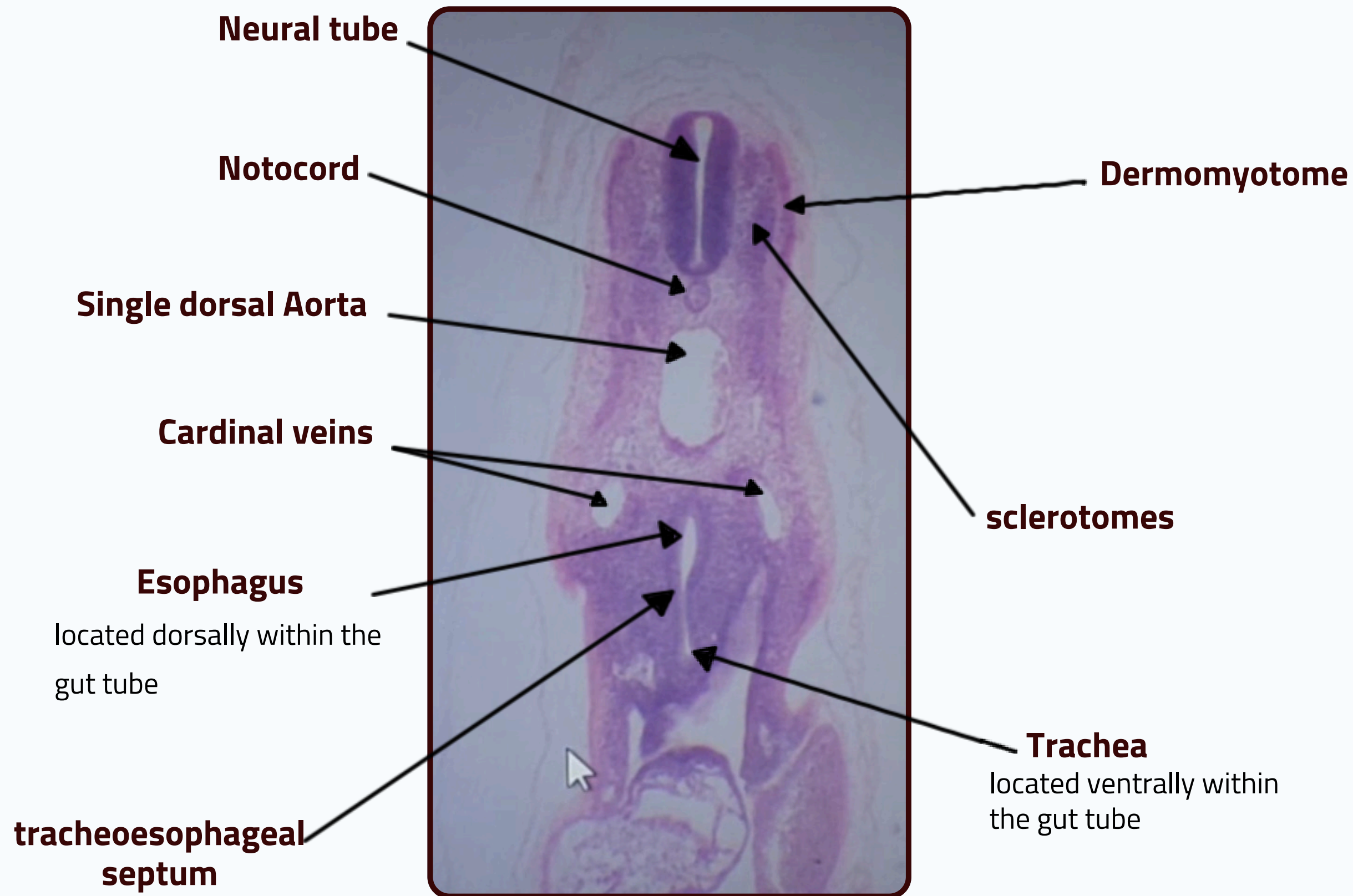
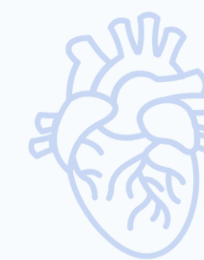Stomodeal Oral cavity

Rathke's pouch

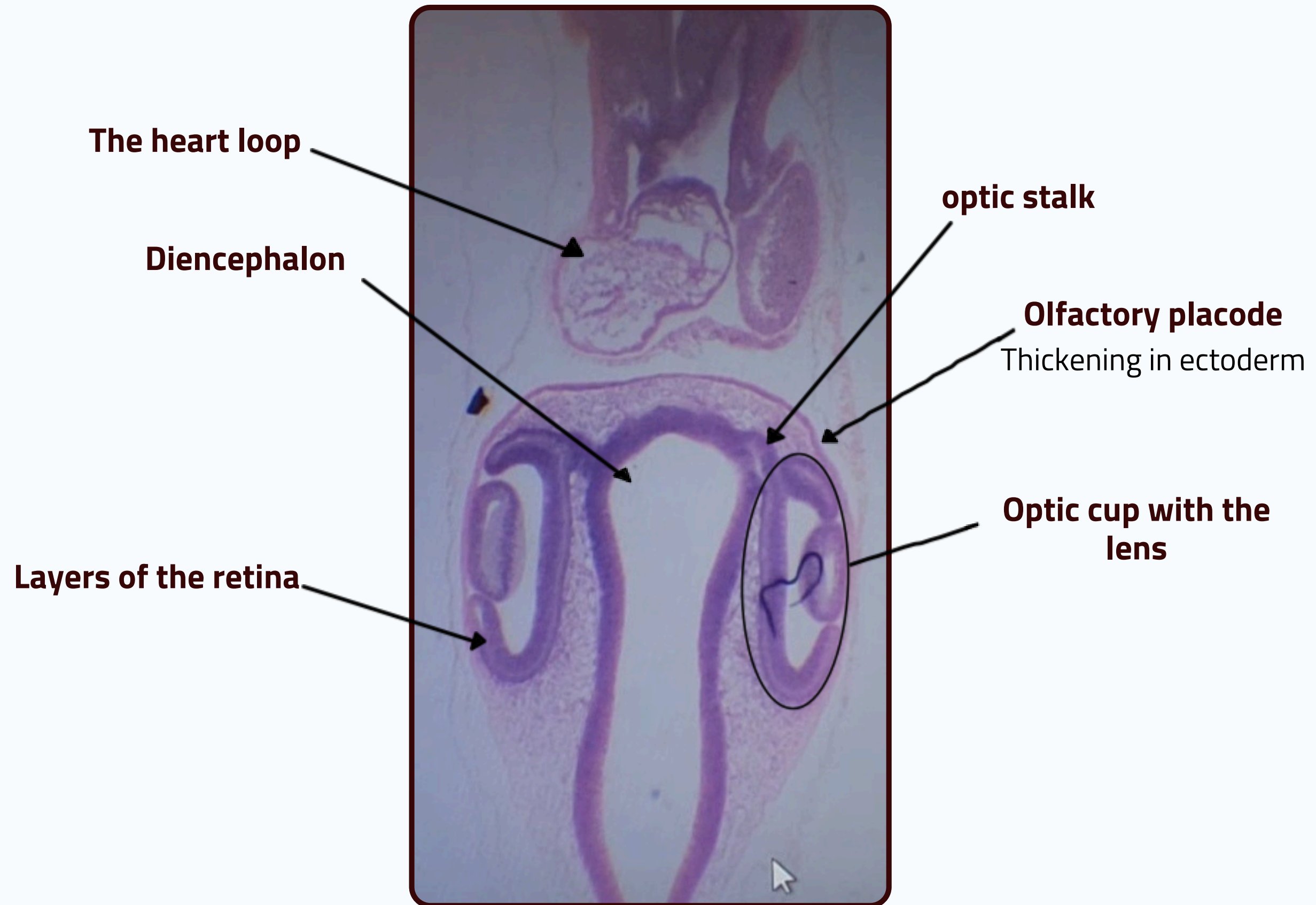
Infundibulum

*Rathke's pouch with the Infundibulum forming
the pituitary gland

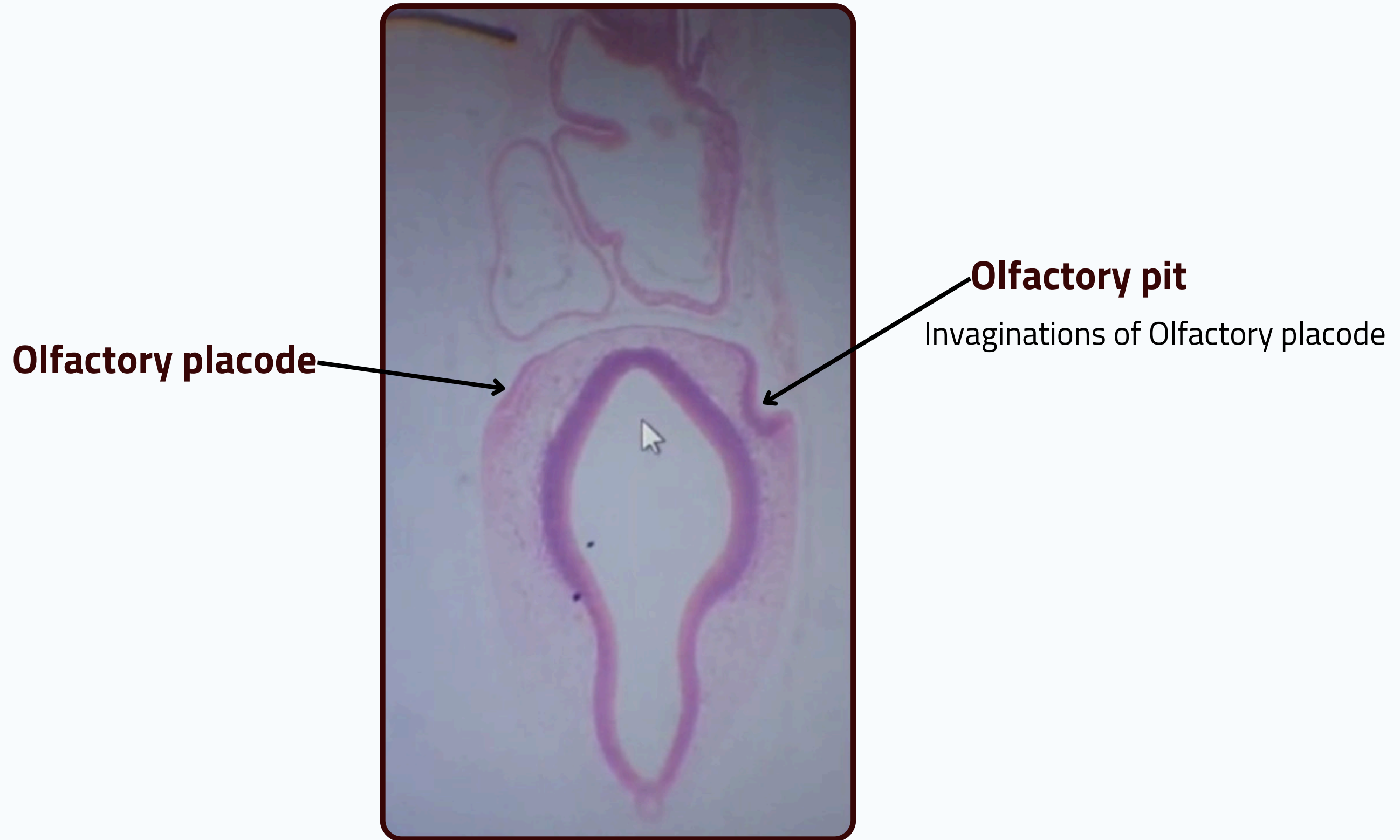
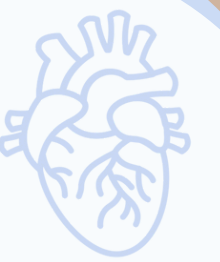DEVELOPMENT OF THE CVS & DIGESTIVE SYSTEM



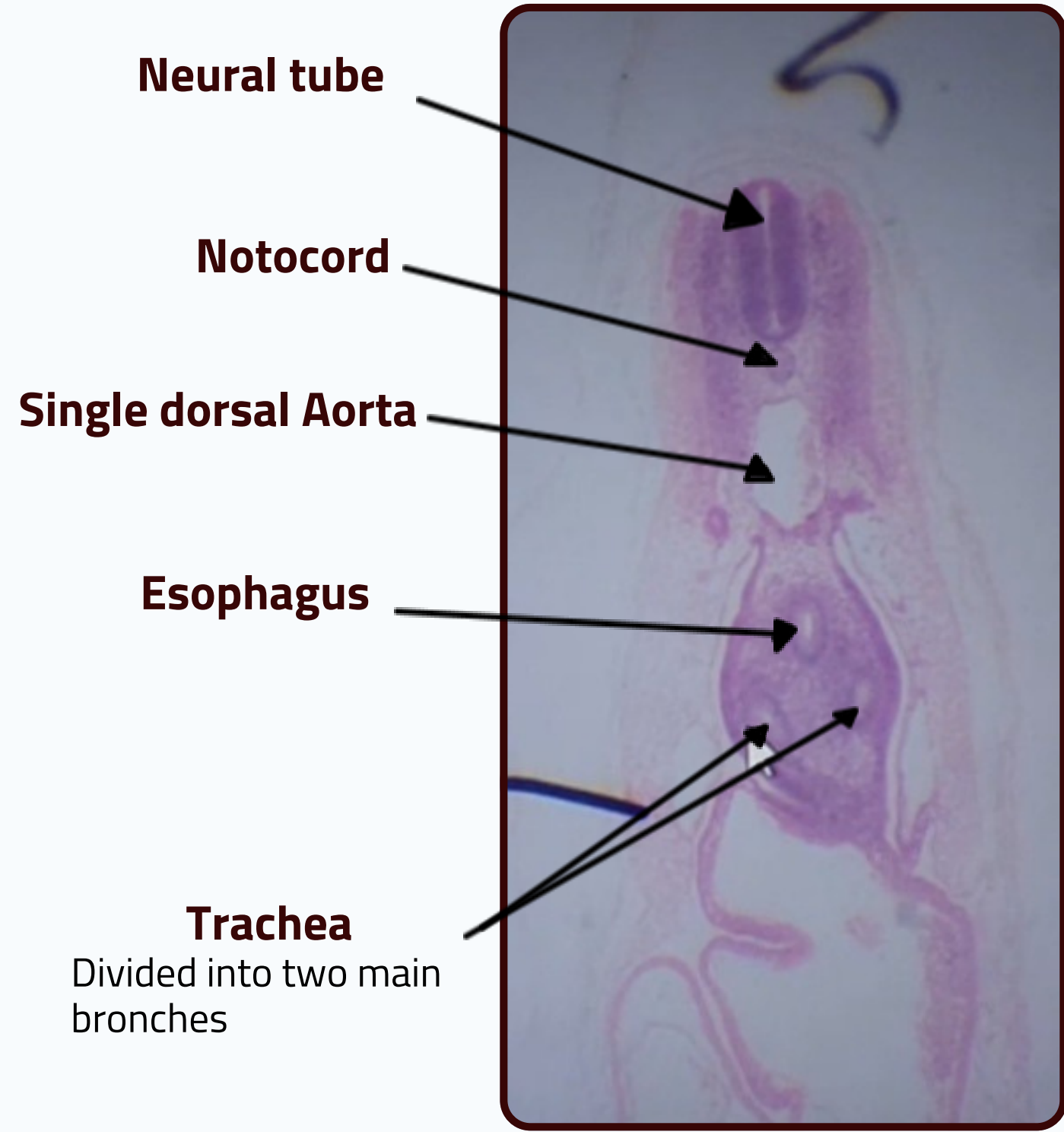
DEVELOPMENT OF THE CVS & DIGESTIVE SYSTEM



DEVELOPMENT OF THE CVS & DIGESTIVE SYSTEM



DEVELOPMENT OF THE CVS & DIGESTIVE SYSTEM



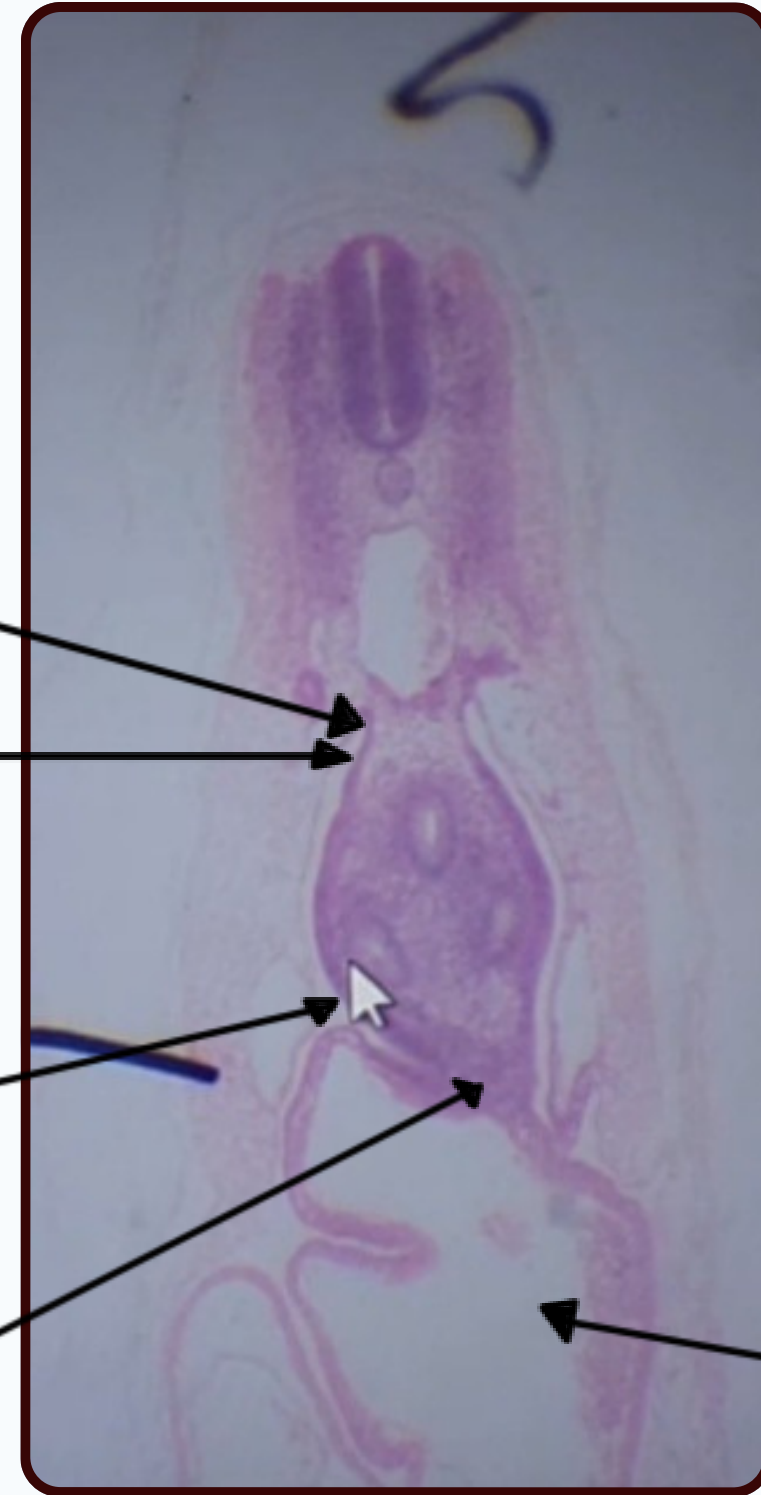
The dorsal mesentery
suspended from the dorsal (posterior) abdominal wall.

Peritoneal cavity

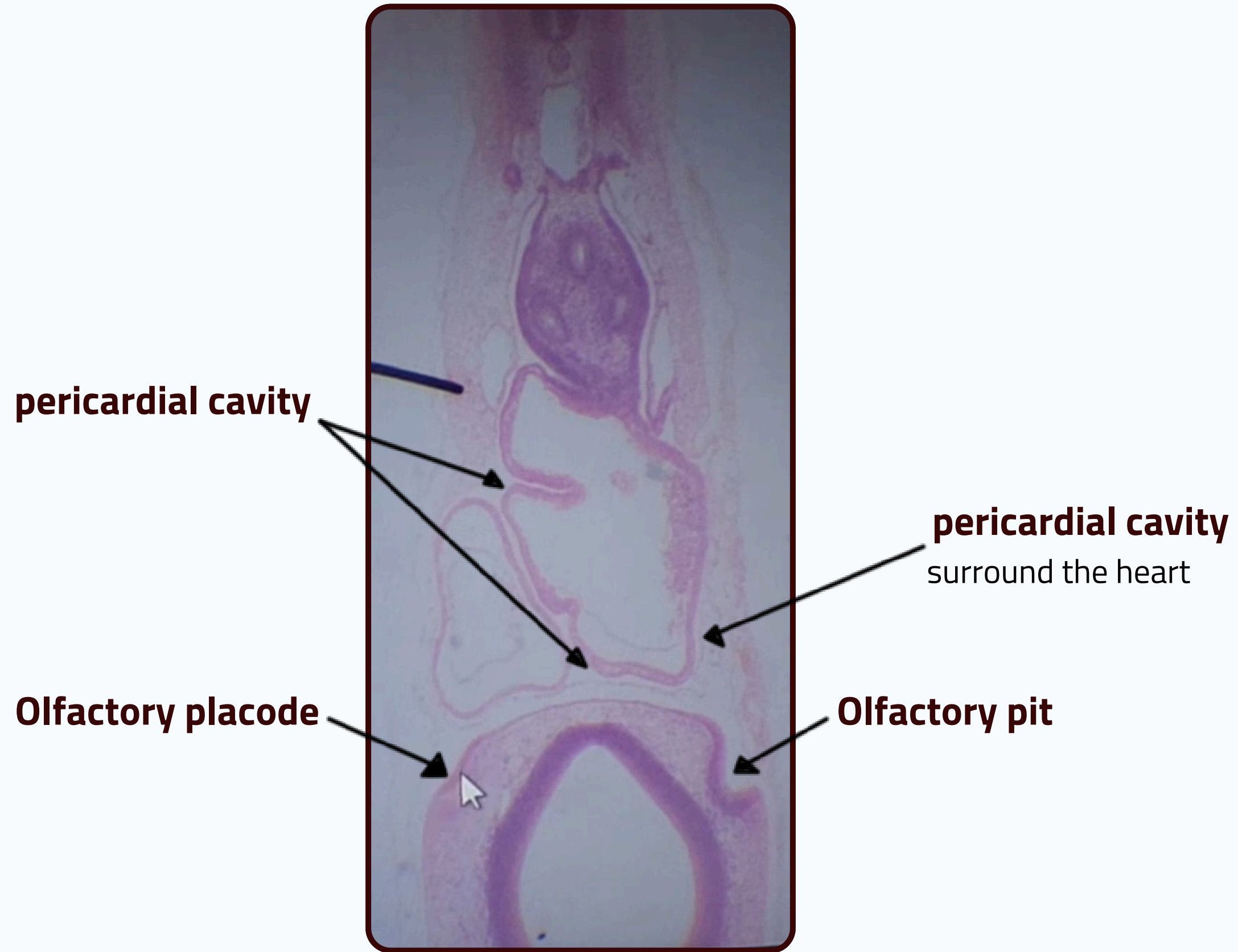
Pleural cavity

Ventral mesentery

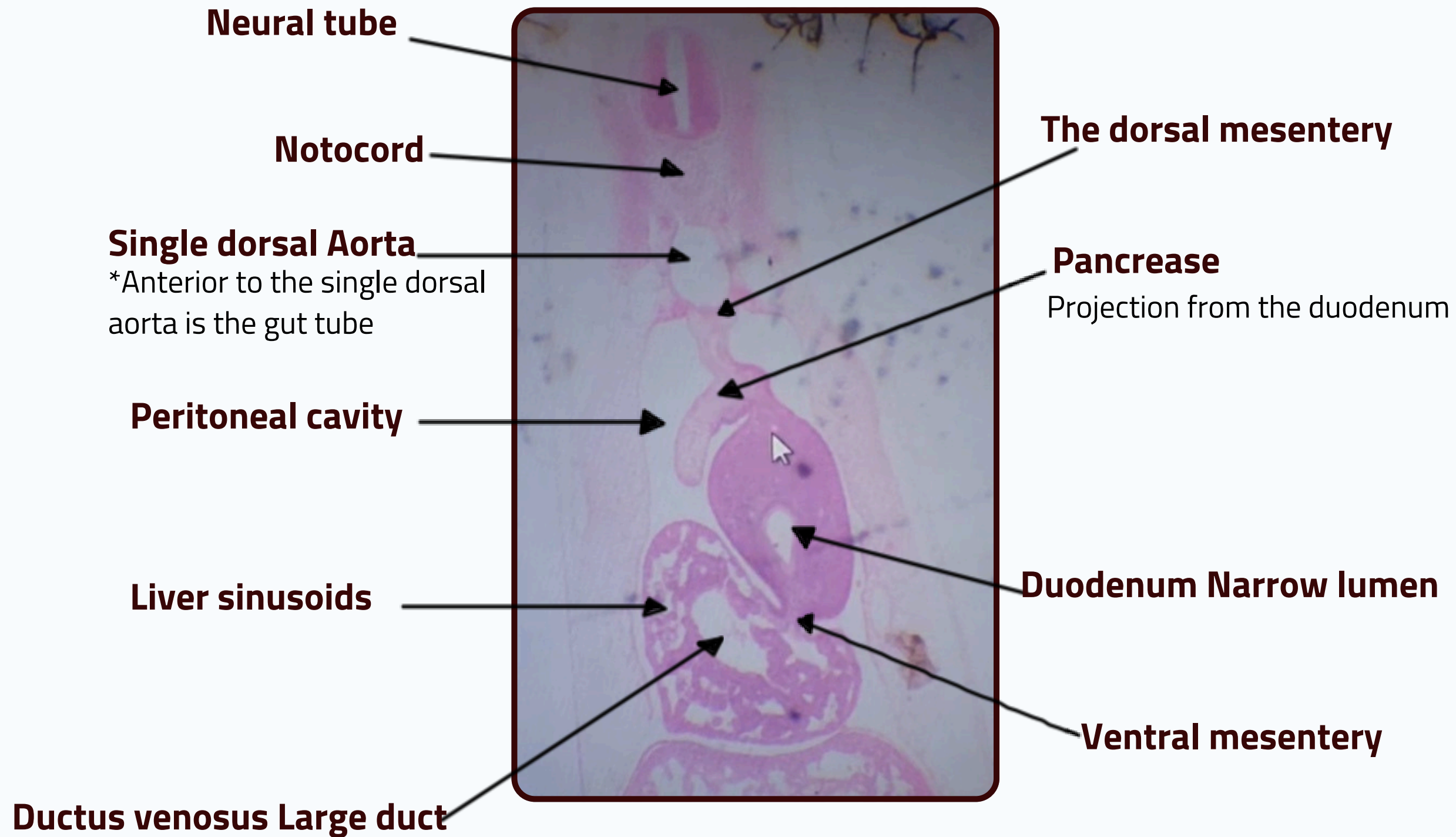
Heart loop



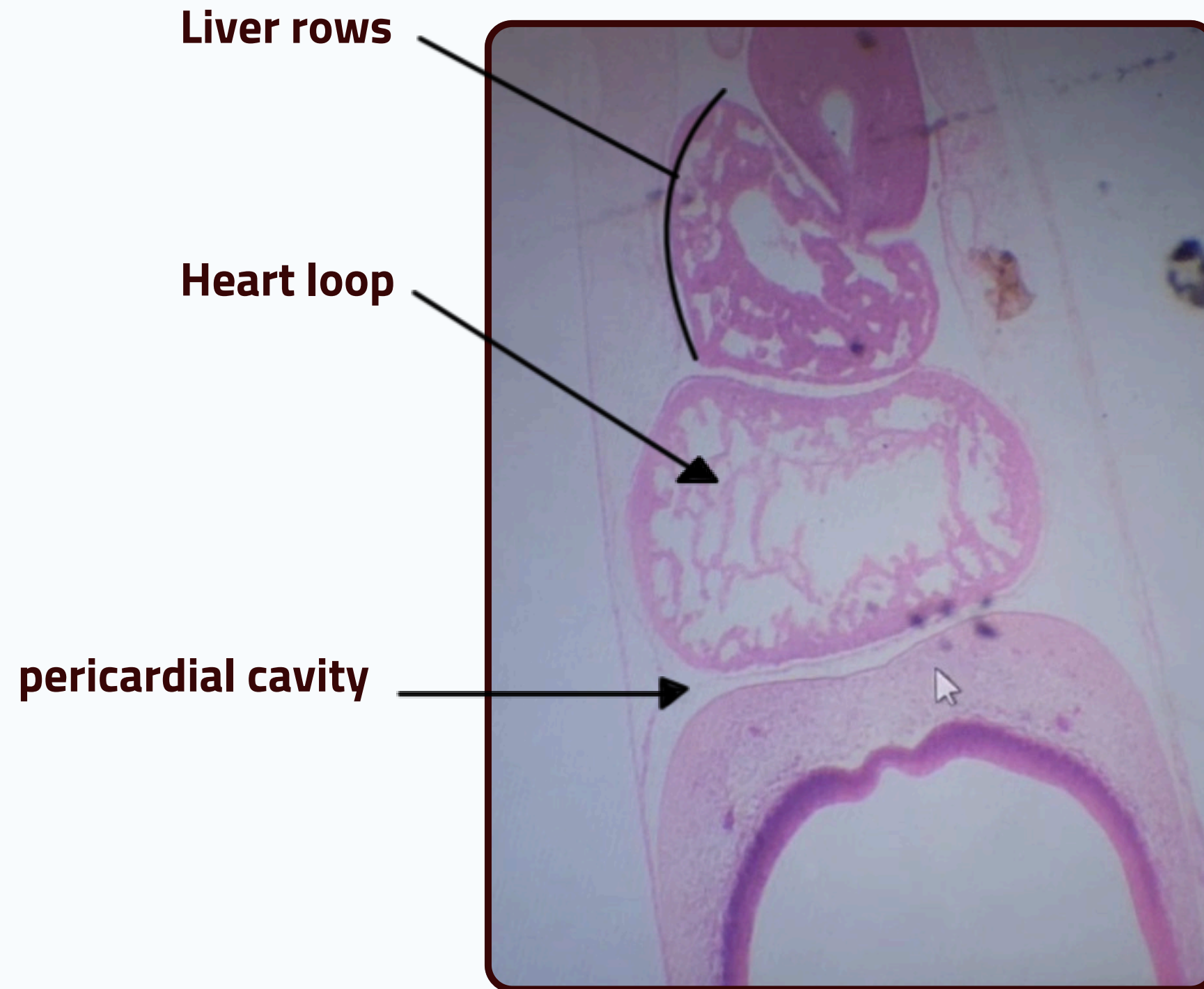
DEVELOPMENT OF THE CVS & DIGESTIVE SYSTEM



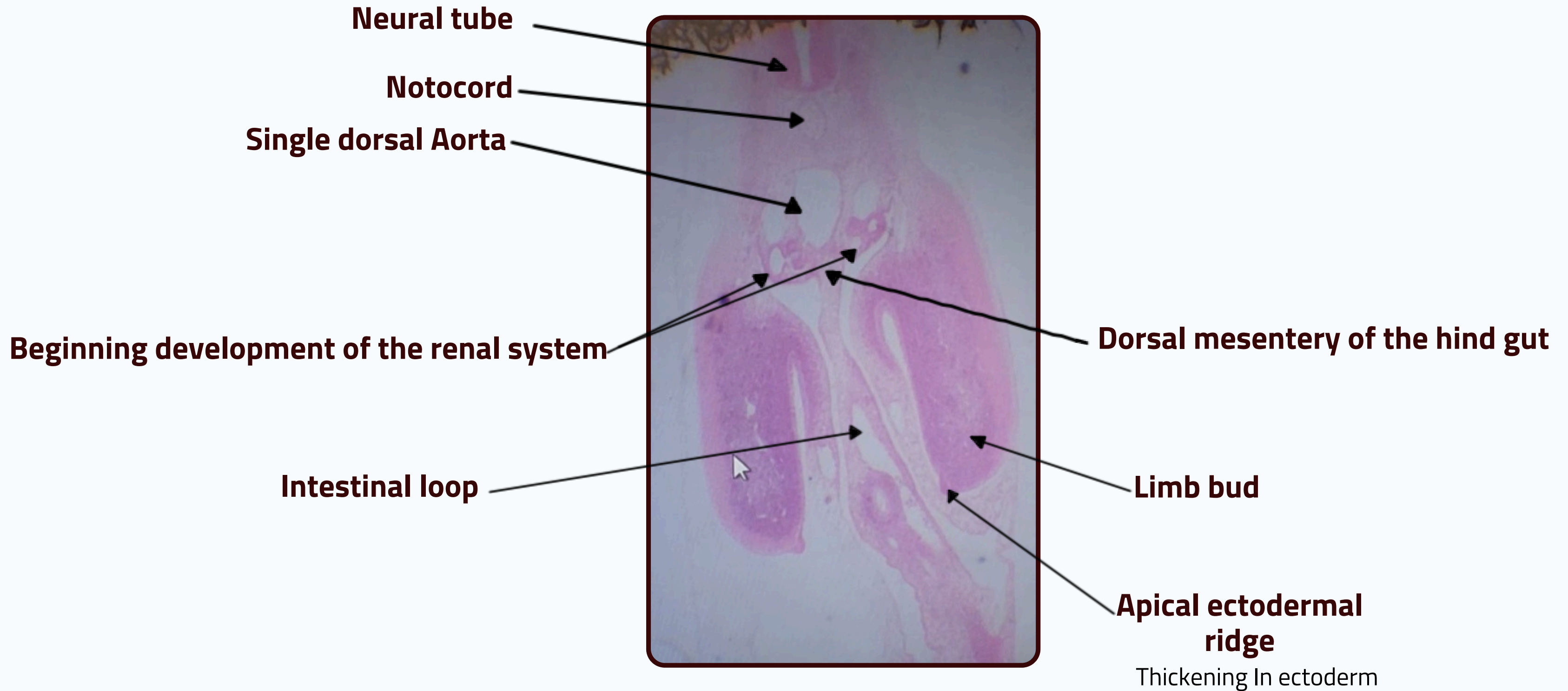
DEVELOPMENT OF THE CVS & DIGESTIVE SYSTEM



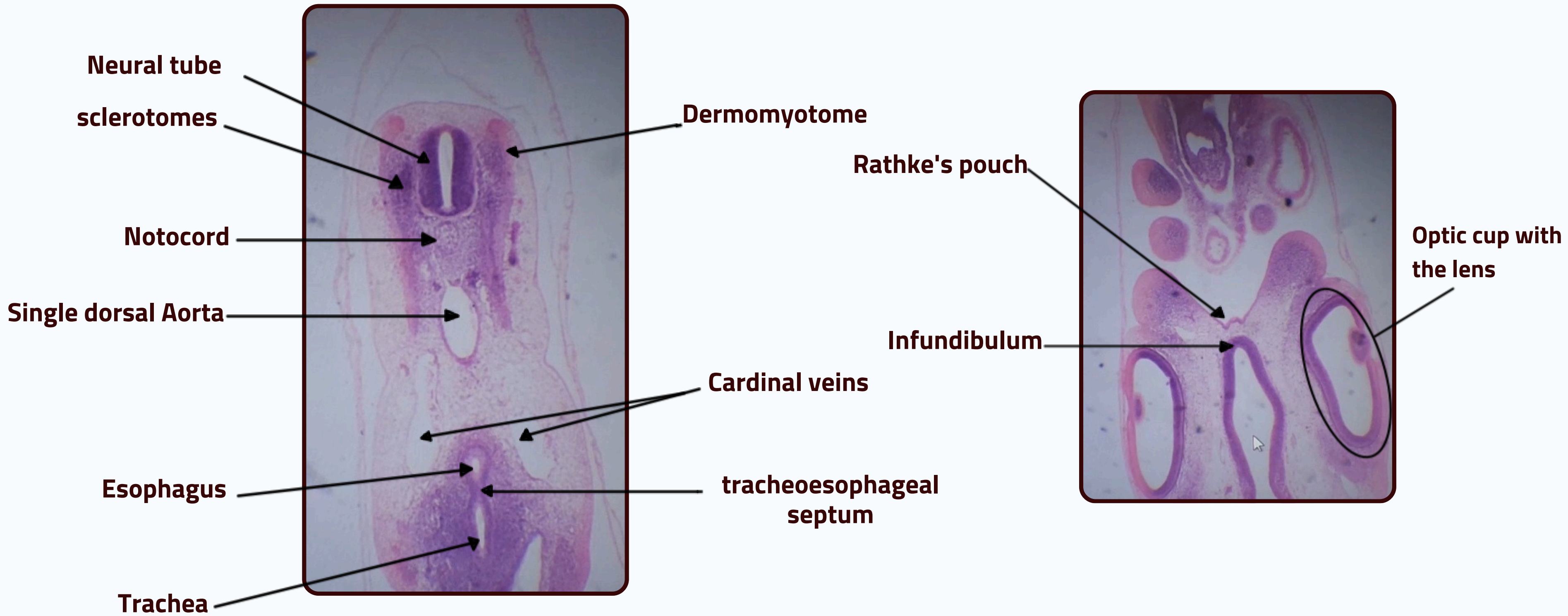
DEVELOPMENT OF THE CVS & DIGESTIVE SYSTEM



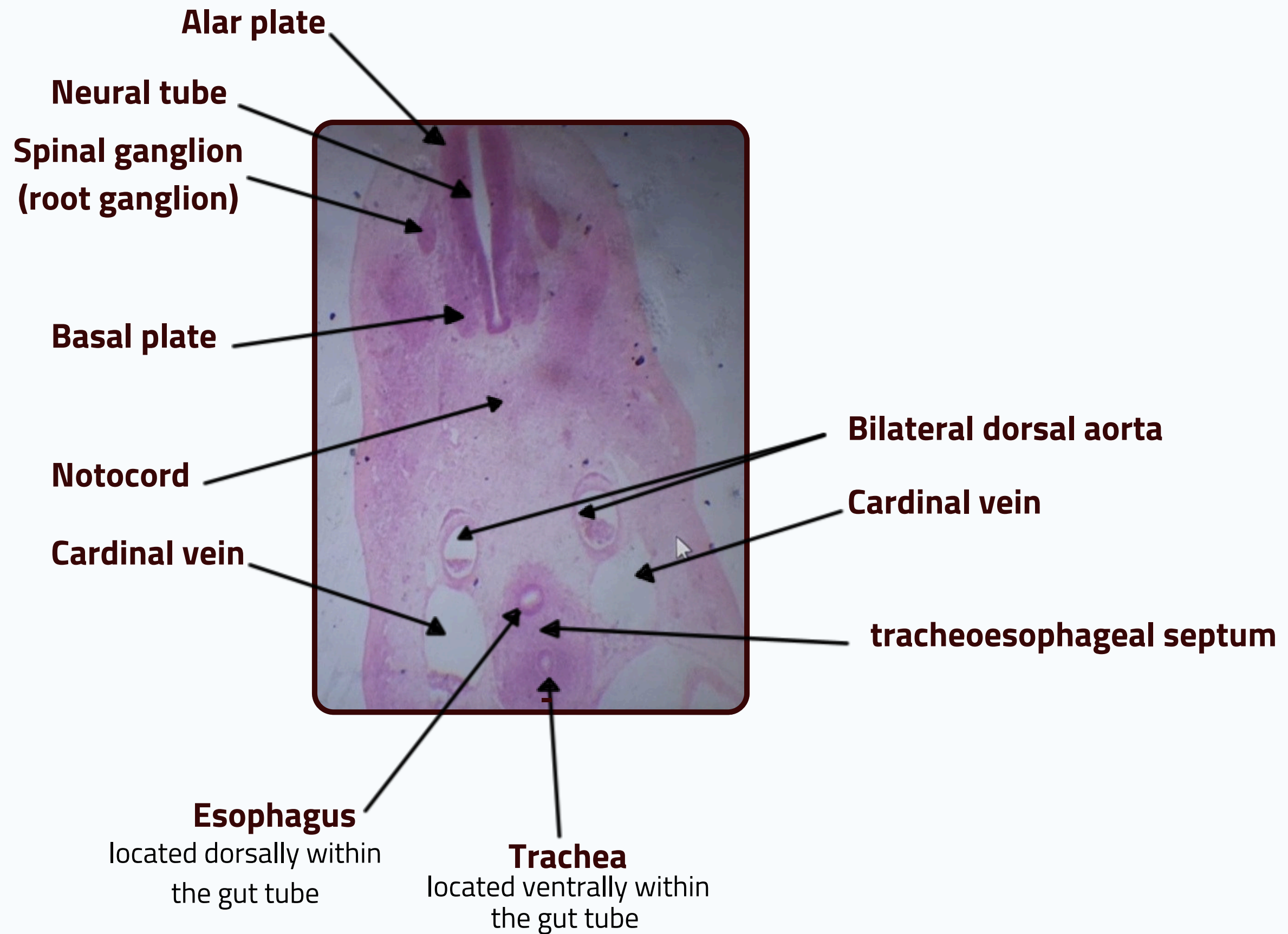
DEVELOPMENT OF THE CVS & DIGESTIVE SYSTEM



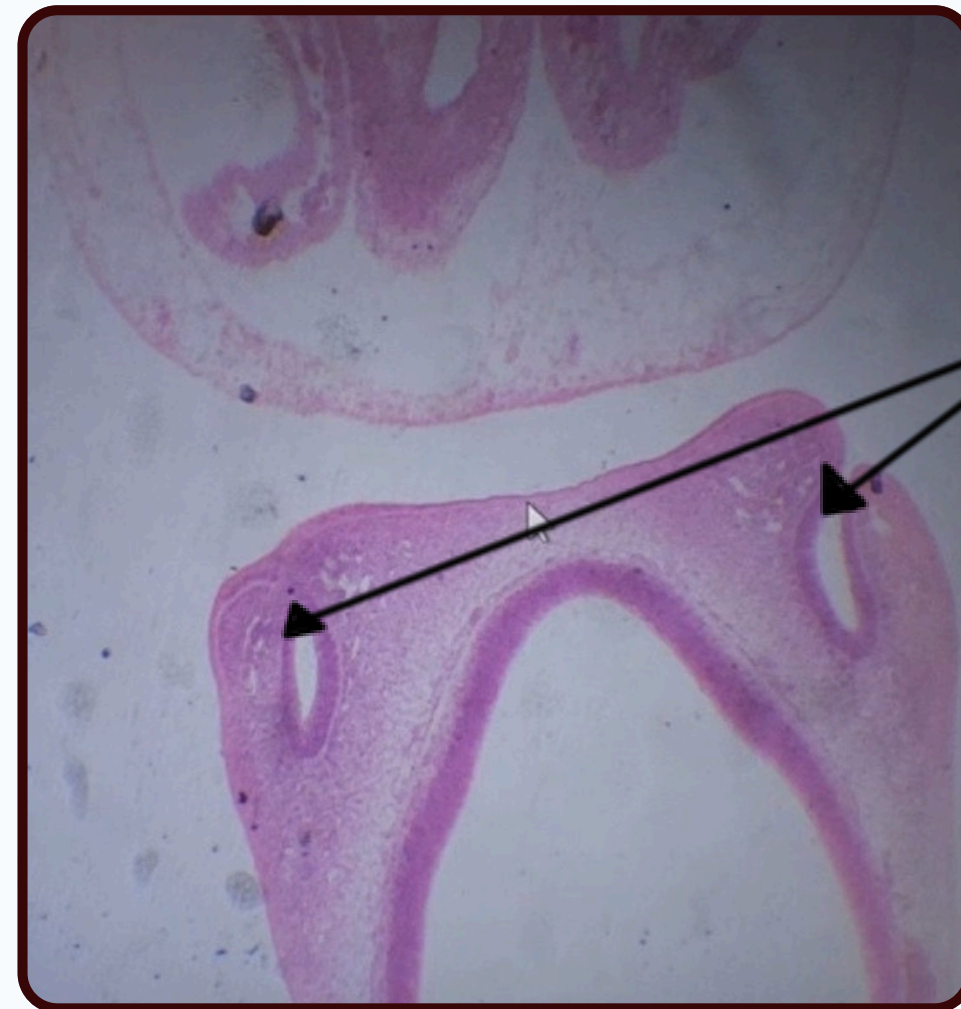
DEVELOPMENT OF THE CVS & DIGESTIVE SYSTEM



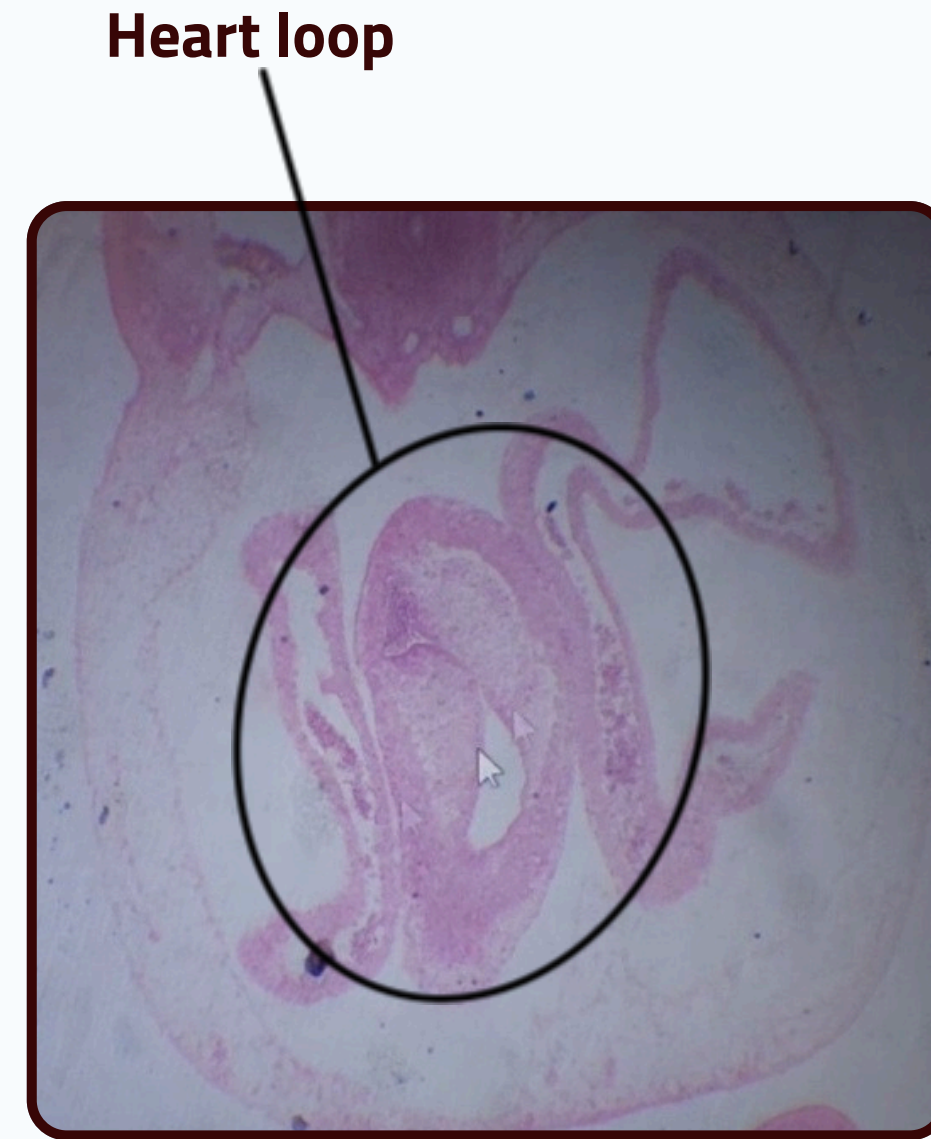
DEVELOPMENT OF THE CVS & DIGESTIVE SYSTEM



DEVELOPMENT OF THE CVS & DIGESTIVE SYSTEM

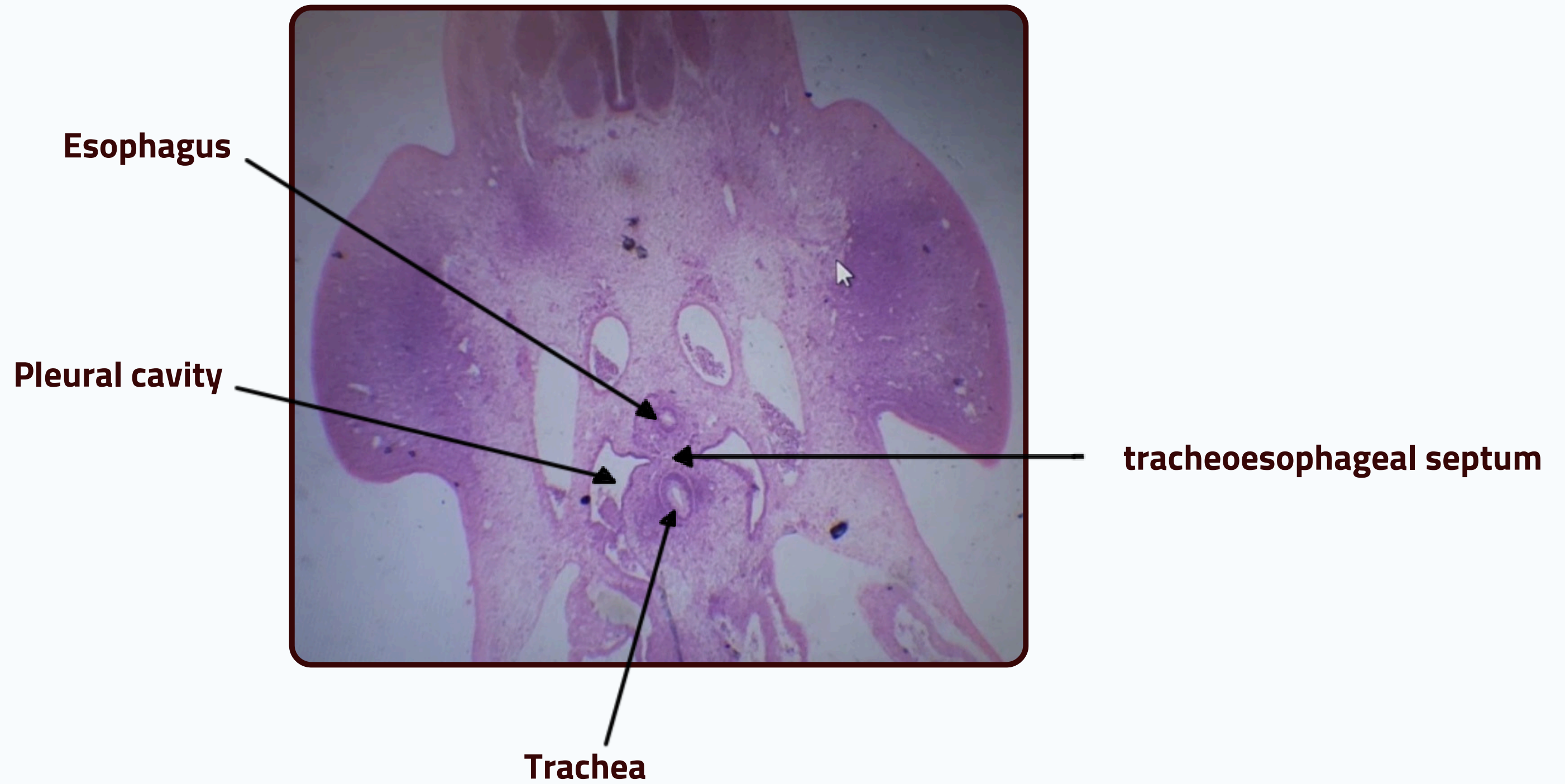


Olfactory pit

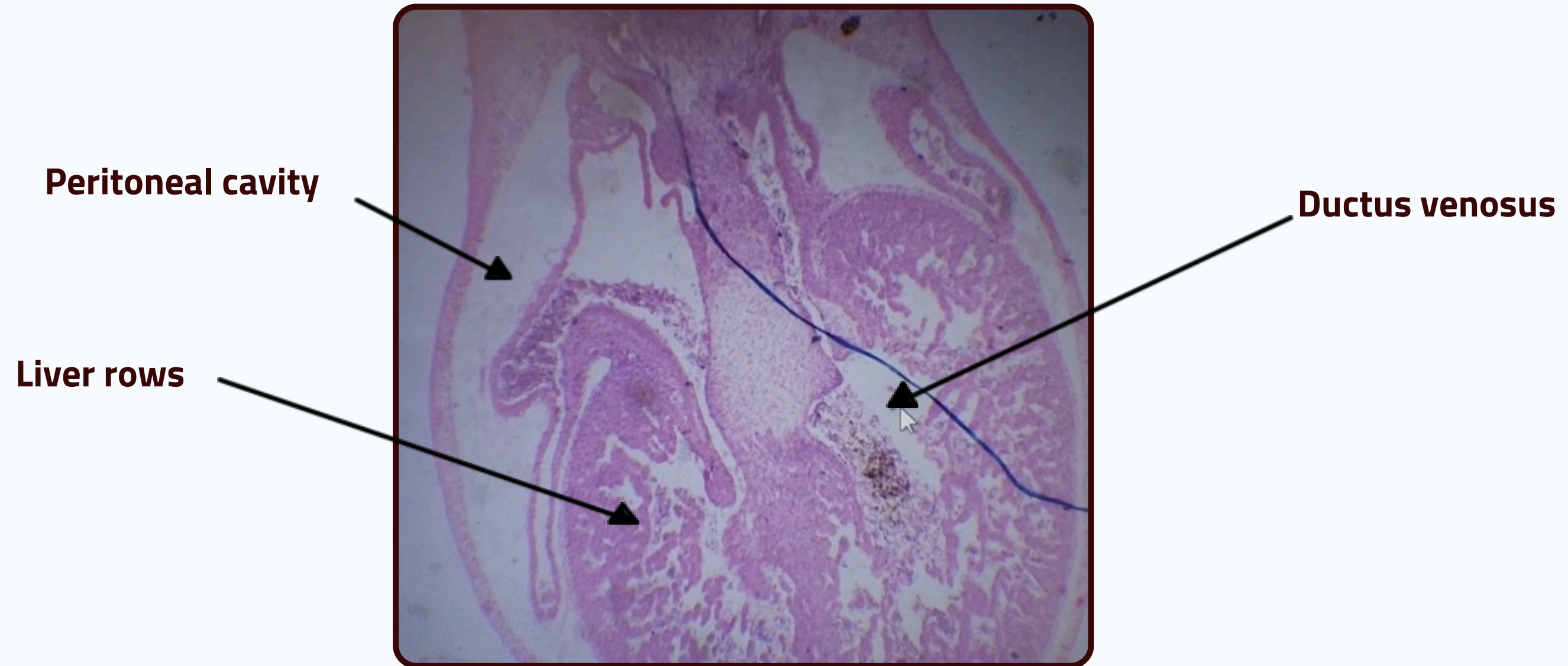


Heart loop

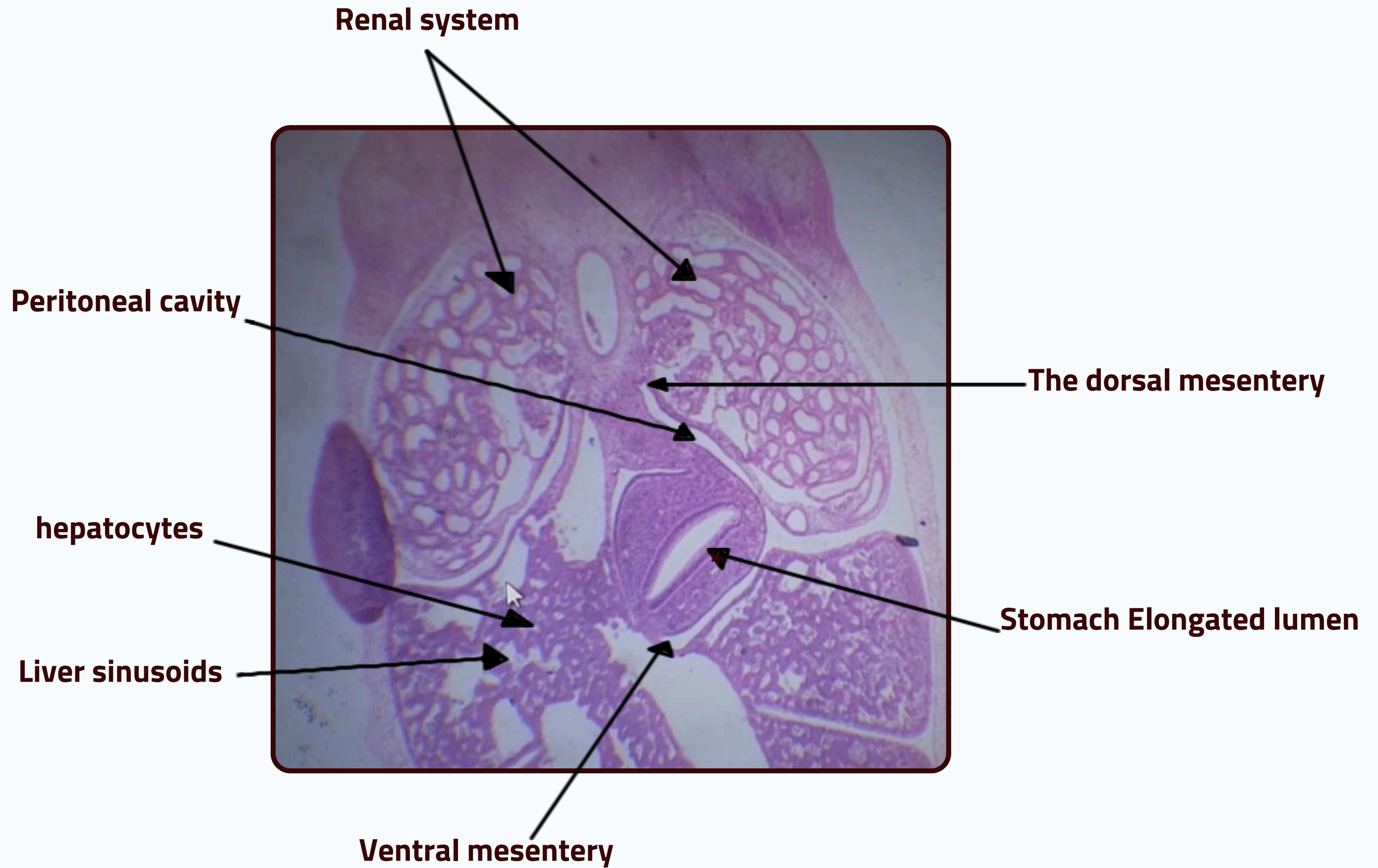
DEVELOPMENT OF THE CVS & DIGESTIVE SYSTEM



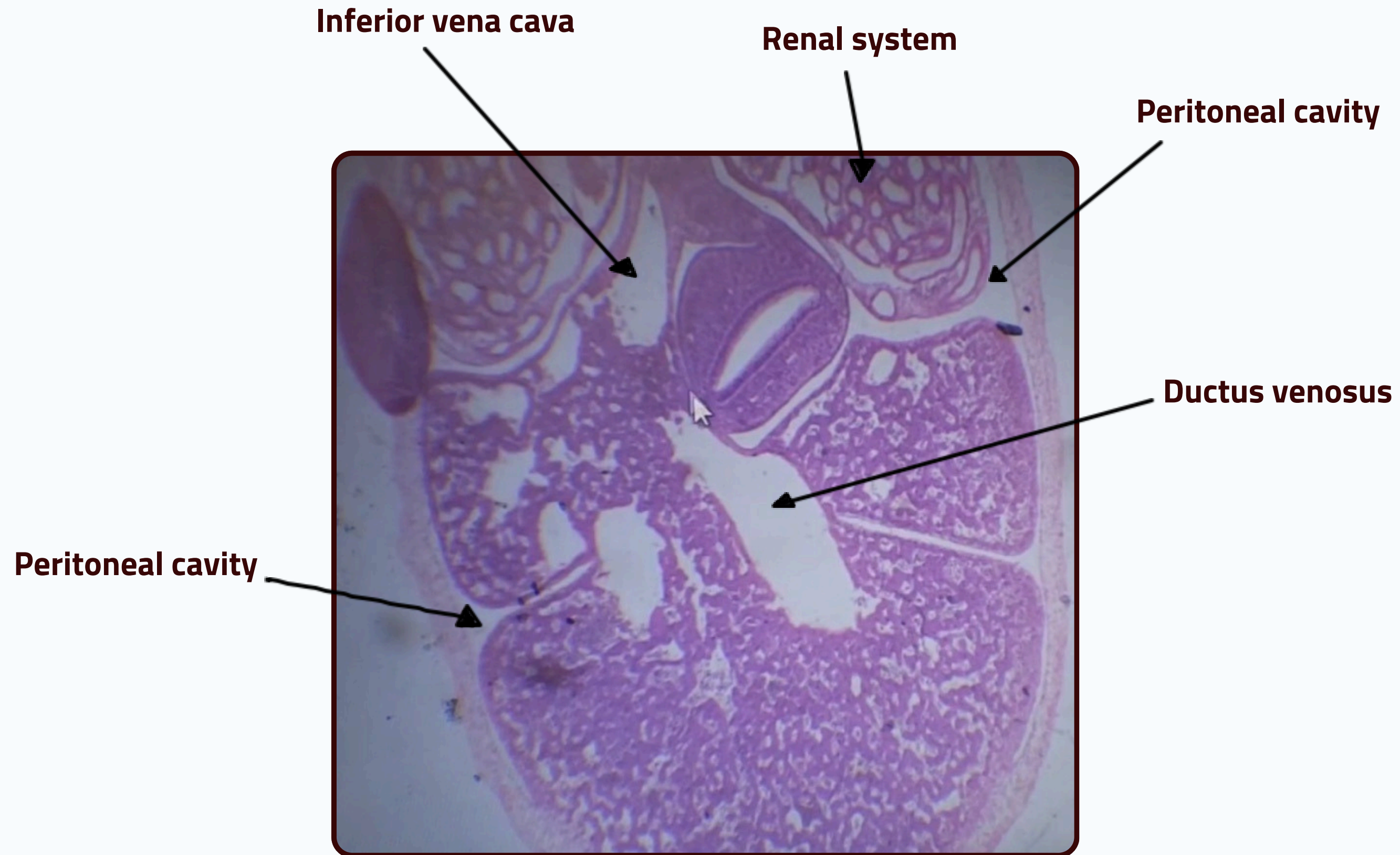
DEVELOPMENT OF THE CVS & DIGESTIVE SYSTEM



DEVELOPMENT OF THE CVS & DIGESTIVE SYSTEM



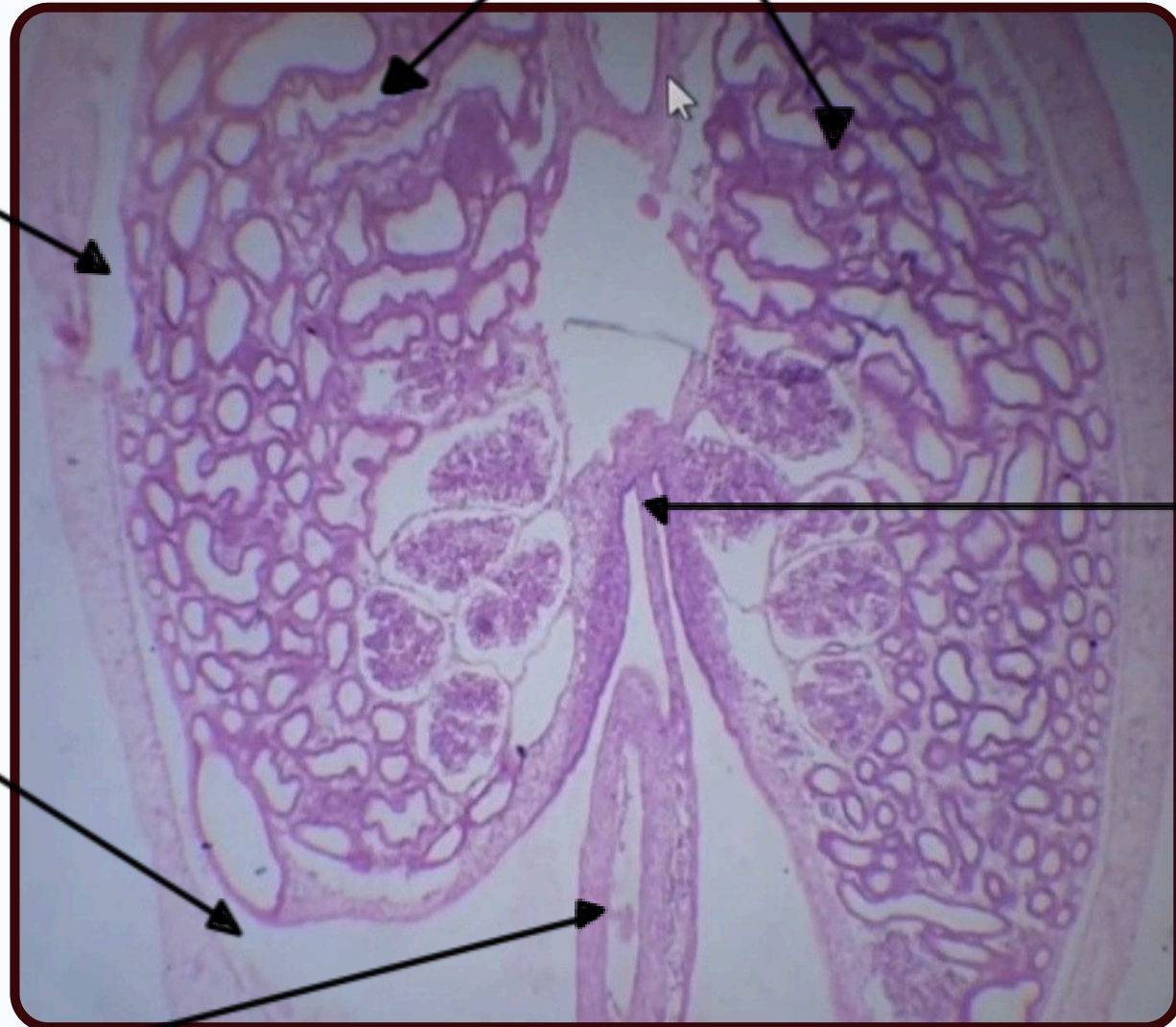
DEVELOPMENT OF THE CVS & DIGESTIVE SYSTEM



DEVELOPMENT OF THE CVS & DIGESTIVE SYSTEM



Renal system



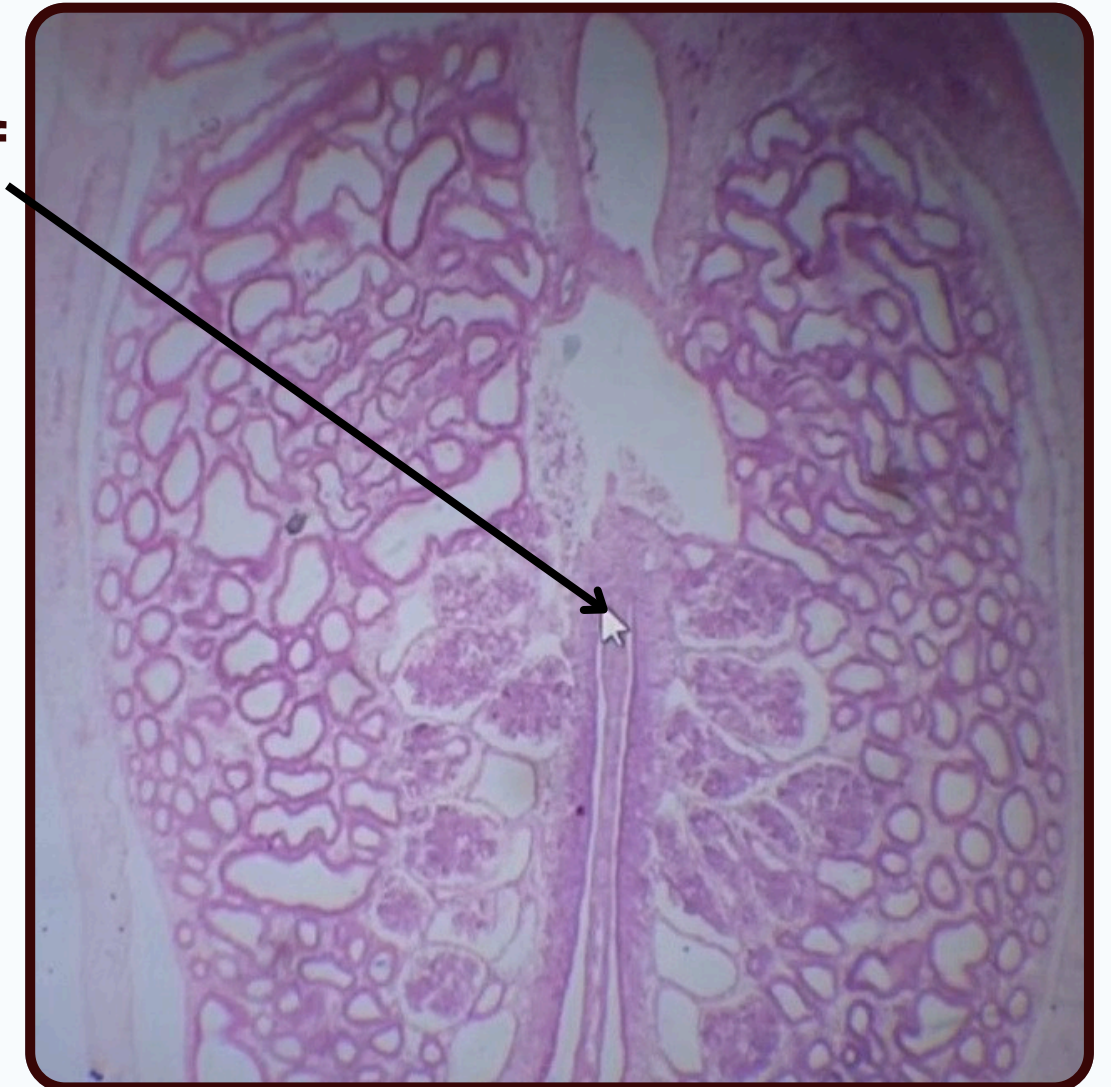
Peritoneal cavity

Peritoneal cavity

Intestine

Dorsal mesentery of the hind gut

Dorsal mesentery of the hind gut

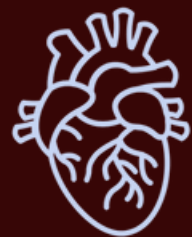

THANK YOU

EDITED BY



SATURN
MEDIC



ARECH

© ALL COPYRIGHT ARE RESERVED FOR
SATURN MEDIC AND ARECH

WWW.SATURNMEDIC.COM