

ANATOMY OF UPPER LIMB

PRACTICAL LECTURE - 6 -

MUSCLES / PART 1

ANTERIOR THORACO-APPENDICULAR MUSCLES

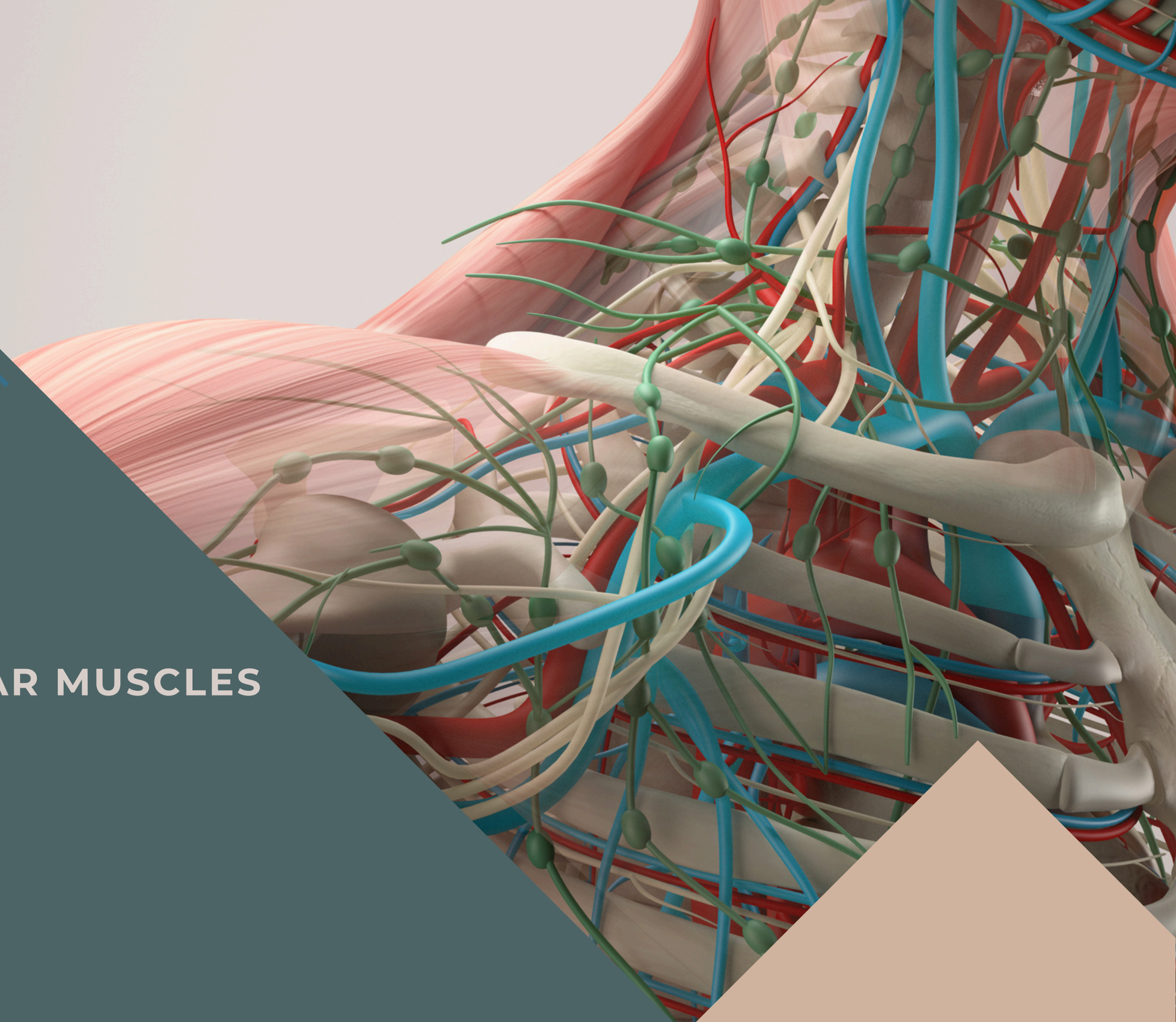
EDITED BY



SATURN
MEDIC



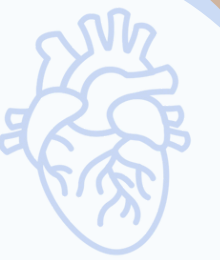ARECH



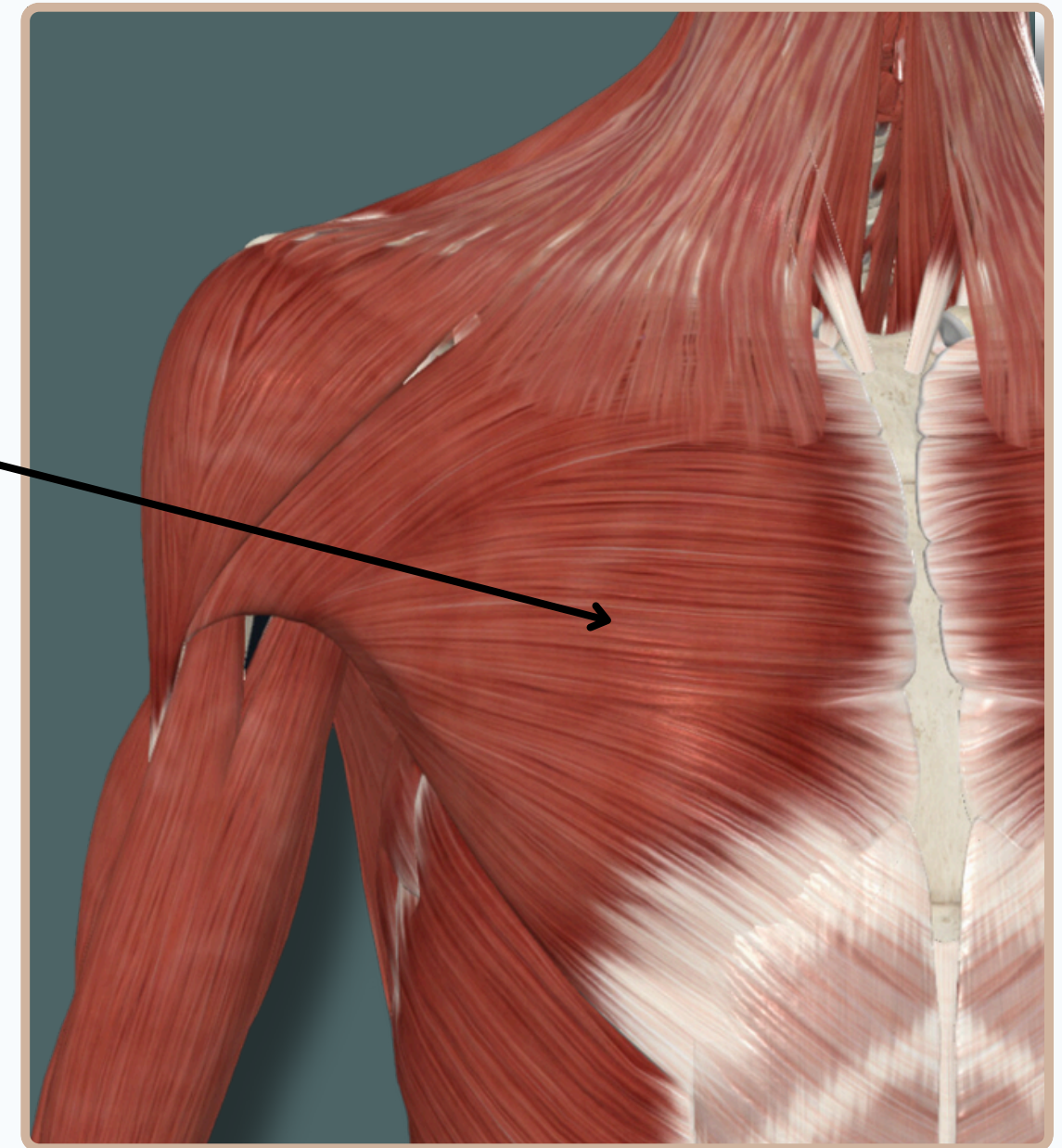
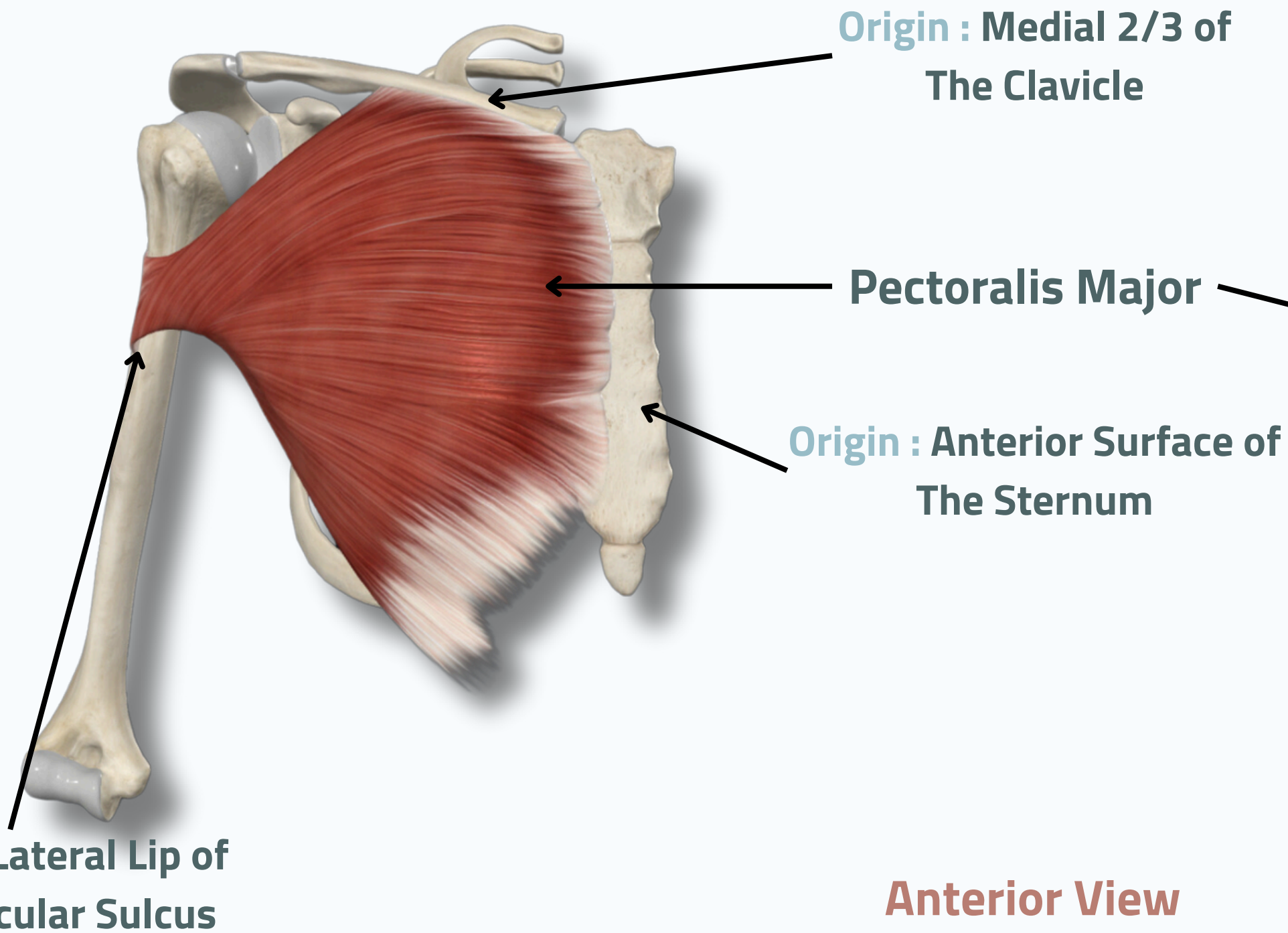
ALL COPYRIGHT ARE RESERVED FOR
SATURN MEDIC AND ARECH

WWW.SATURNMEDIC.COM

ANTERIOR THORACO-APPENDICULAR MUSCLES

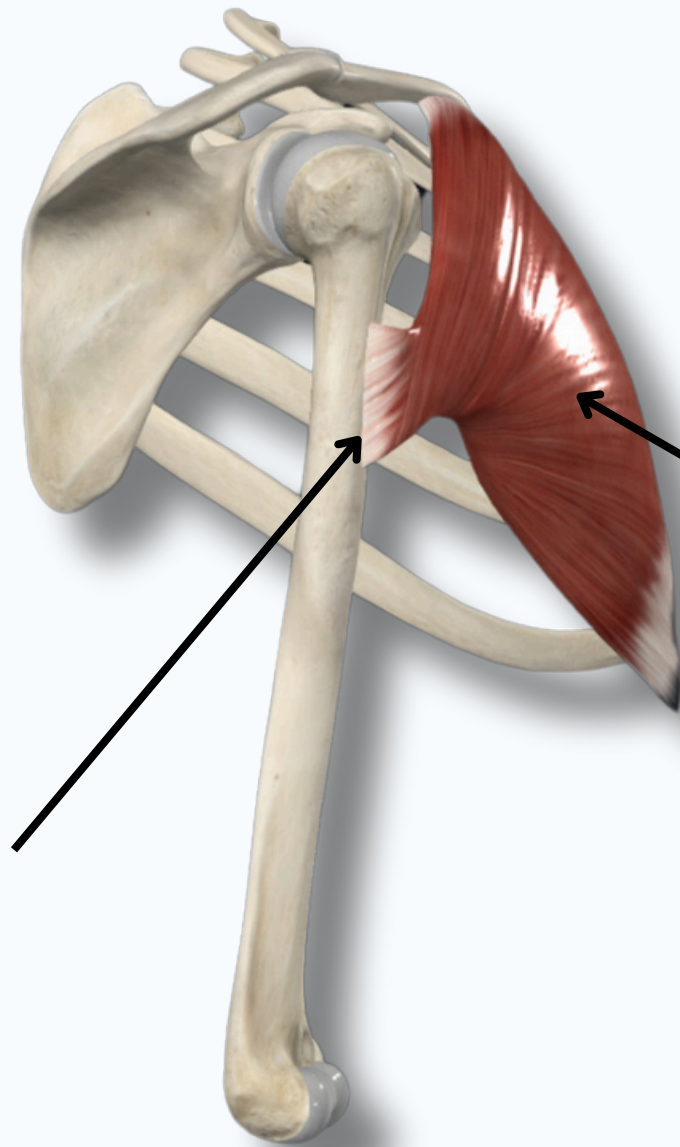
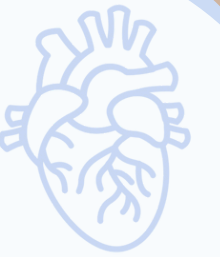

PECTORALIS MAJOR



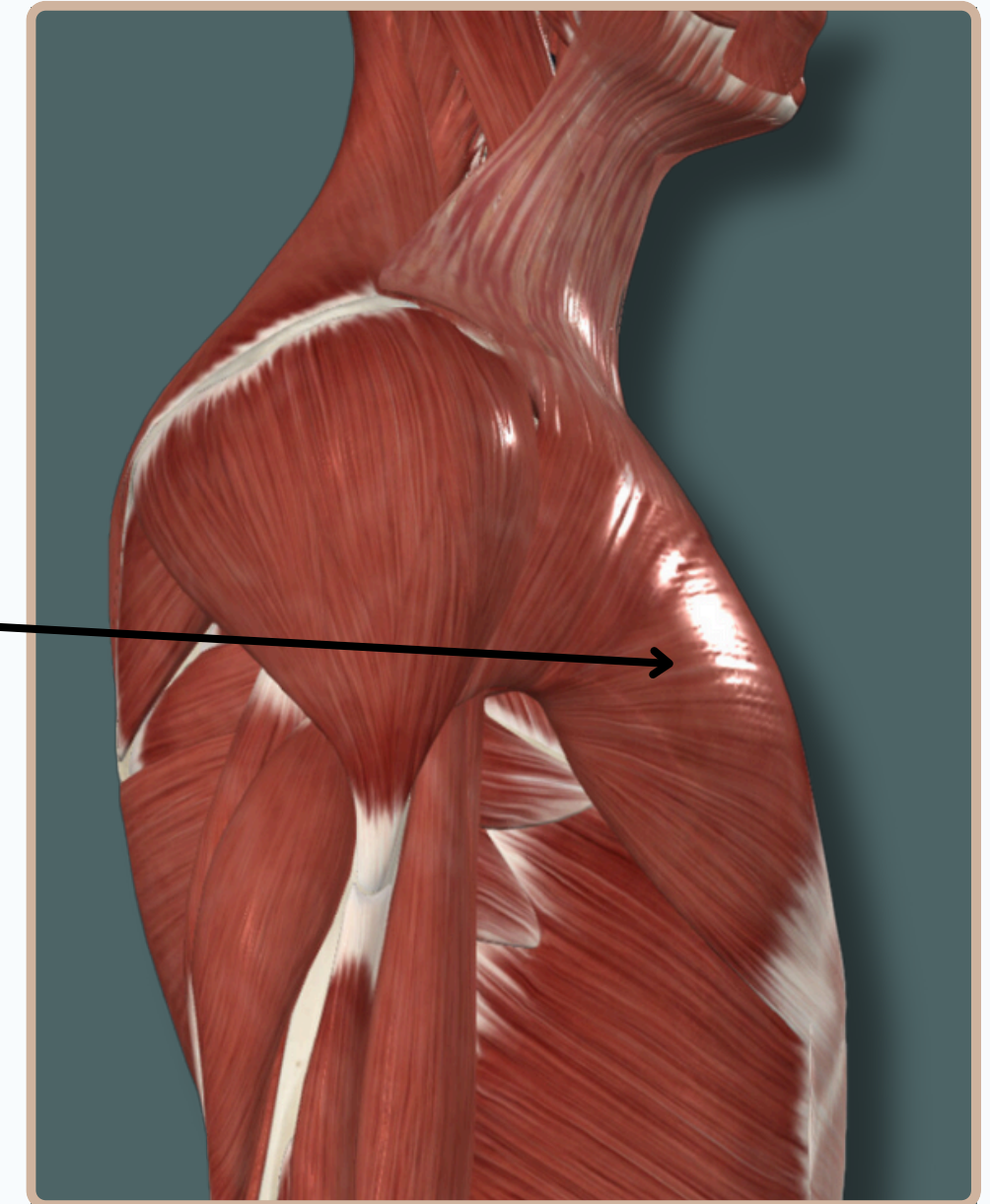
ANTERIOR THORACO-APPENDICULAR MUSCLES

PECTORALIS MAJOR



Insertion : Lateral Lip of Intertubercular Sulcus

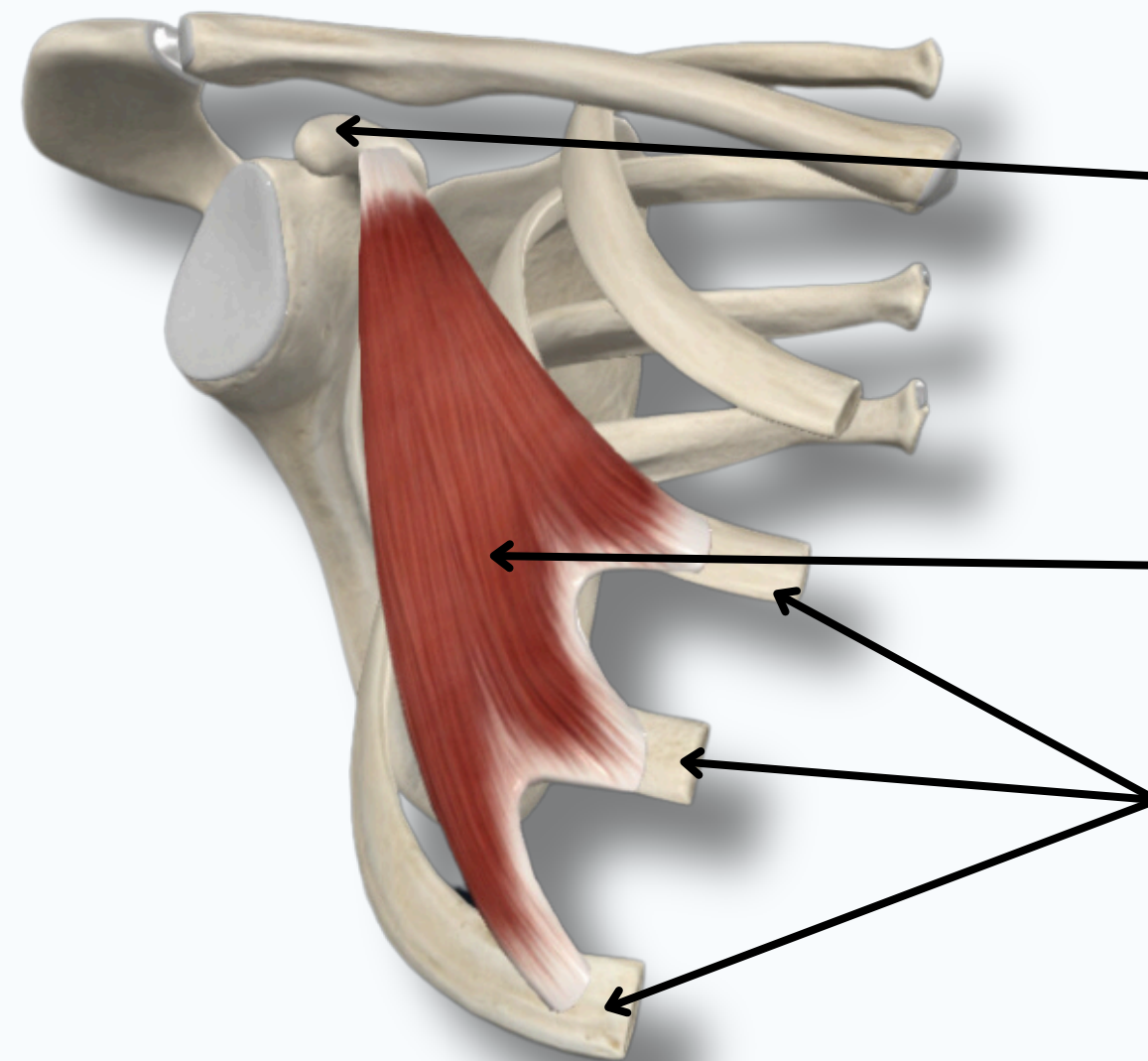
Pectoralis Major



Lateral View

ANTERIOR THORACO-APPENDICULAR MUSCLES

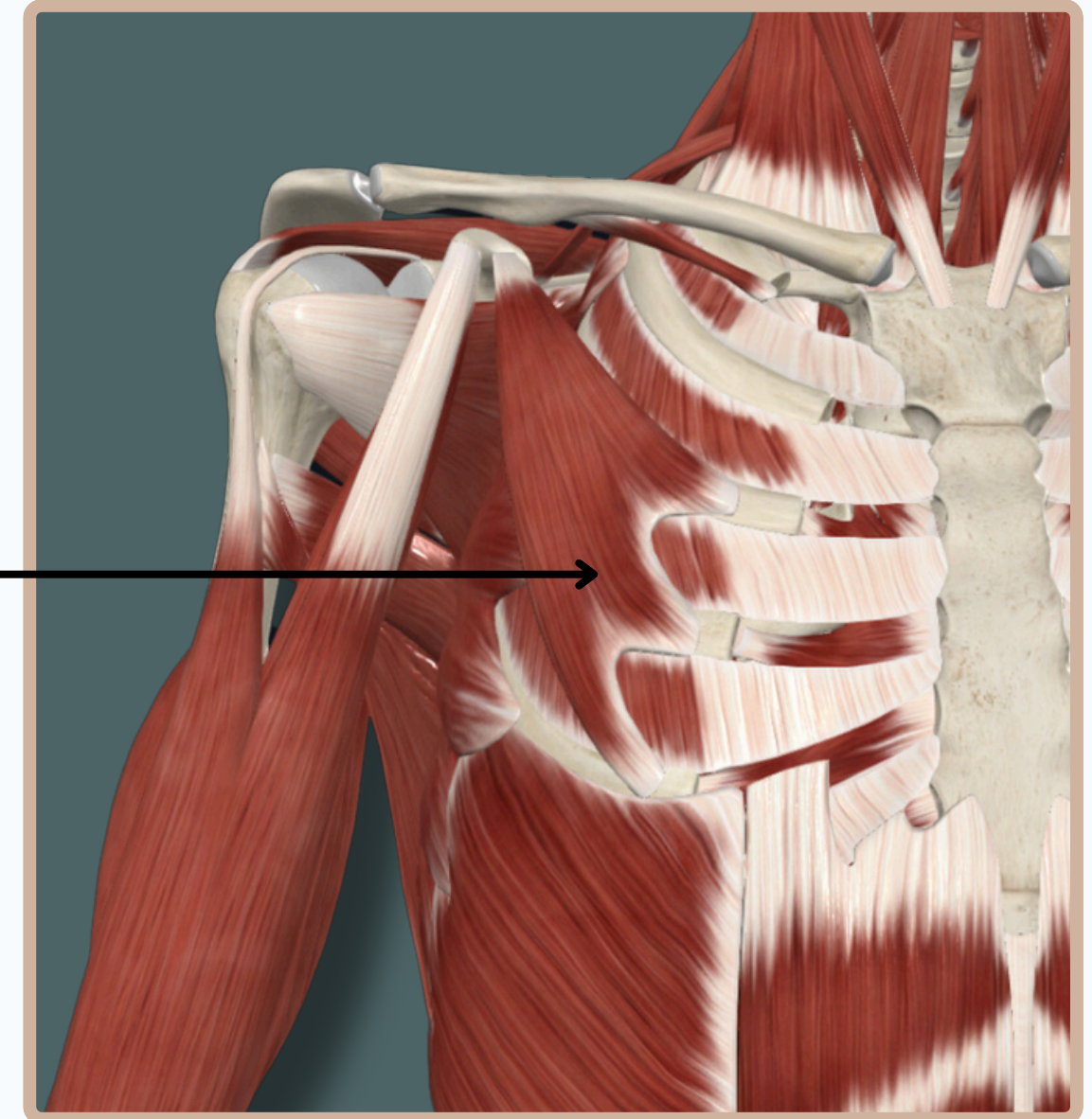
PECTORALIS MINOR



Insertion : Tip of the Coracoid Process

Pectoralis Minor

Origin : Third, Fourth and Fifth ribs



Anterior View

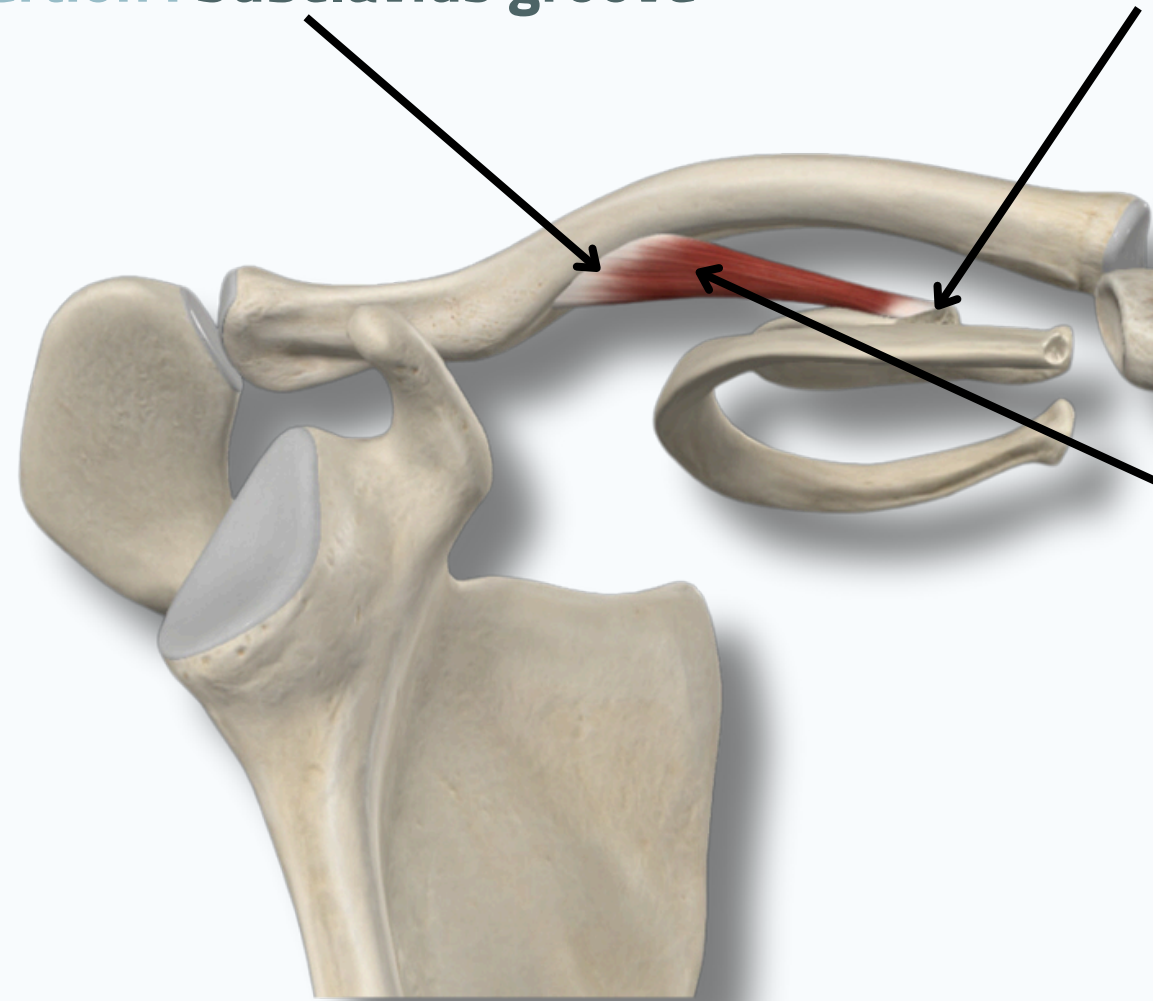
ANTERIOR THORACO-APPENDICULAR MUSCLES



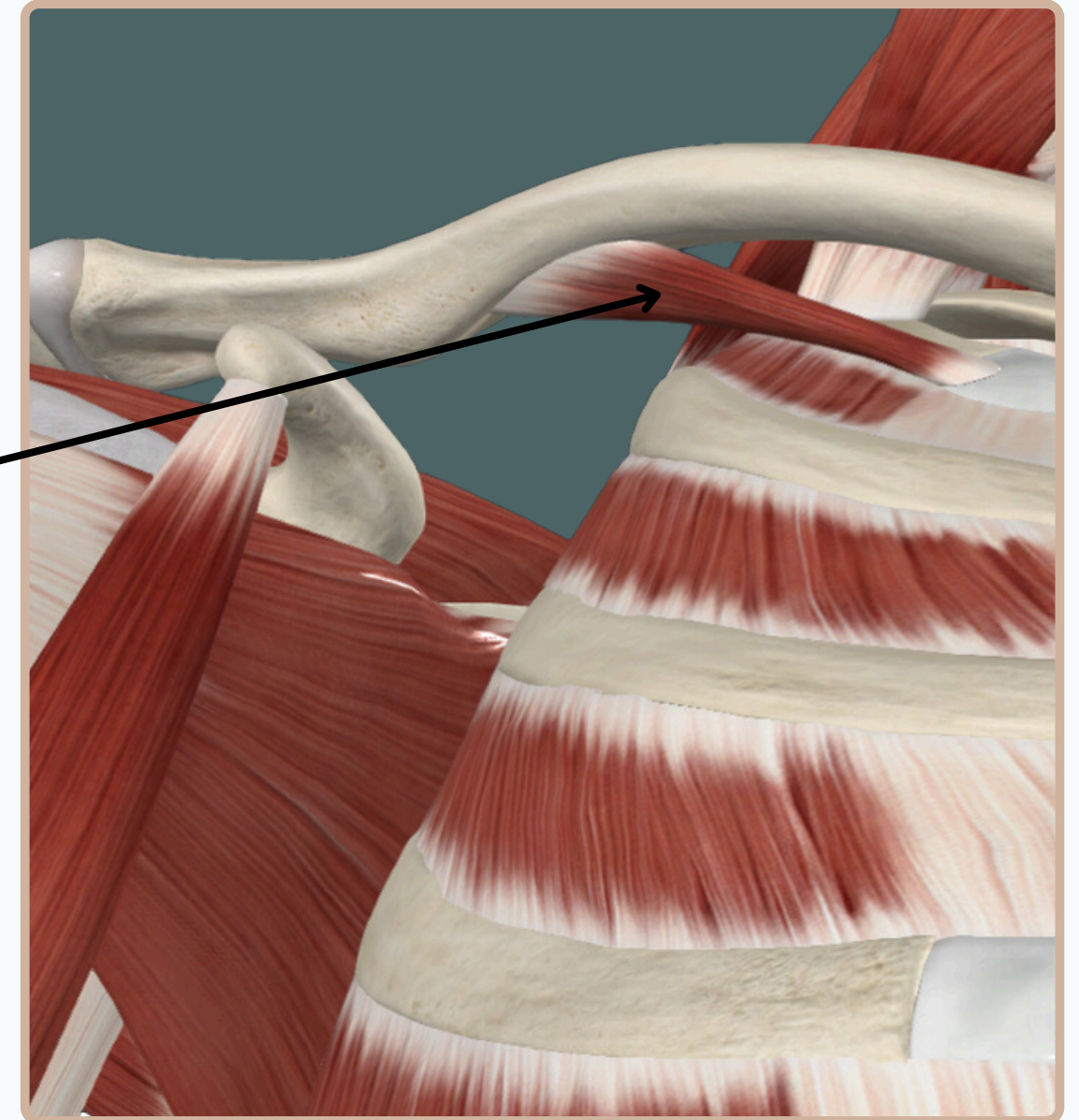
SUBCLAVIUS

Insertion : Subclavius groove

Origin : 1st rib and its costal cartilage



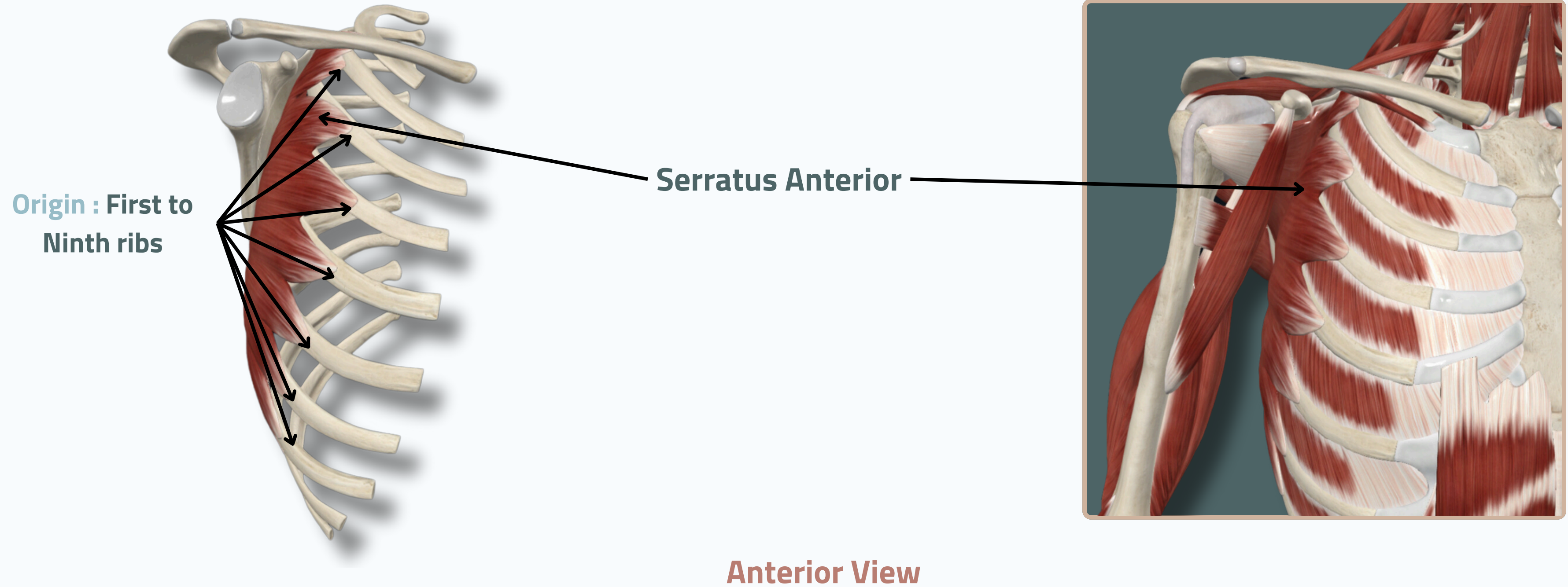
Subclavius



Anterior View

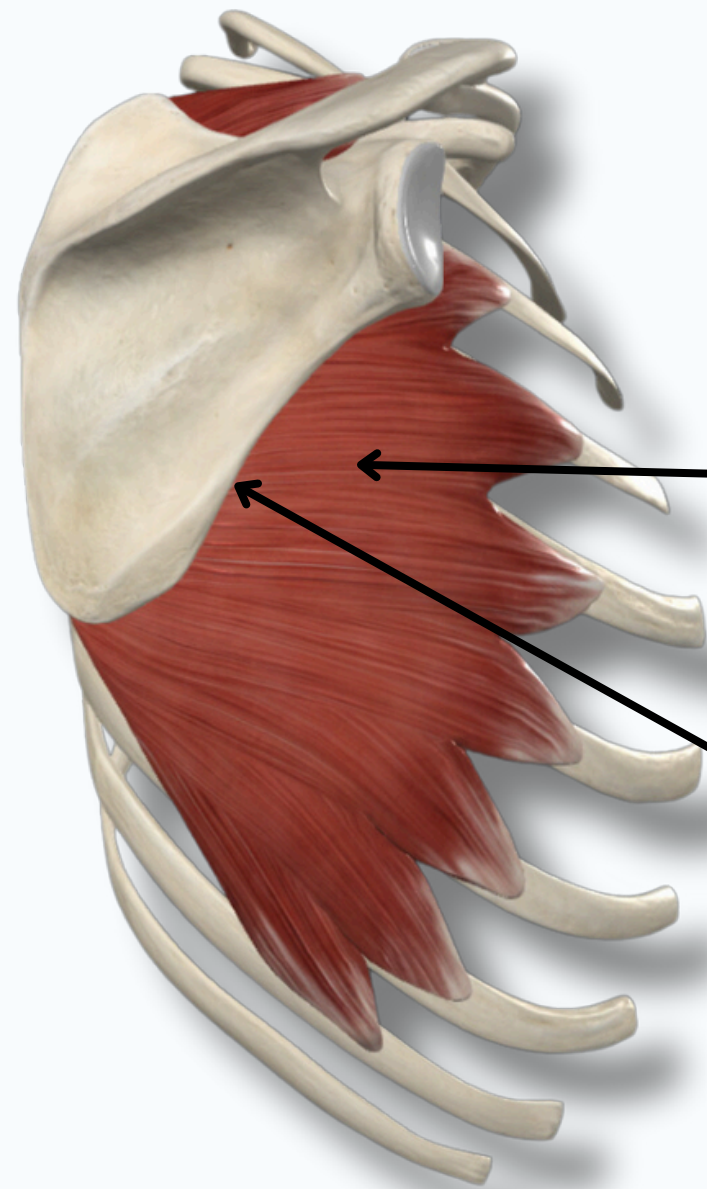
ANTERIOR THORACO-APPENDICULAR MUSCLES

SERRATUS ANTERIOR



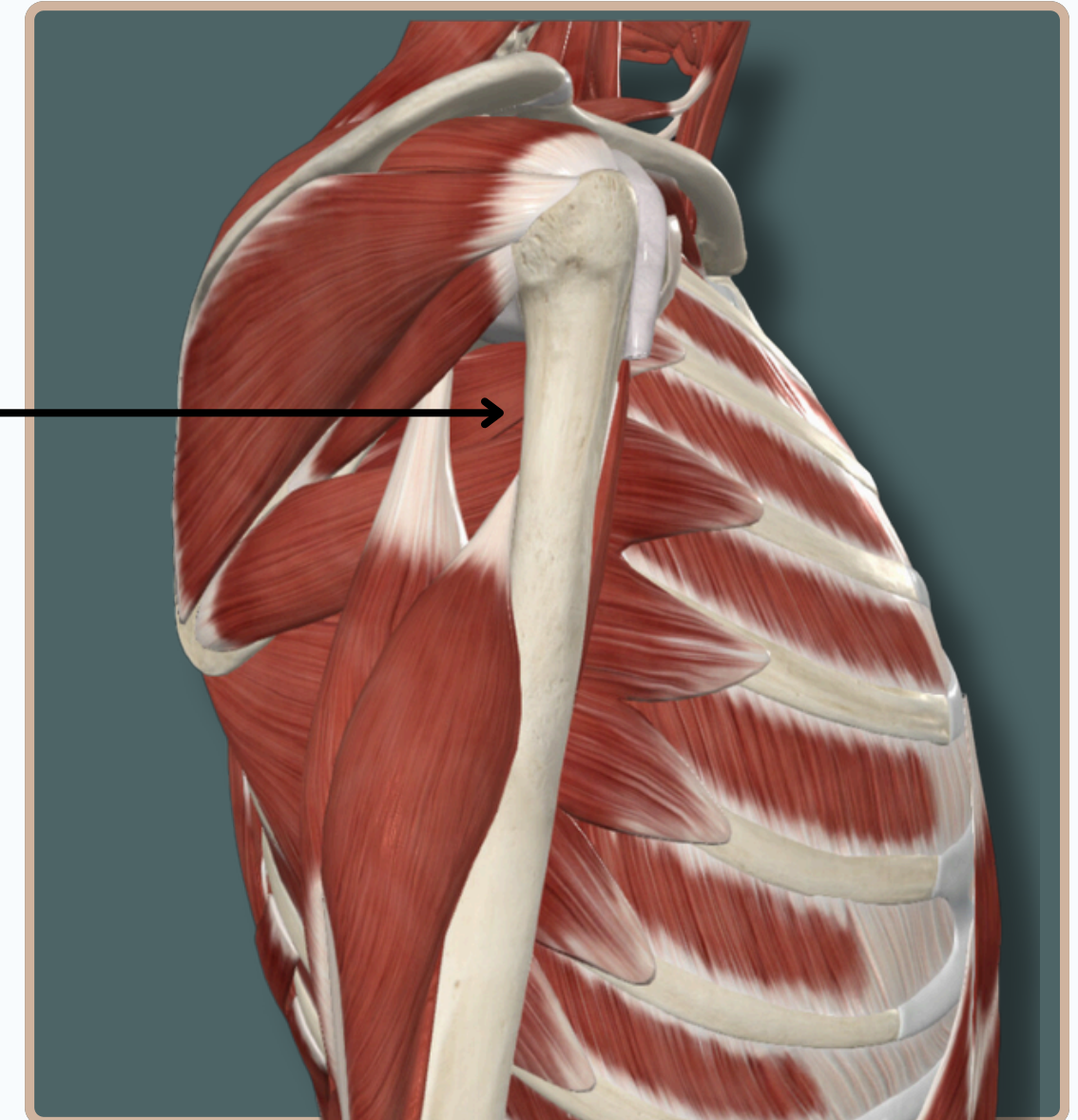
ANTERIOR THORACO-APPENDICULAR MUSCLES

SERRATUS ANTERIOR



Serratus Anterior

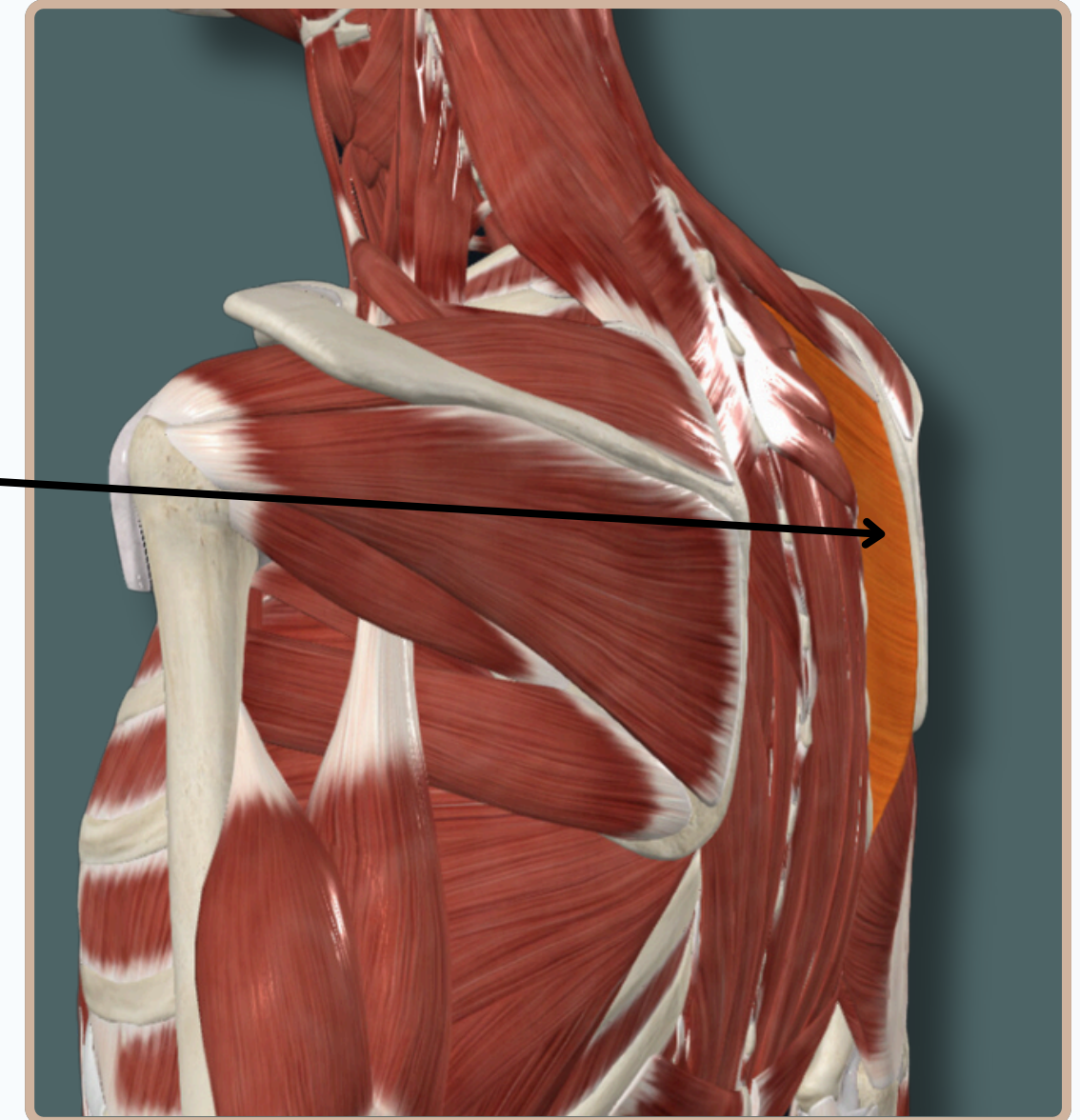
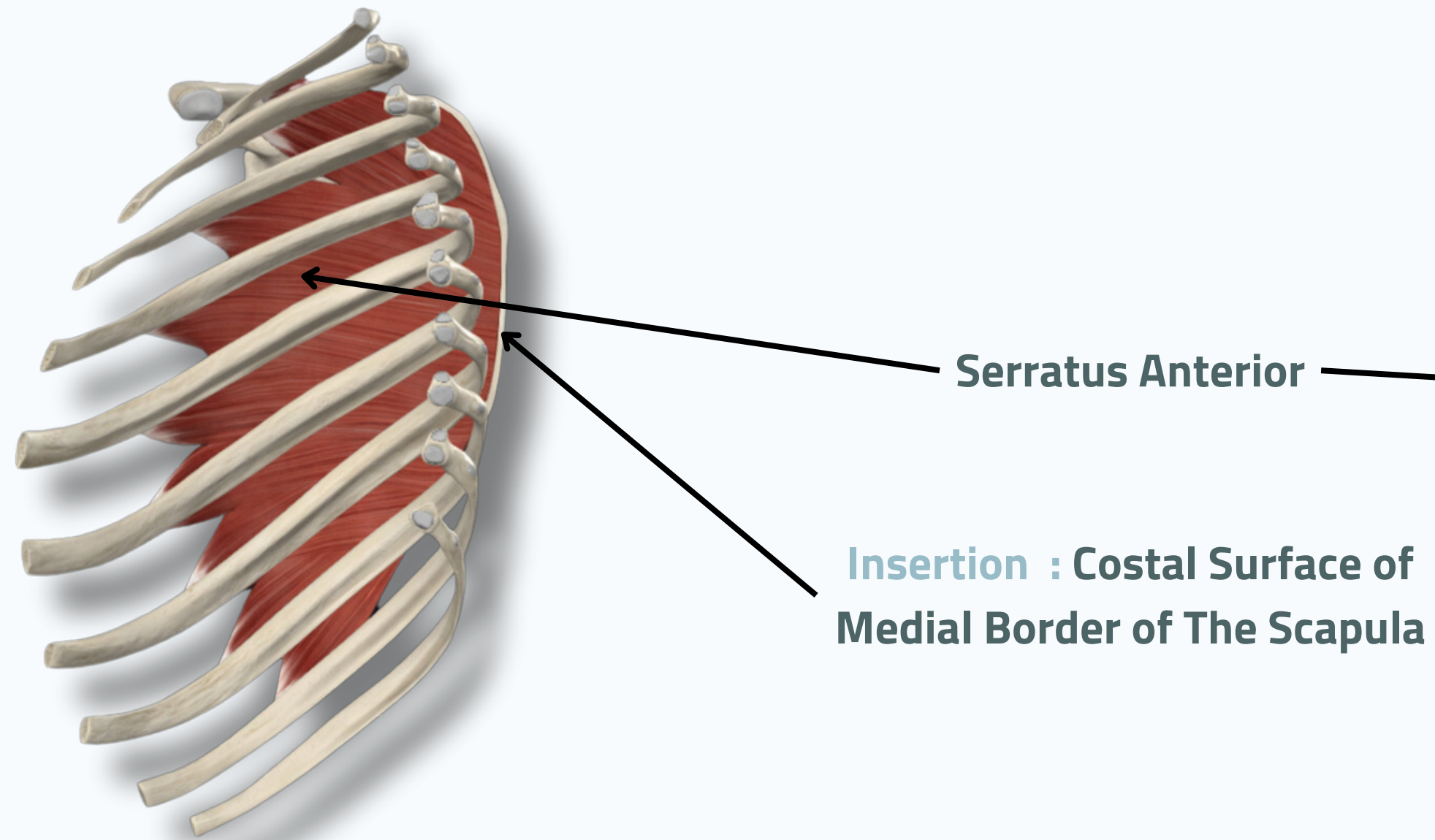
Insertion : Costal Surface of
Medial Border of The Scapula



Lateral View

ANTERIOR THORACO-APPENDICULAR MUSCLES

SERRATUS ANTERIOR



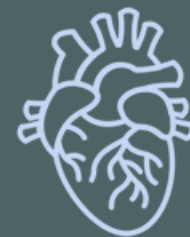Medial View

THANK YOU

EDITED BY



SATURN
MEDIC



ARECH

© ALL COPYRIGHT ARE RESERVED FOR
SATURN MEDIC AND ARECH

WWW.SATURNMEDIC.COM