

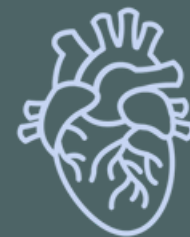ANATOMY OF UPPER LIMB

PRACTICAL LECTURE - 13 - BRACHIAL PLEXUS

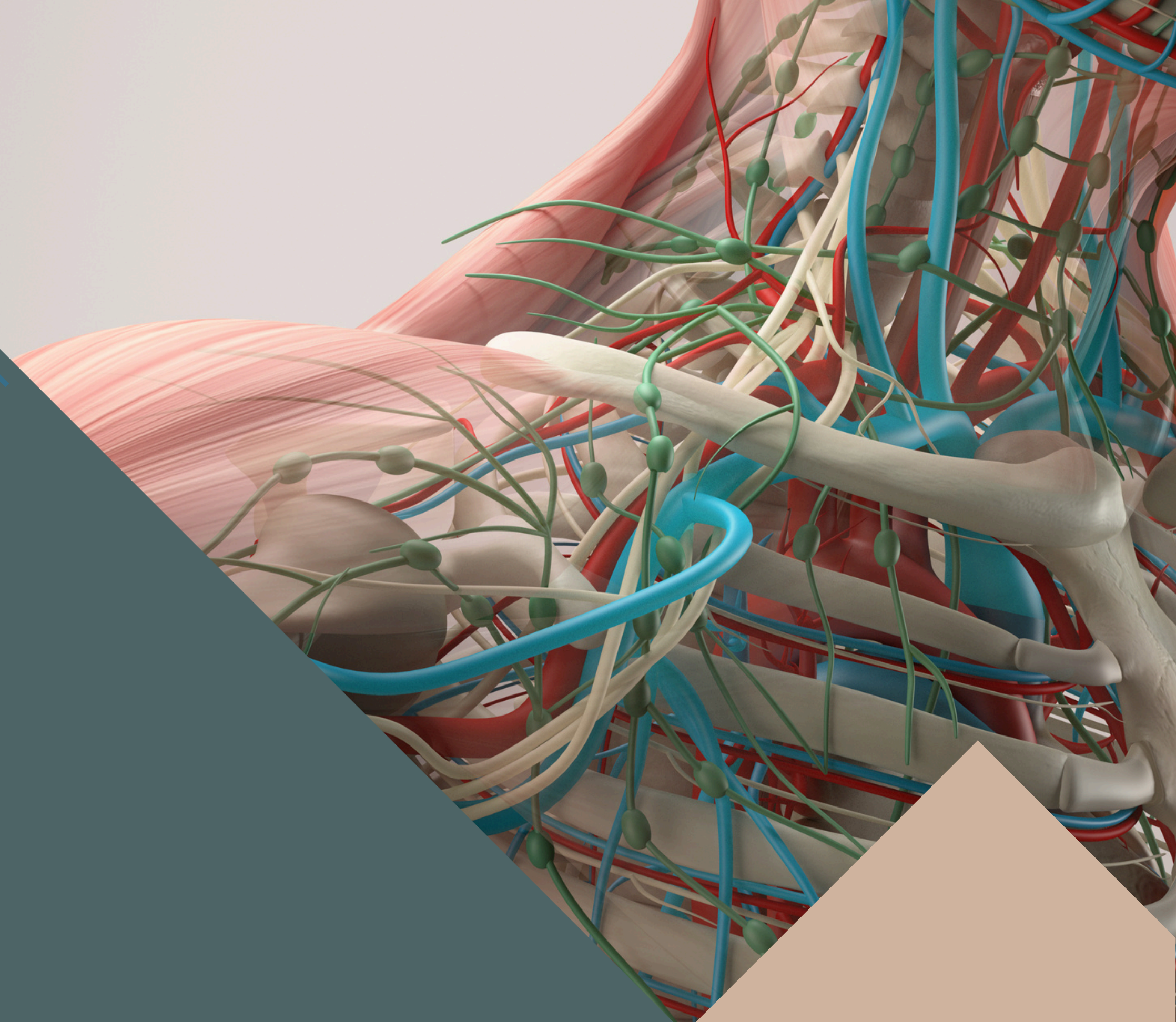
EDITED BY



SATURN
MEDIC

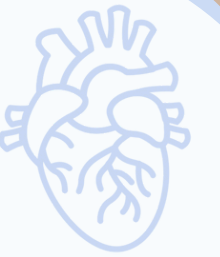

ARECH



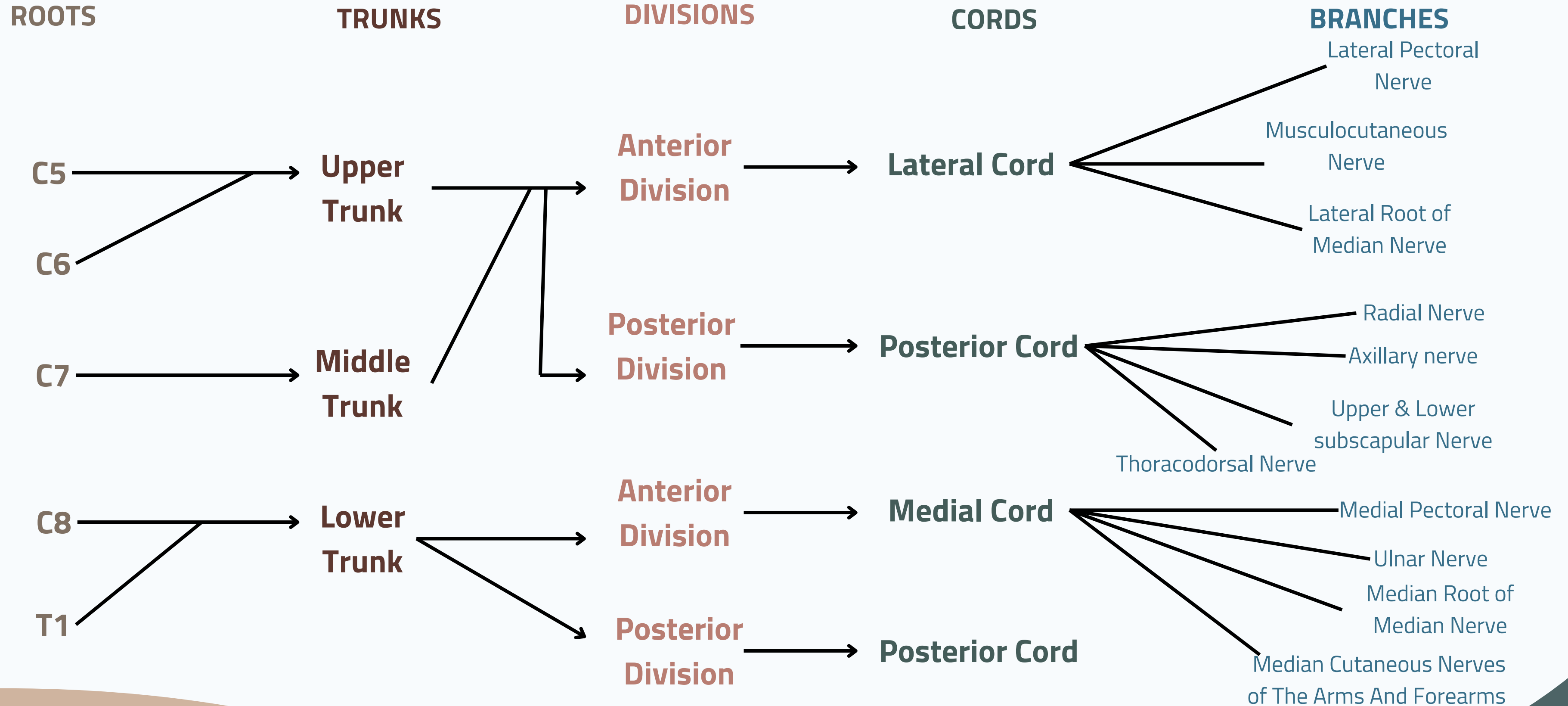
© ALL COPYRIGHT ARE RESERVED FOR
SATURN MEDIC AND ARECH

WWW.SATURNMEDIC.COM



BRACHIAL PLEXUS

BRACHIAL PLEXUS

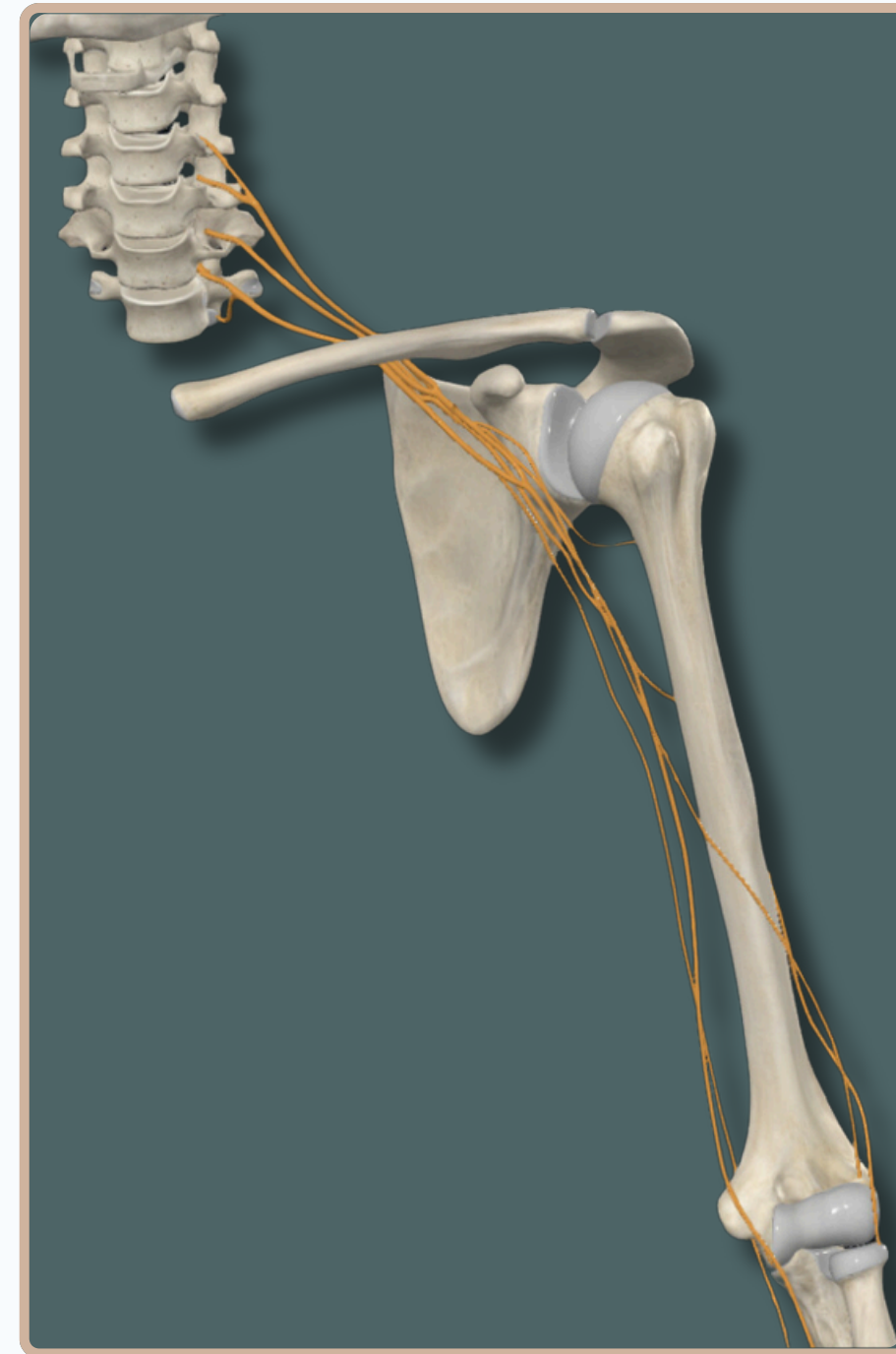
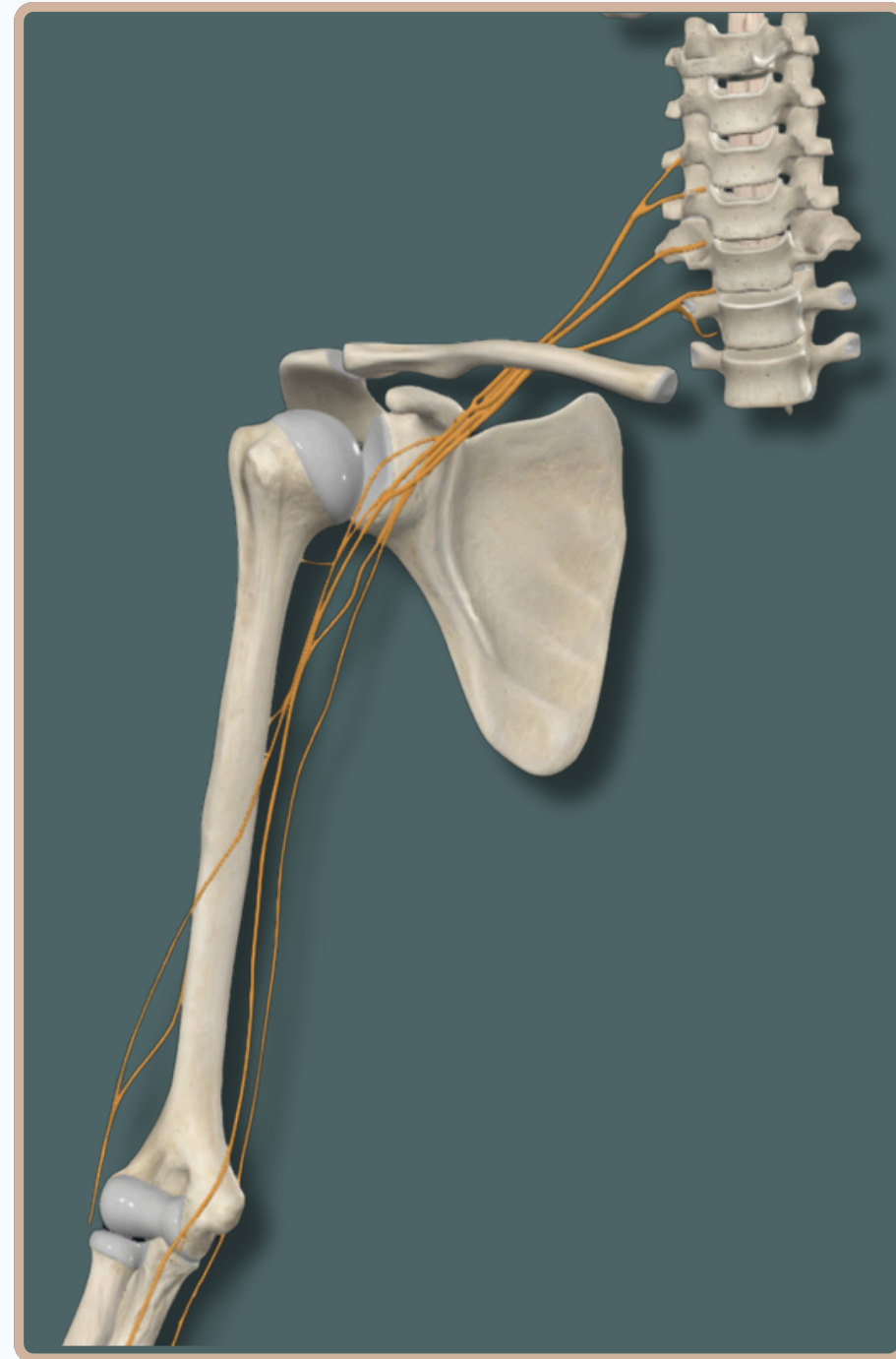




BRACHIAL PLEXUS



BRACHIAL PLEXUS



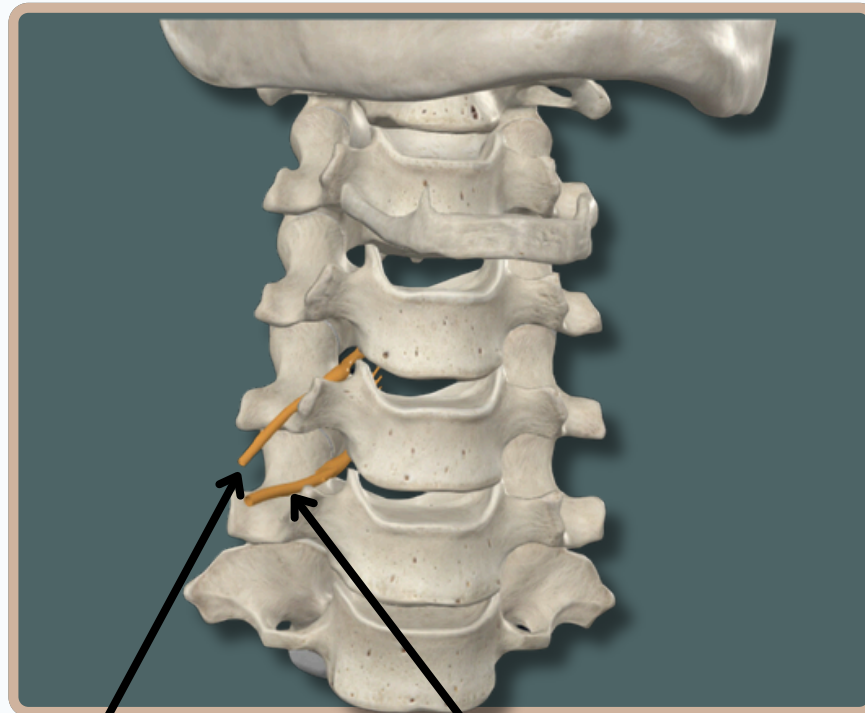
Anterior View



BRACHIAL PLEXUS

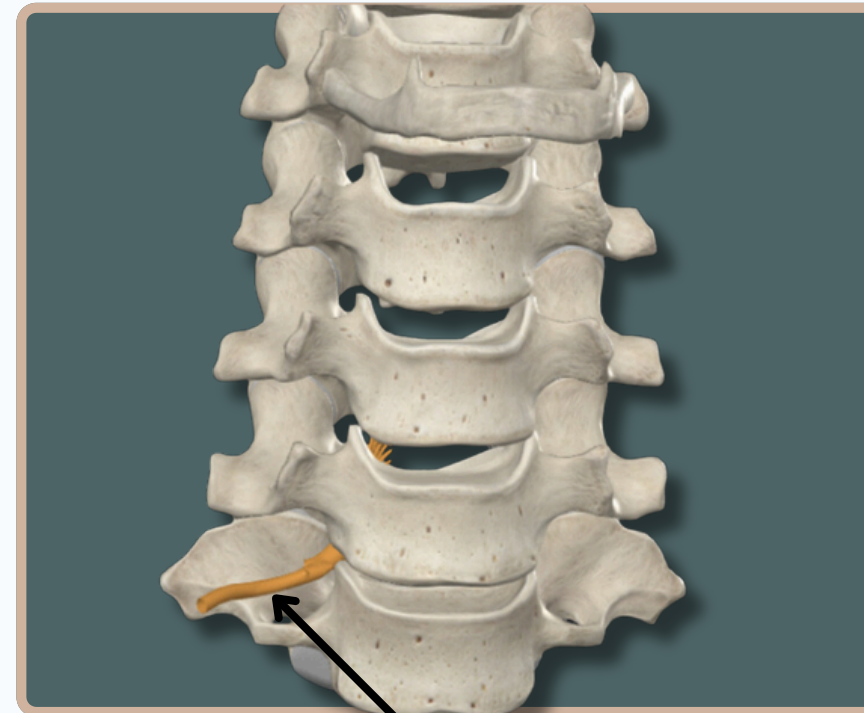

ROOTS OF BRACHIAL PLEXUS

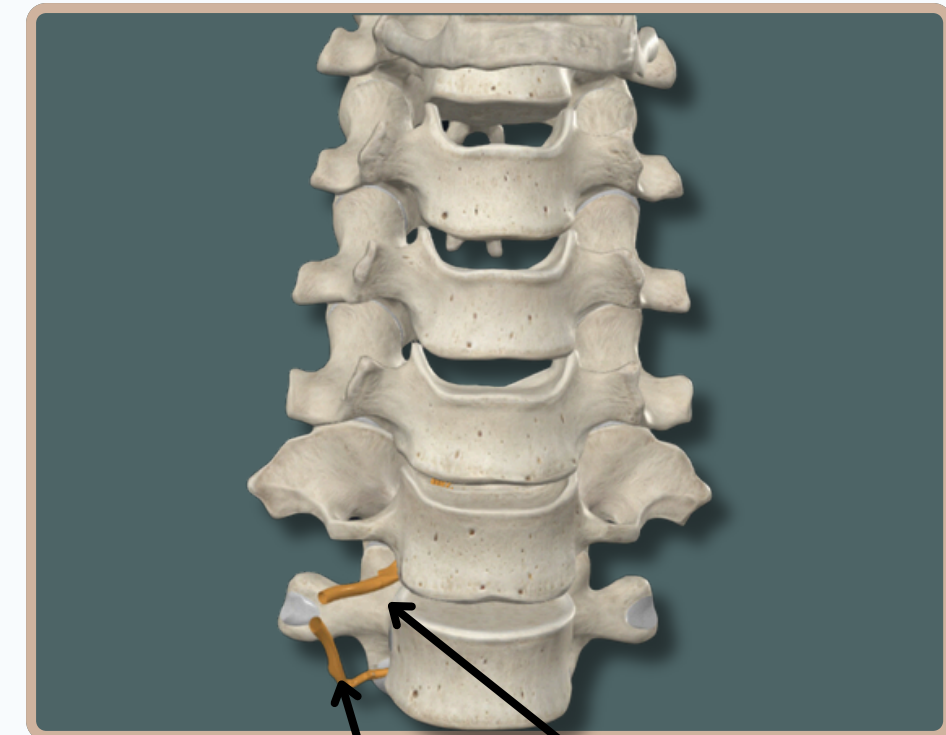

Ventral Rami of Fifth Cervical nerve

Ventral Rami of Sixth Cervical nerve



Ventral Rami of Seventh Cervical nerve



Ventral Rami of First Thoracic nerve

Ventral Rami of Eighth Cervical nerve

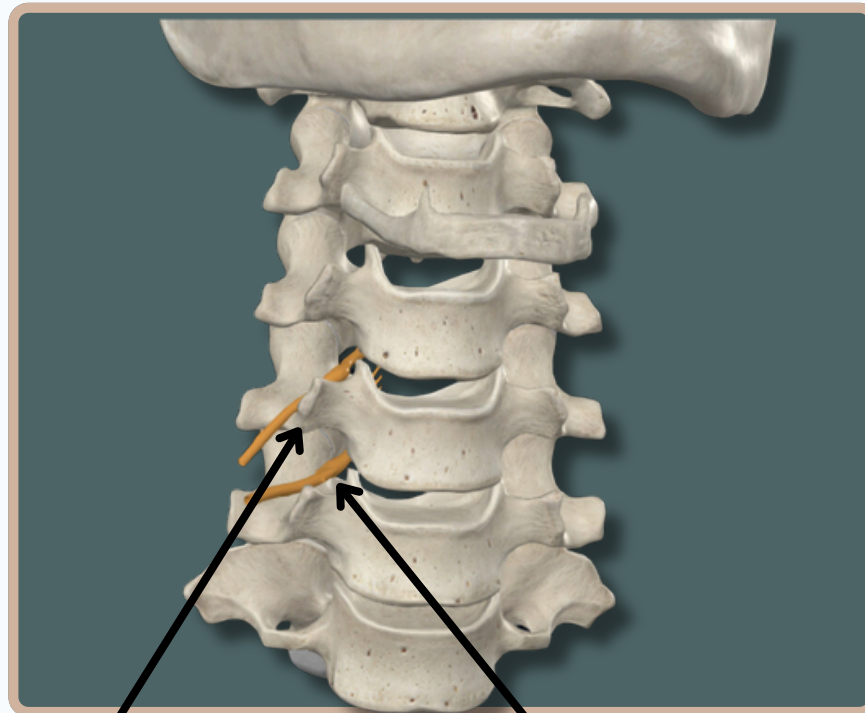
Anterior View



BRACHIAL PLEXUS

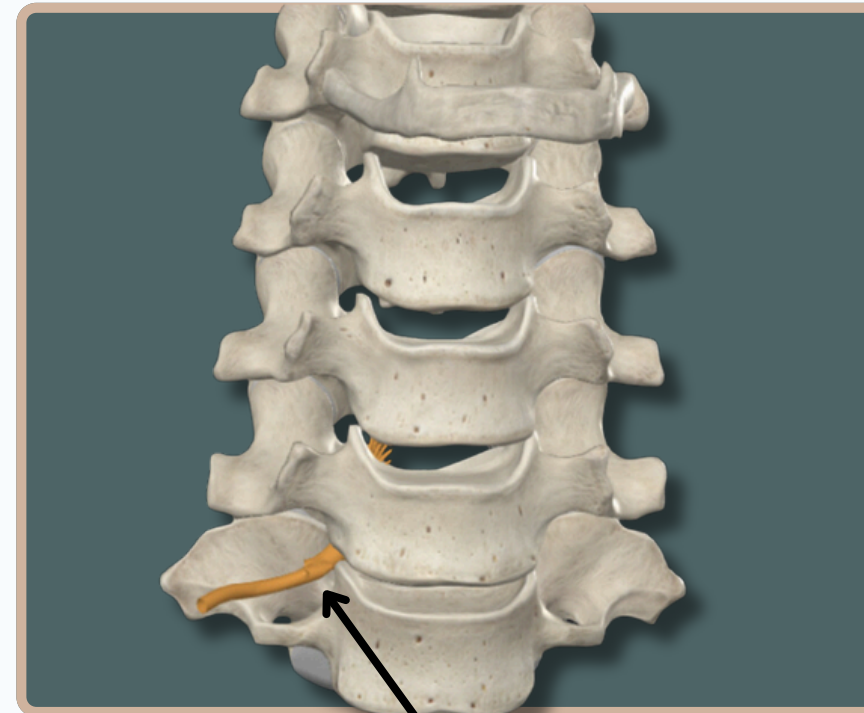

ROOTS OF BRACHIAL PLEXUS



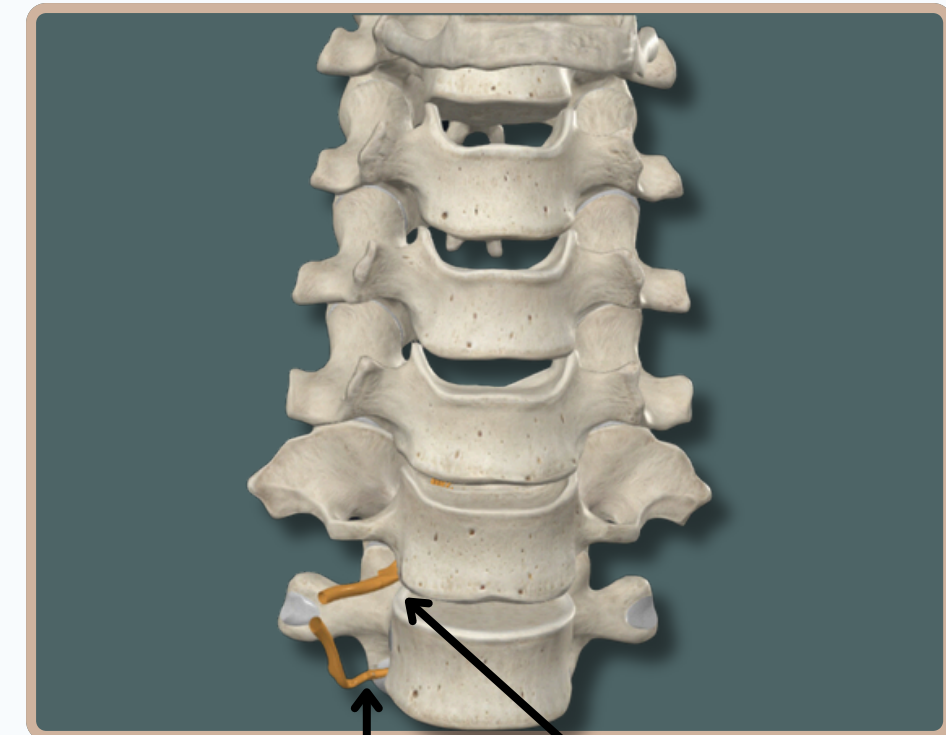**Fifth Cervical nerve
Above The Fifth Cervical
Vertebra**

**Sixth Cervical nerve
Above The Sixth Cervical
Vertebra**



**Seventh Cervical nerve
Above The Seventh
Cervical Vertebra**

Anterior View



**First Thoracic nerve
Below The First Thoracic
Vertebra**

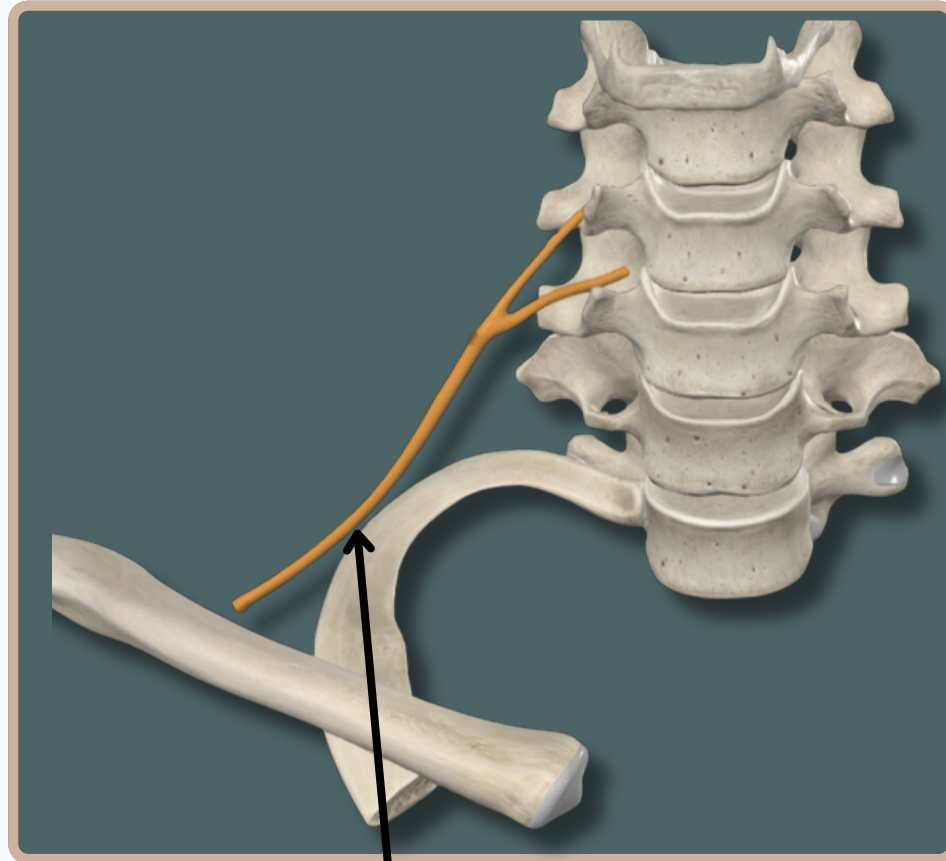
**Eighth Cervical nerve
Below The Seventh
Cervical Vertebra**



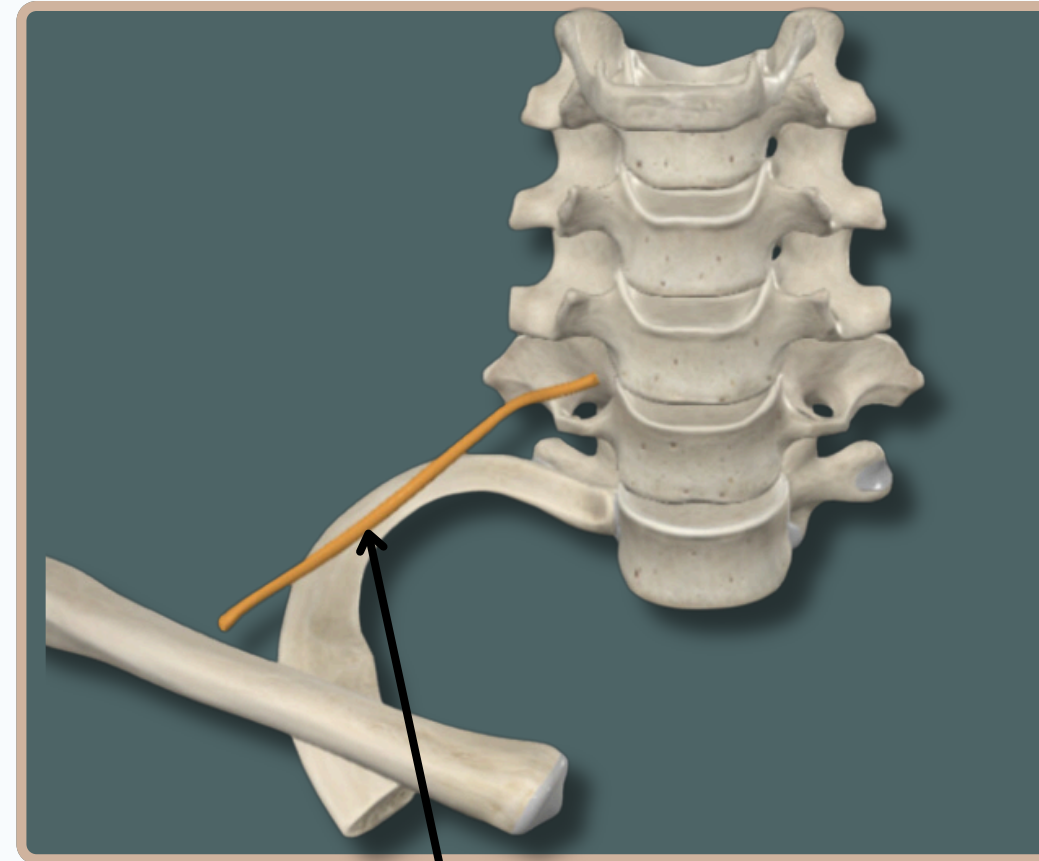
BRACHIAL PLEXUS



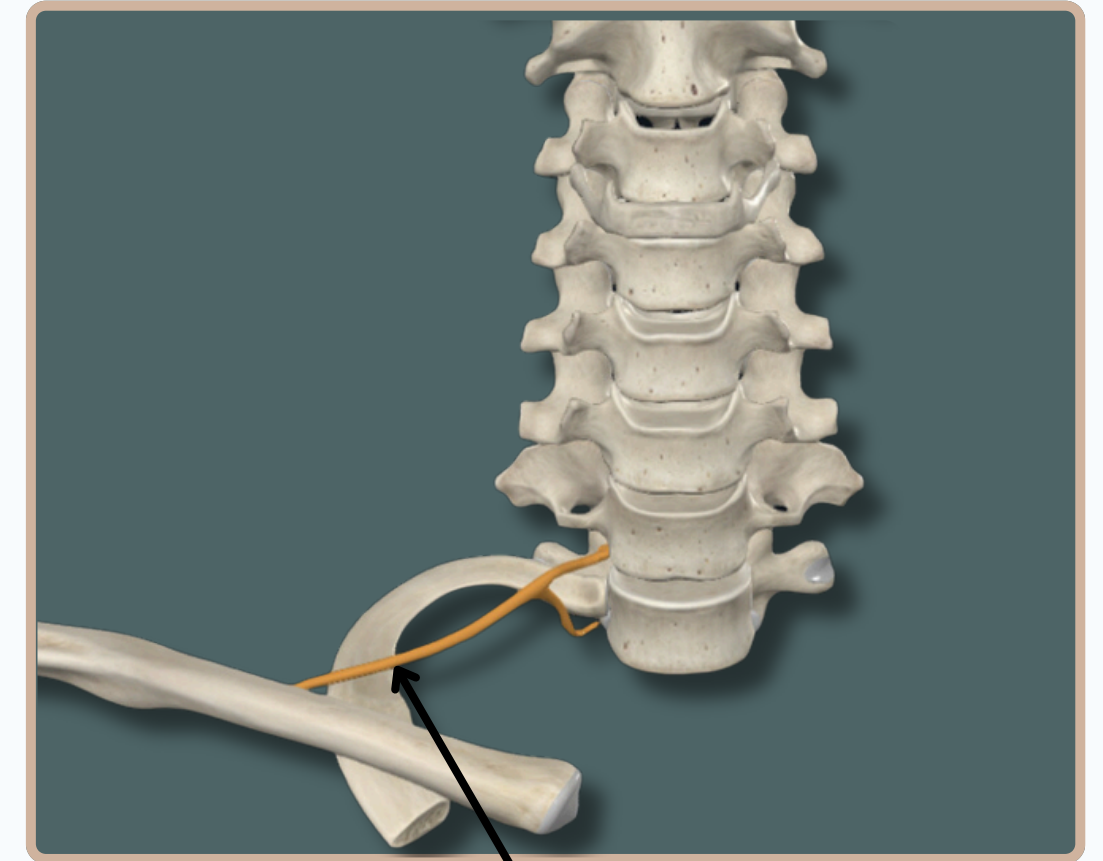
TRUNKS OF BRACHIAL PLEXUS



Fifth & Sixth Cervical Nerves
Unite To Form **The Superior
Trunk**



Seventh Cervical Nerve Form
The Middle Trunk



Eighth Cervical Nerve & First
Thoracic Nerve Unite To Form
The Inferior Trunk

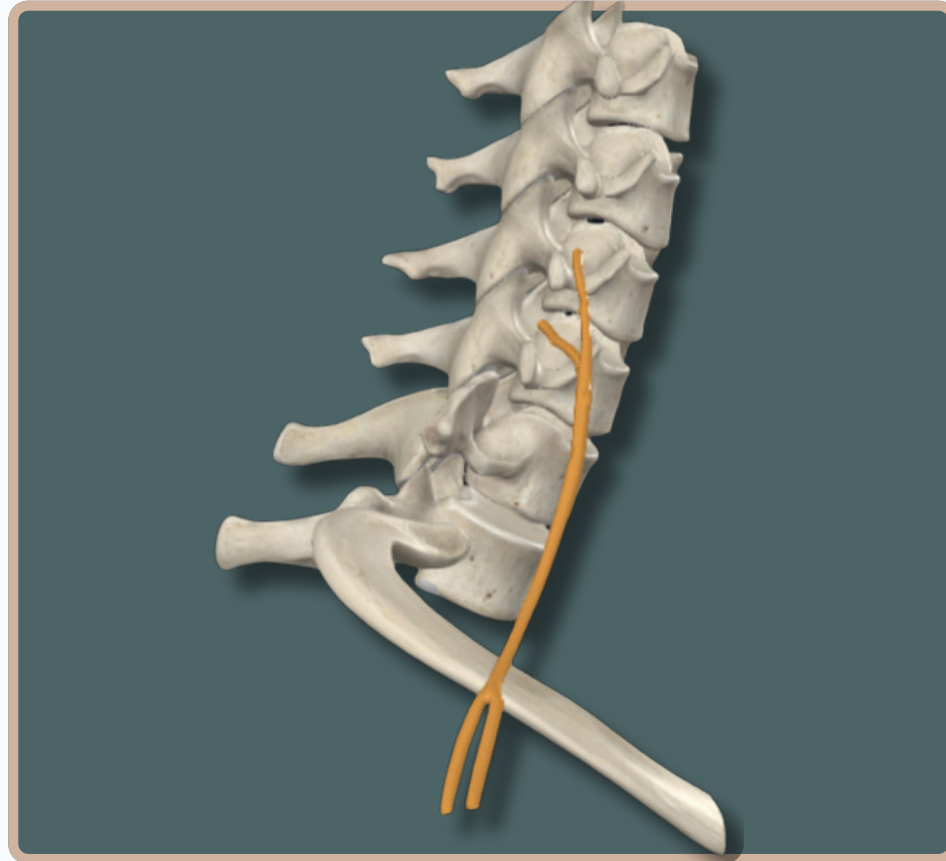
Anterior View



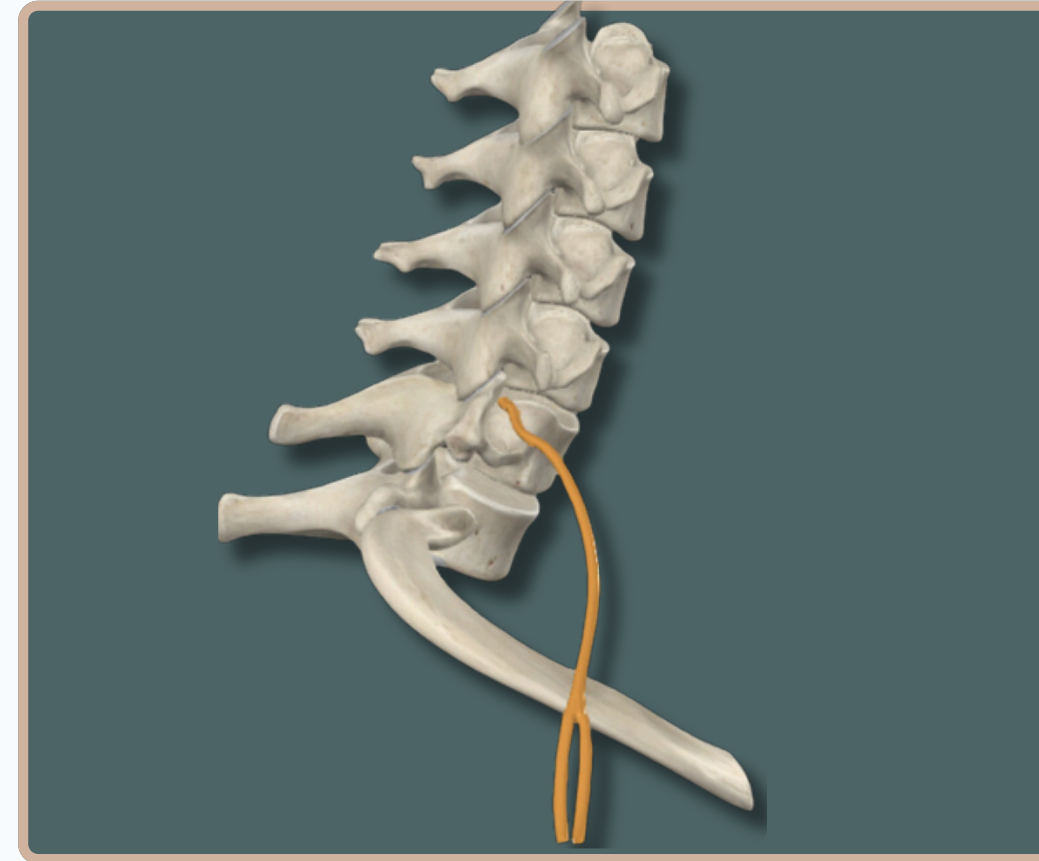
BRACHIAL PLEXUS



DIVISIONS OF BRACHIAL PLEXUS

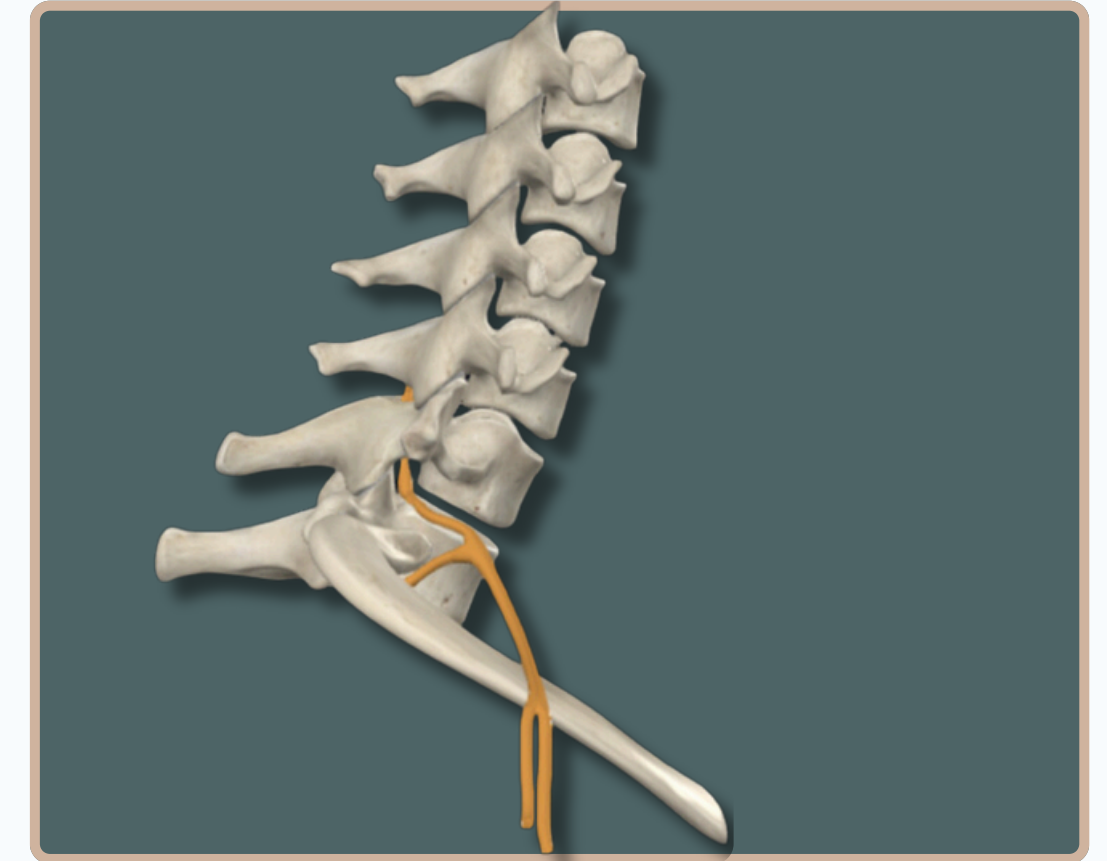


The Superior Trunk **Divides** Into
Anterior And Posterior
Divisions



The Middle Trunk **Divides** Into
Anterior And Posterior
Divisions

Anterior View



The Inferior Trunk **Divides** Into
Anterior And Posterior
Divisions

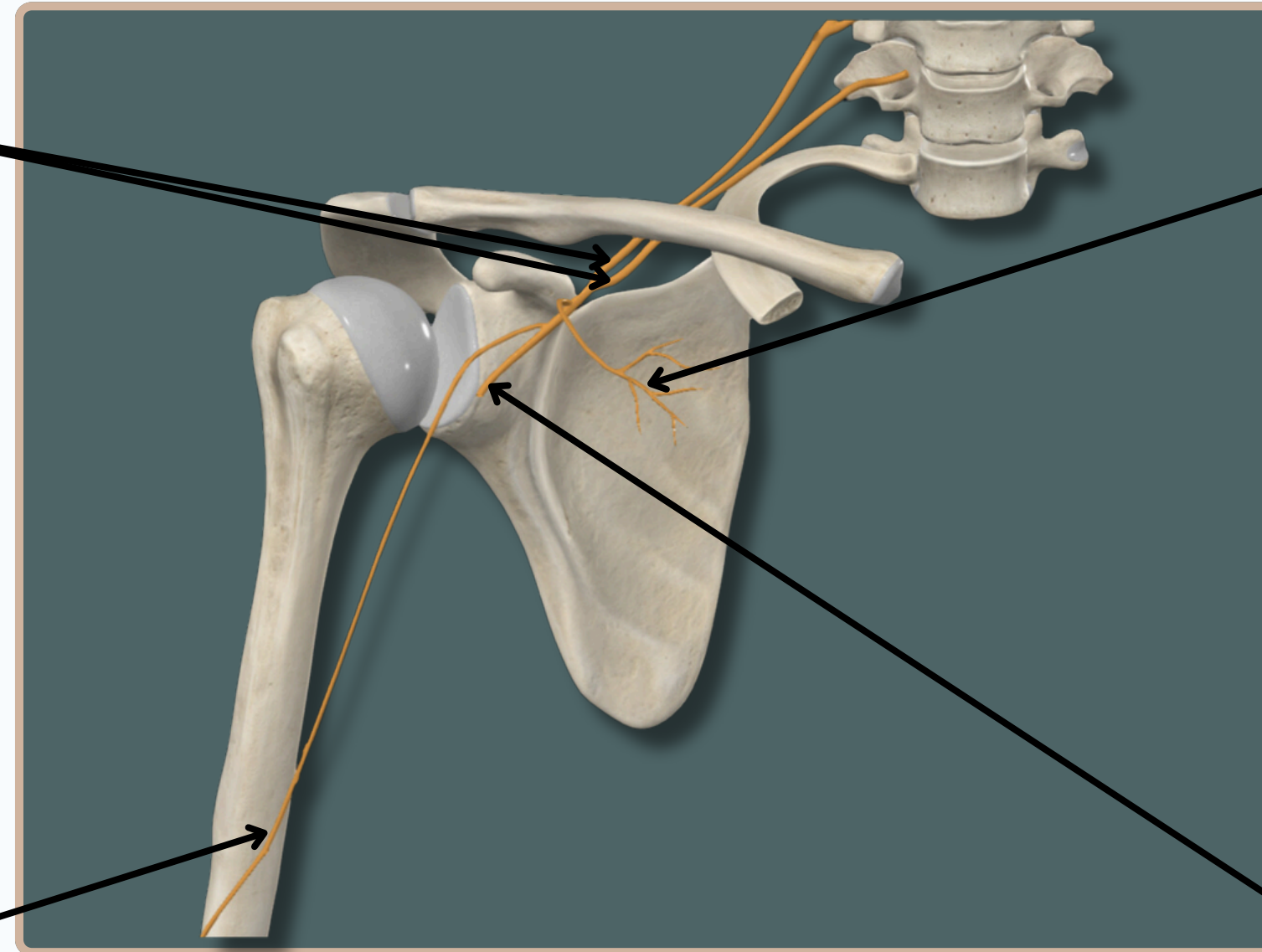


BRACHIAL PLEXUS



CORDS OF BRACHIAL PLEXUS

The Lateral Cord Consist of Anterior Divisions of Upper & Middle Trunks



Lateral pectoral Nerve
Supplies :

- Pectoralis Major

Musculocutaneous Nerve

Supplies :

- Biceps Brachii
- Brachialis
- Coracobrachialis

Lateral Root of Median Nerve
Supplies :

- Motor Innervation To The Muscles of The Anterior Compartment of The Forearm And The Hand Musculature

Anterior View



BRACHIAL PLEXUS



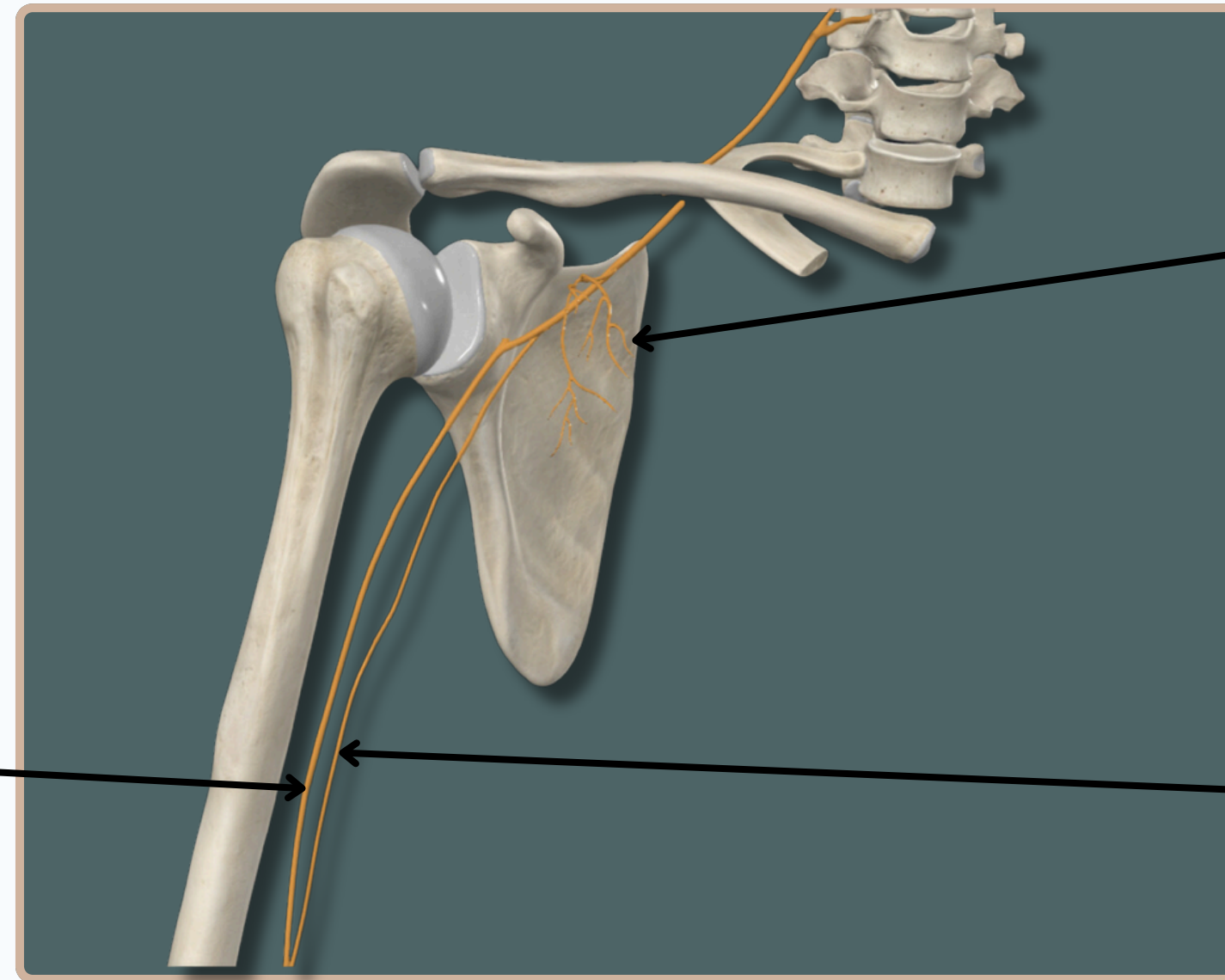
CORDS OF BRACHIAL PLEXUS

The Medial Cord Consist of Anterior Divisions of The Lower Trunk

Median Nerve

Supplies :

- Most of The Superficial And Deep Flexors In The Forearm
- Thenar And Lumbrical Muscles



Medial pectoral Nerve

Supplies :

- Pectoralis Major
- Pectoralis Minor

Ulnar Nerve

Supplies :

Sensory Cutaneous Innervation To

- The Medial Forearm
- Medial wrist
- Medial One And One-Half Digits.

Anterior View



BRACHIAL PLEXUS



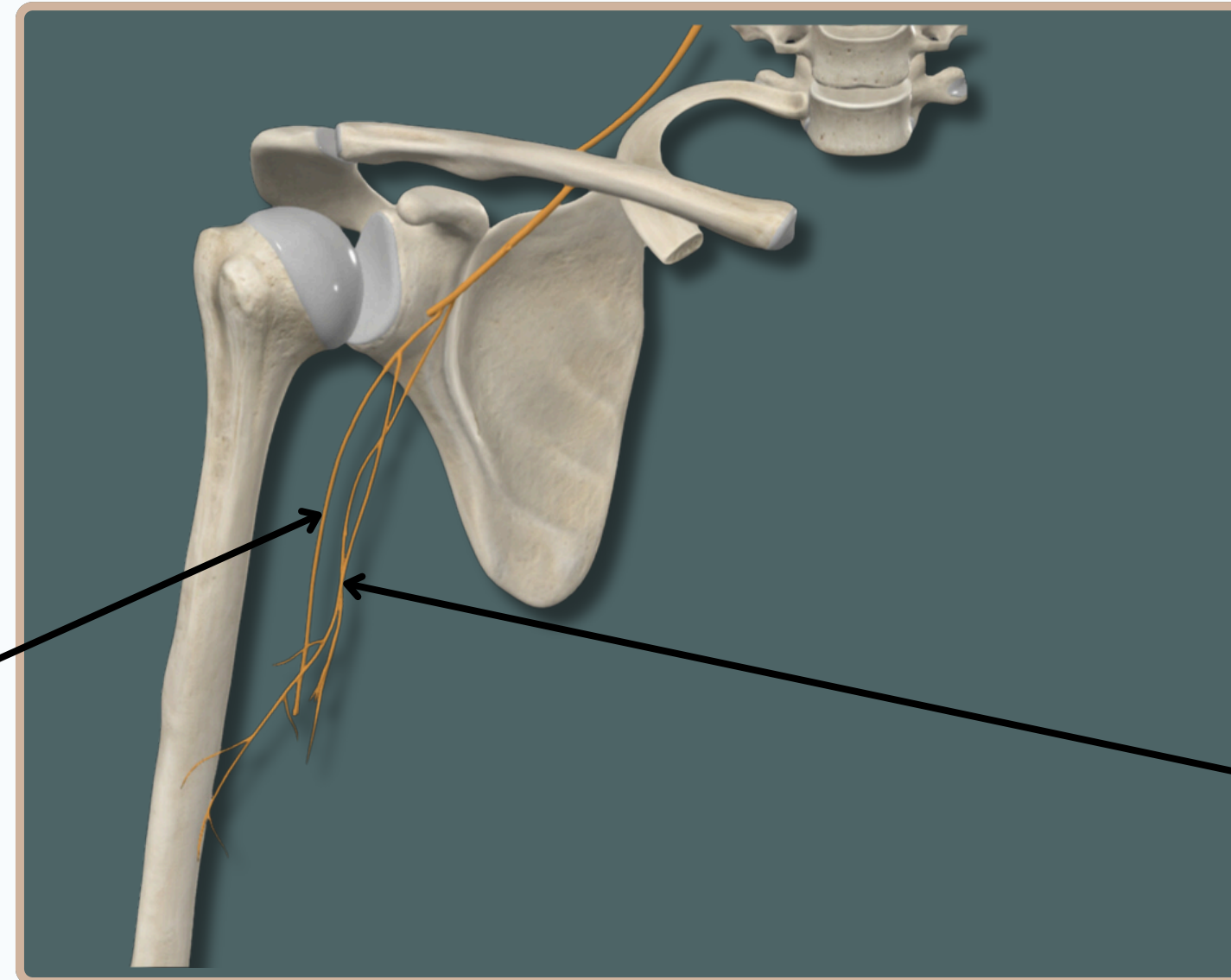
CORDS OF BRACHIAL PLEXUS

The Medial Cord Consist of Anterior Divisions of The Lower Trunk

Medial Brachial Cutaneous Nerve

Supplies :

- The Skin of The Medial Side of The Arm As Far Distal As The Medial Epicondyle



Medial Antebrachial Cutaneous Nerve

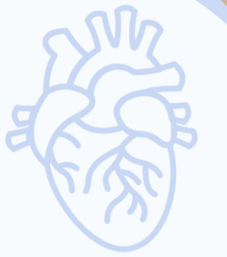Supplies :

- Skin Over The Anterior Surface of The Lower Half of The Arm, The Cubital Fossa, And Anteromedial Surface of The Arm

Anterior View

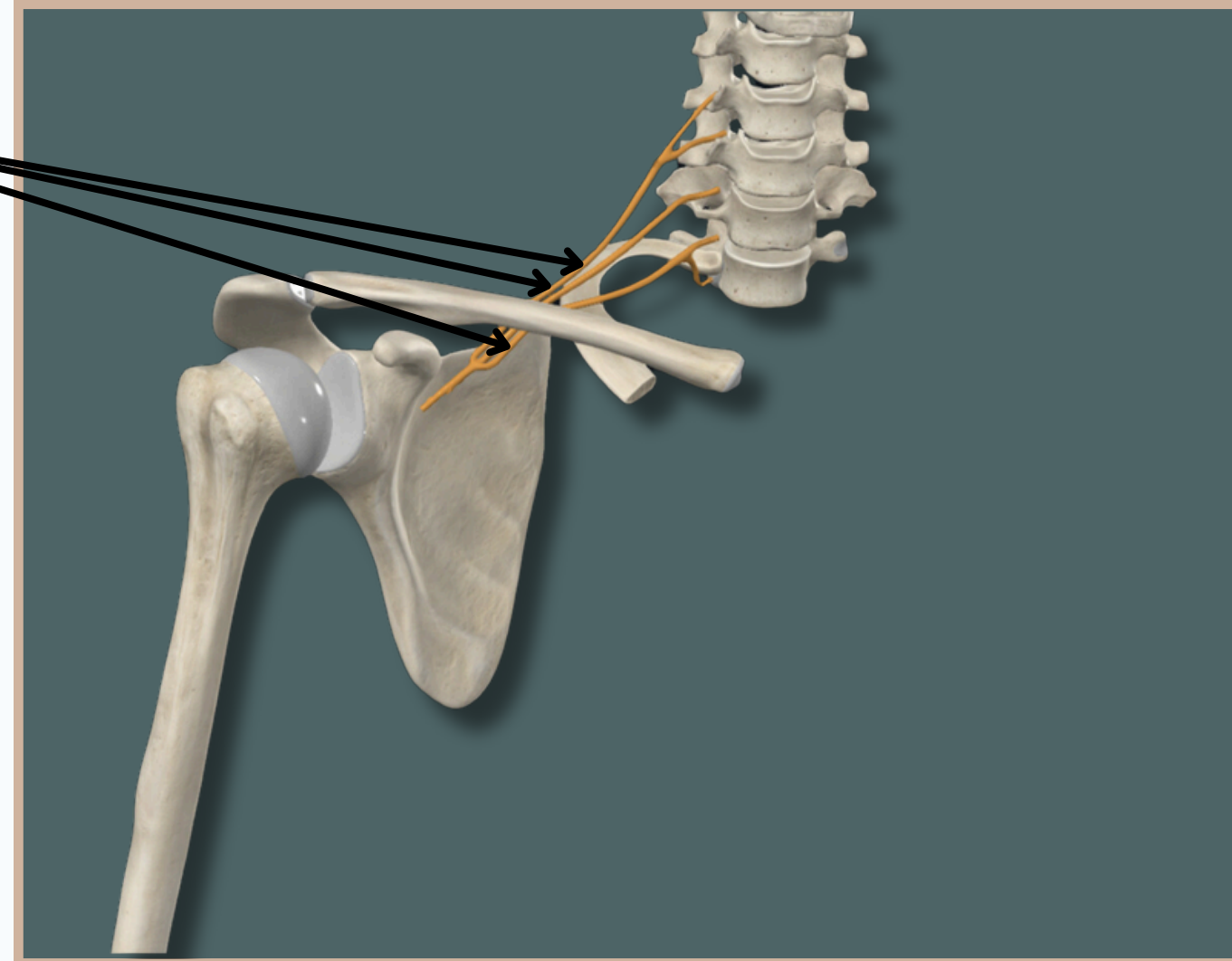


BRACHIAL PLEXUS



CORDS OF BRACHIAL PLEXUS

The Posterior Cord Consist of
Posterior Divisions of The
Upper, Medial And Lower Trunks



Anterior View



BRACHIAL PLEXUS



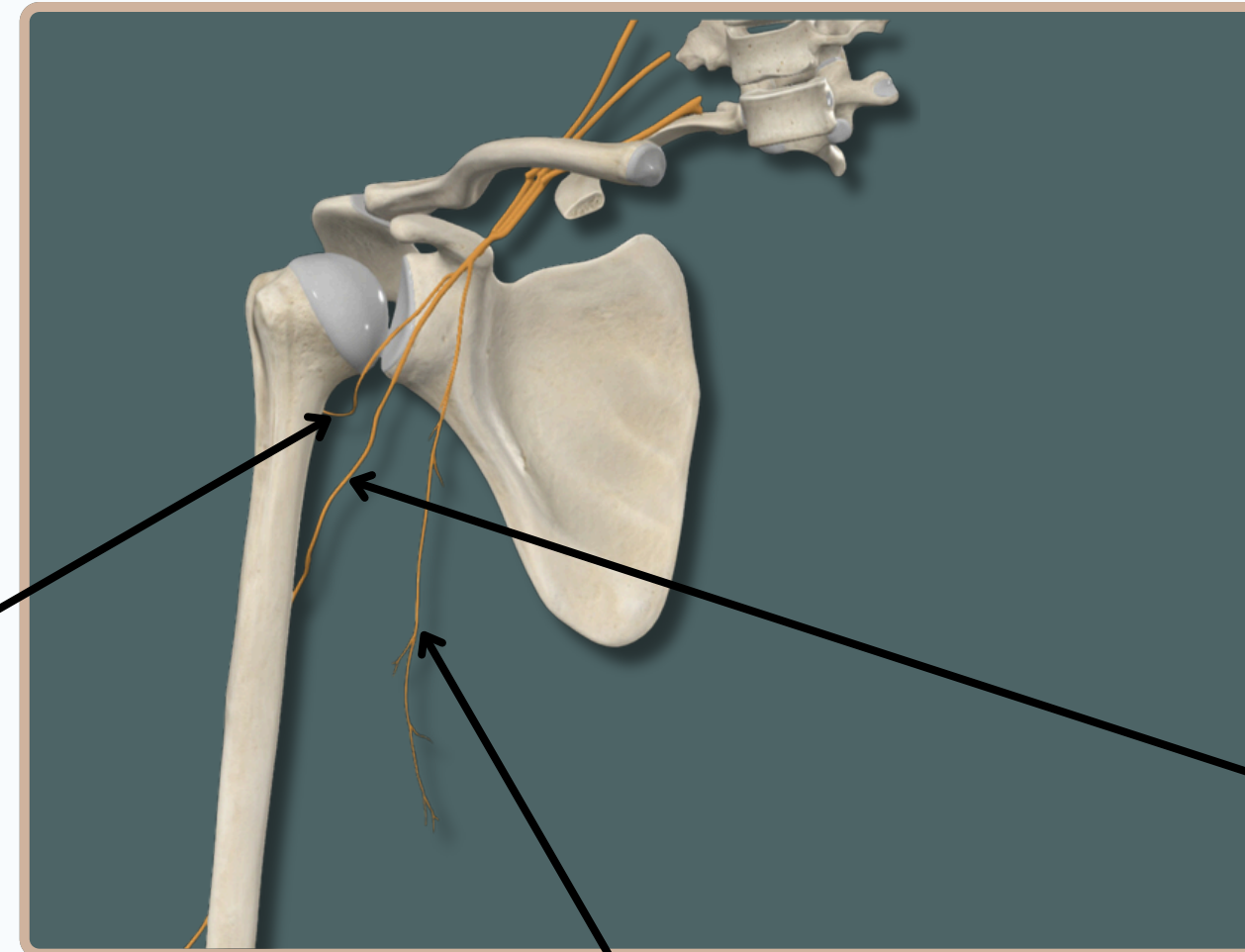
CORDS OF BRACHIAL PLEXUS

The Posterior Cord Consist of
Posterior Divisions of The
Upper, Medial And Lower Trunks

Axillary Nerve

Supplies :

- Deltoid Muscle
- Teres Minor



Radial Nerve

Supplies :

- Motor Supply For The
Posterior Muscles of The
Arm and Forearm,
- Sensory Supply of The Skin
of The Arm, Forearm and
Hand

Thoracodorsal Nerve

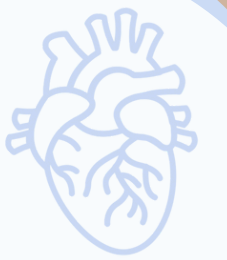Supplies :

- Latissimus Dorsi Muscle

Anterior View



BRACHIAL PLEXUS

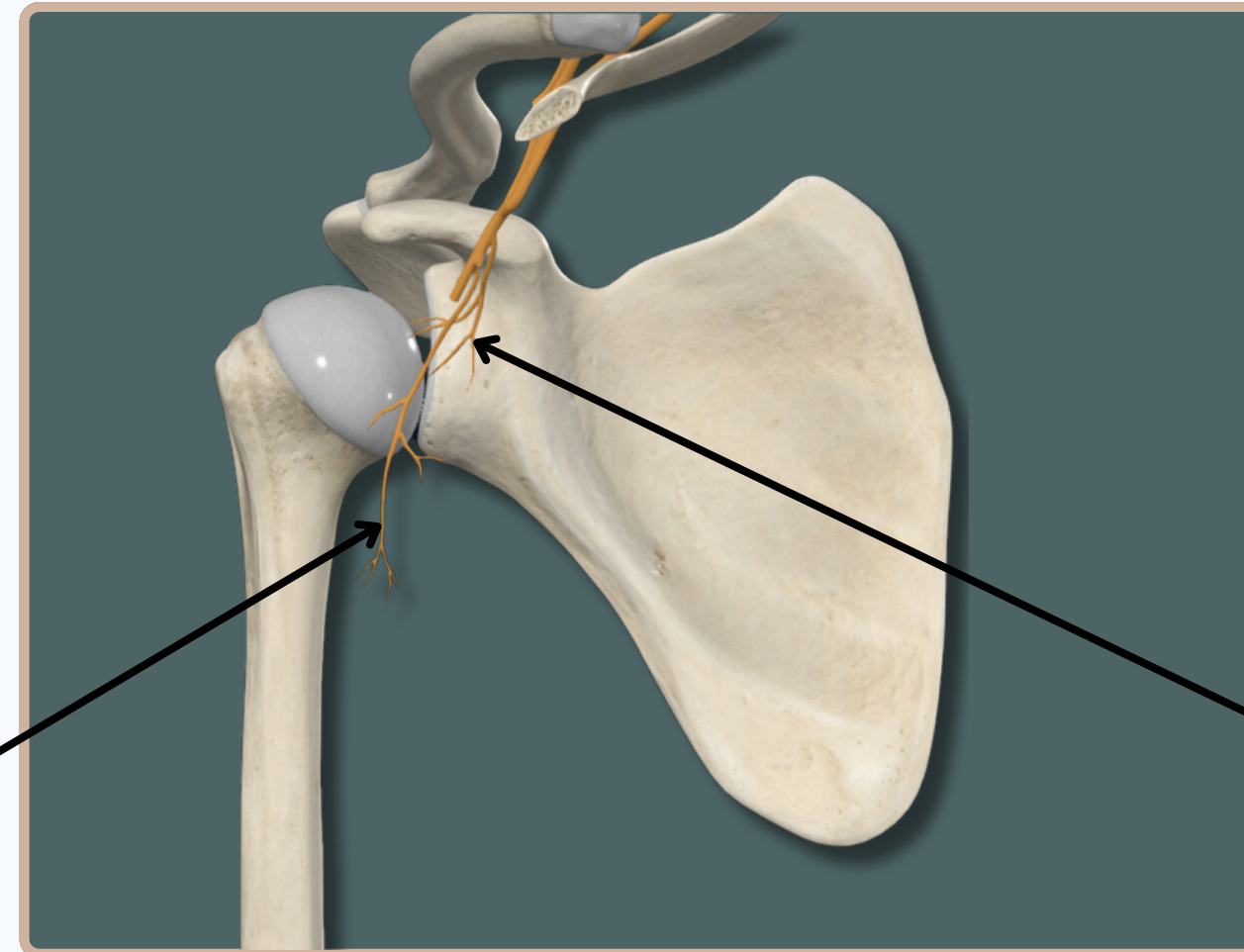


CORDS OF BRACHIAL PLEXUS

The Posterior Cord Consist of
Posterior Divisions of The
Upper, Medial And Lower Trunks

**Inferior Subscapular Nerve
Supplies :**

- Subscapularis Muscle



**Superior Subscapular Nerve
Supplies :**

- Subscapularis Muscle

Anterior View

THANK YOU

EDITED BY



SATURN
MEDIC



ARECH

© ALL COPYRIGHT ARE RESERVED FOR
SATURN MEDIC AND ARECH

WWW.SATURNMEDIC.COM