

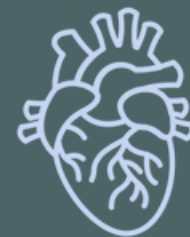ANATOMY OF UPPER LIMB

PRACTICAL LECTURE - 15 - LYMPHATIC SYSTEM

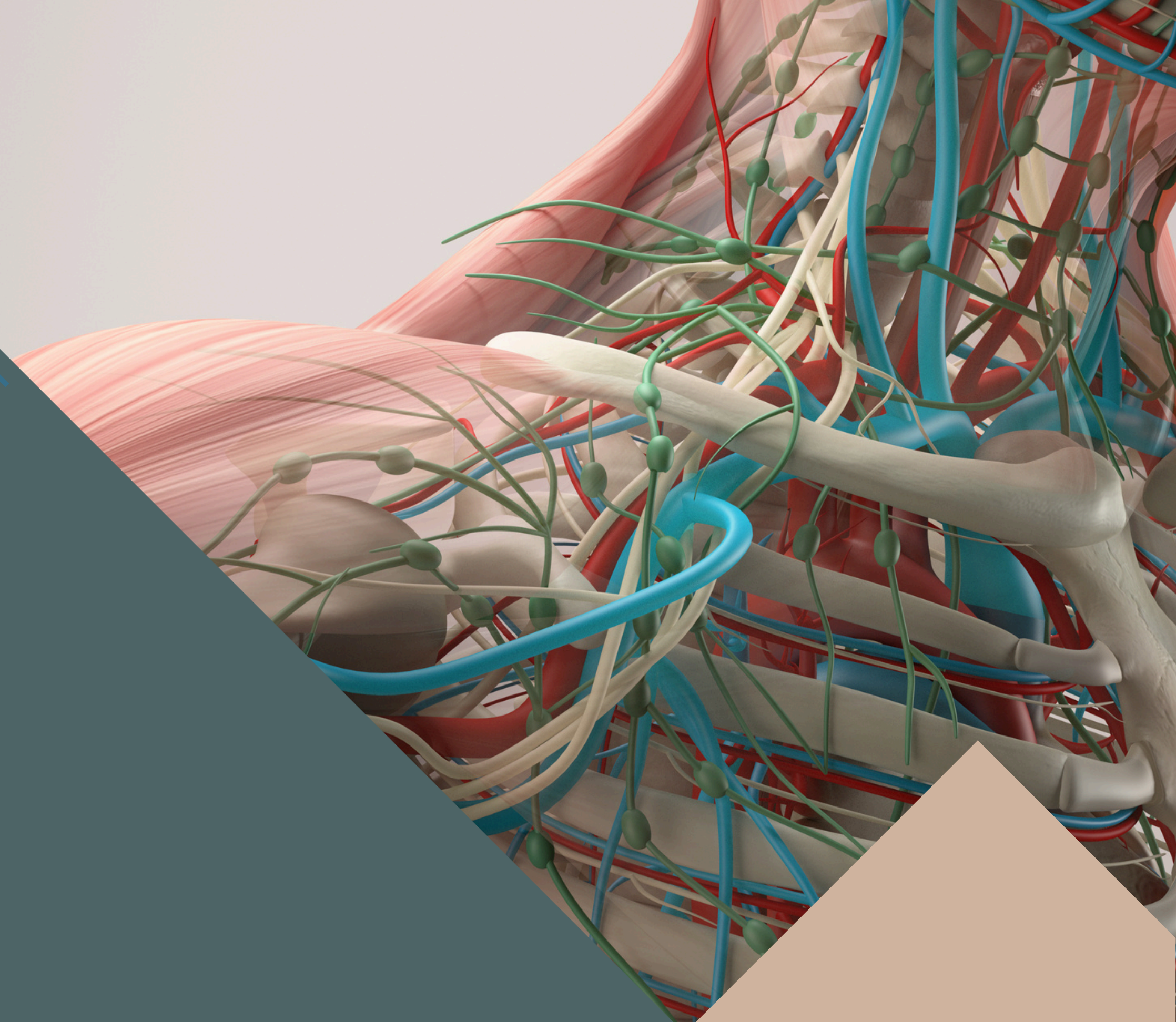
EDITED BY



SATURN
MEDIC



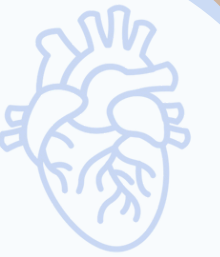ARECH



© ALL COPYRIGHT ARE RESERVED FOR
SATURN MEDIC AND ARECH

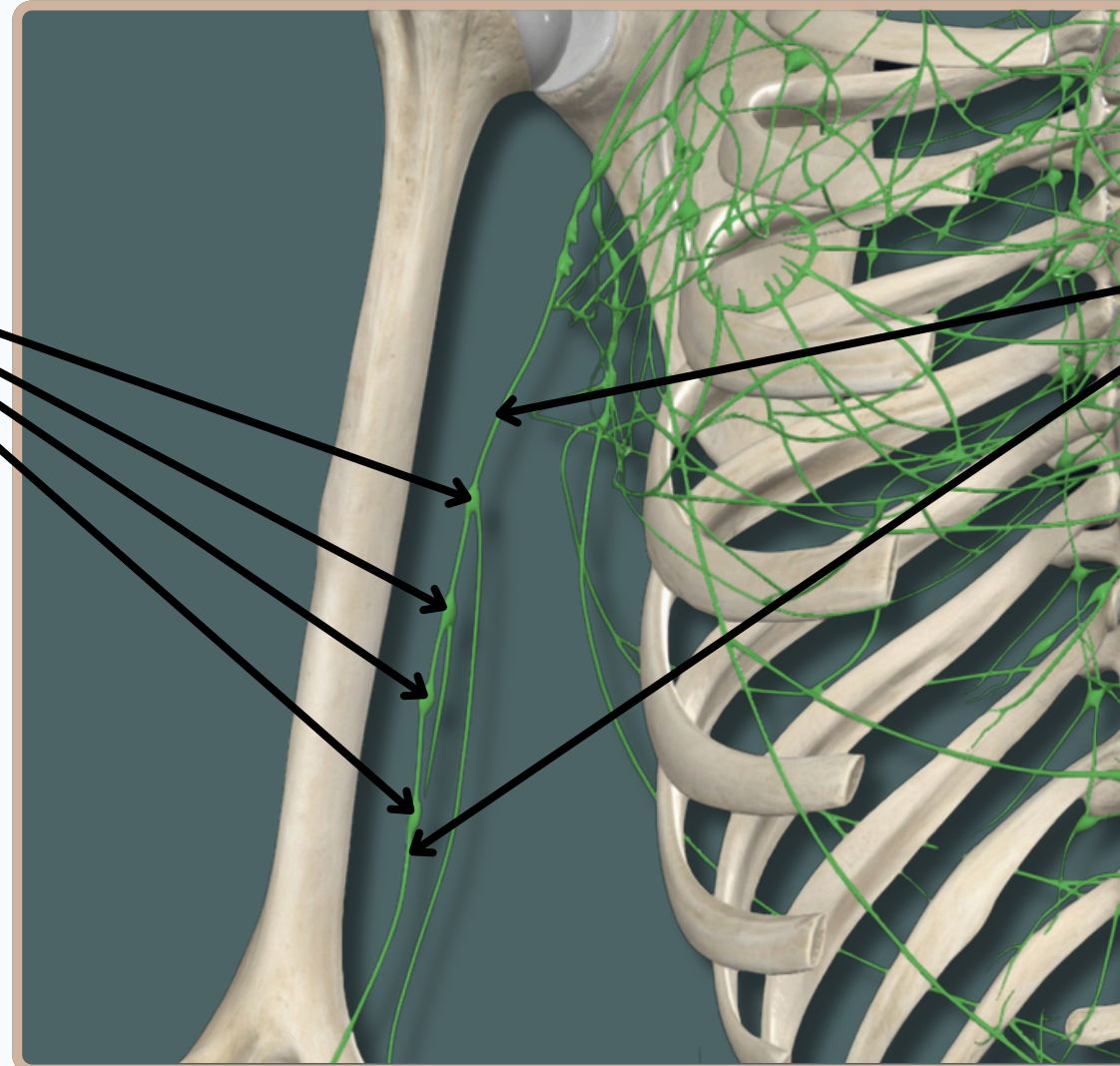
WWW.SATURNMEDIC.COM

LYMPHATIC SYSTEM



Brachial Lymph Nodes

Brachial Lymph Vessels



Anterior View

LYMPHATIC SYSTEM

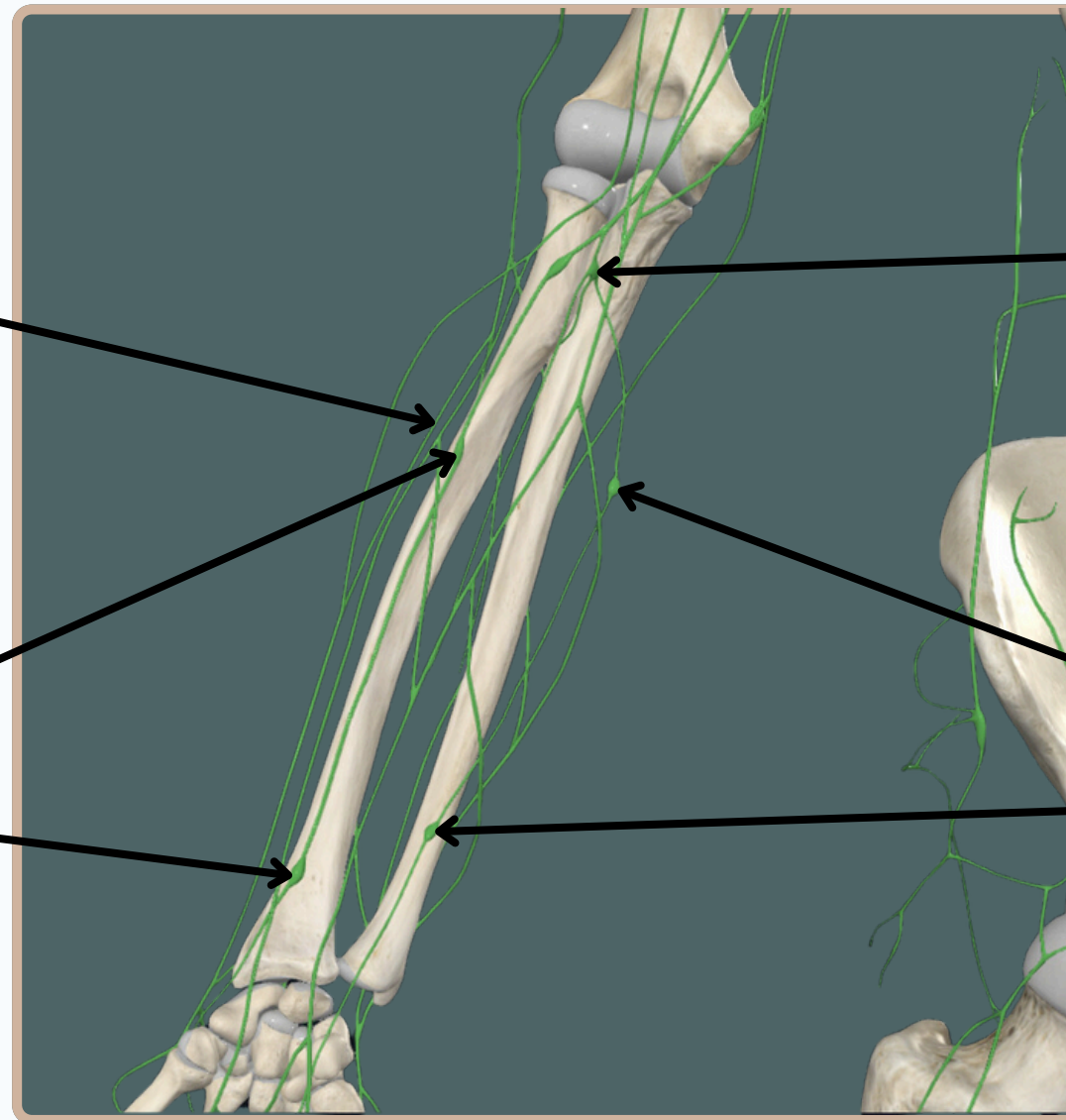


**Superficial Lymph
Vessels of Forearm**

Cubital Lymph Nodes

Radial Lymph Nodes

Ulnar Lymph Nodes



Anterior View

LYMPHATIC SYSTEM



Cubital Lymph Nodes

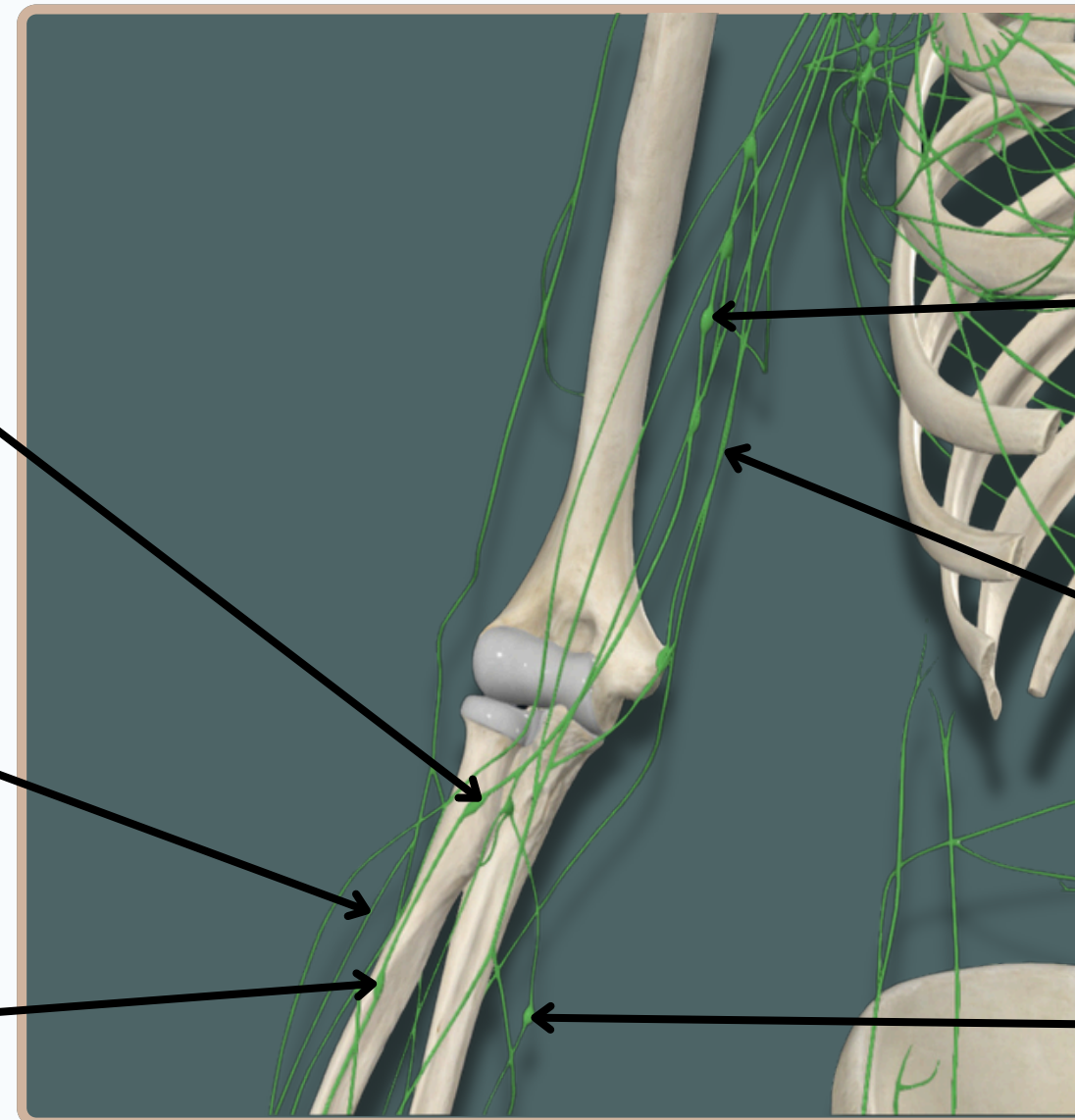
Superficial Lymph Vessels of Forearm

Radial Lymph Nodes

Brachial Lymph Vessels

Brachial Lymph Nodes

Ulnar Lymph Nodes



Anterior View

LYMPHATIC SYSTEM

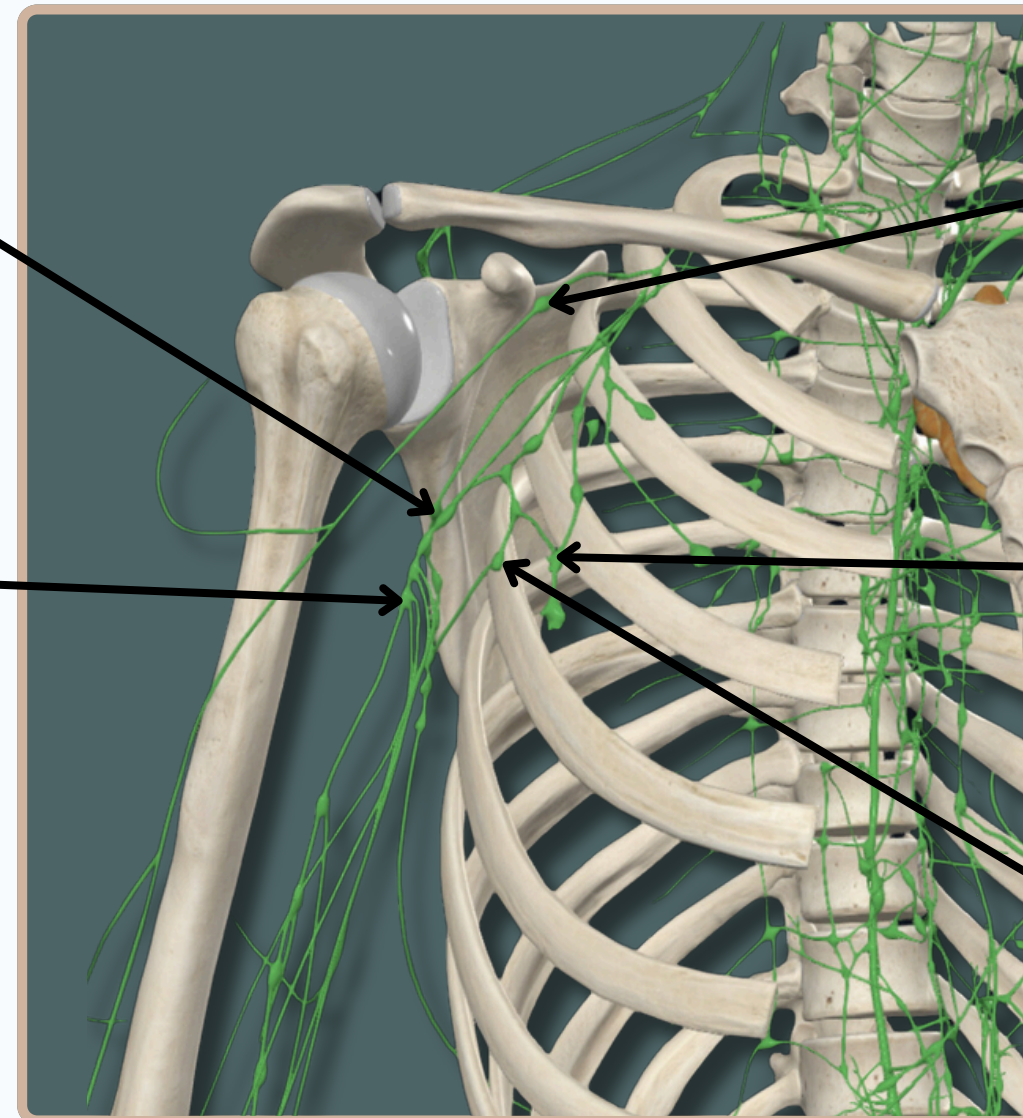


Posterior Axillary Nodes

Infraclavicular Nodes

Lateral Axillary Nodes

Anterior Axillary Nodes



Central Axillary Nodes

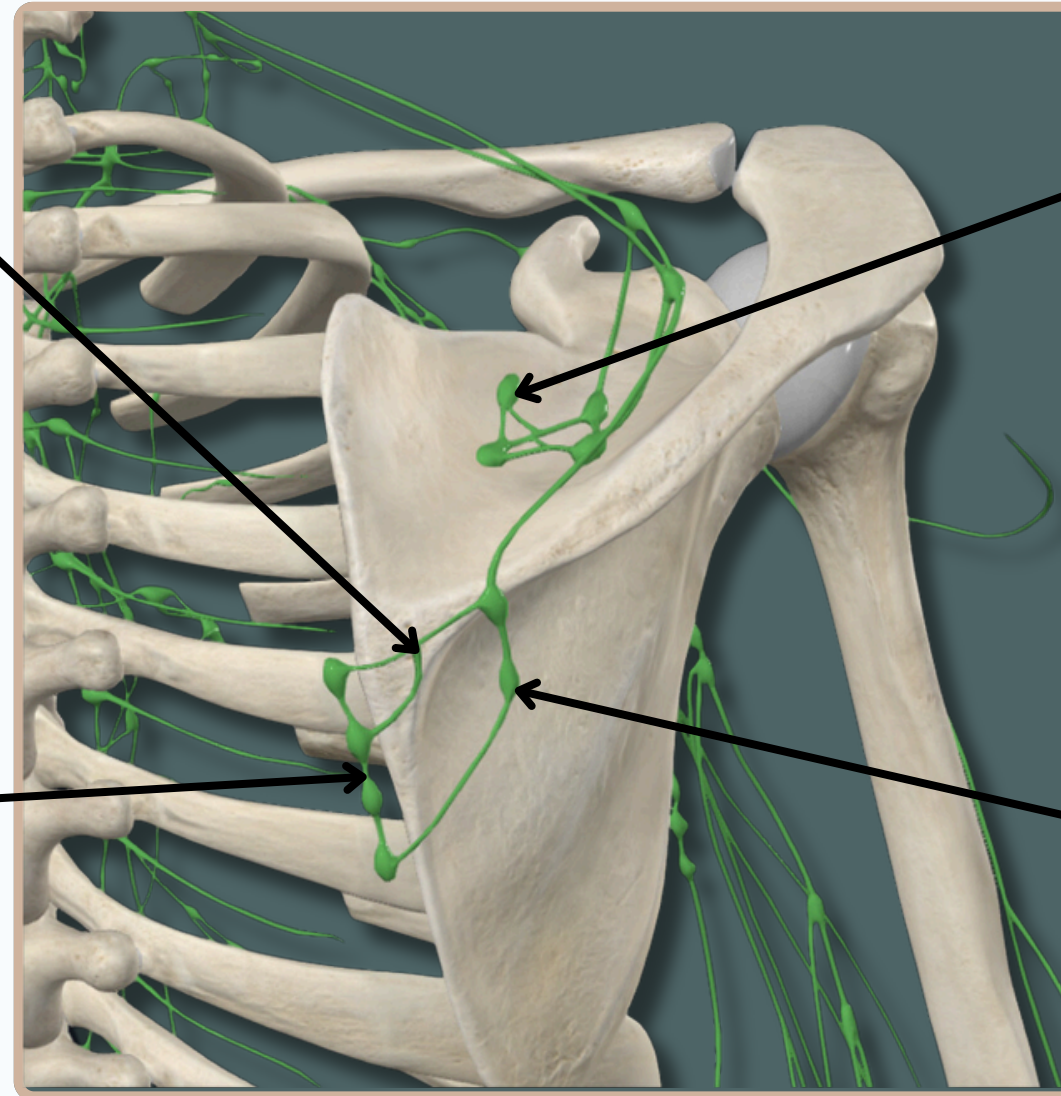
Anterior View

LYMPHATIC SYSTEM



Posterior Scapular Lymph Vessels

Deep Posterior Scapular Nodes



Posterior Scapular Nodes

Dorsal Subtrapezoid Nodes

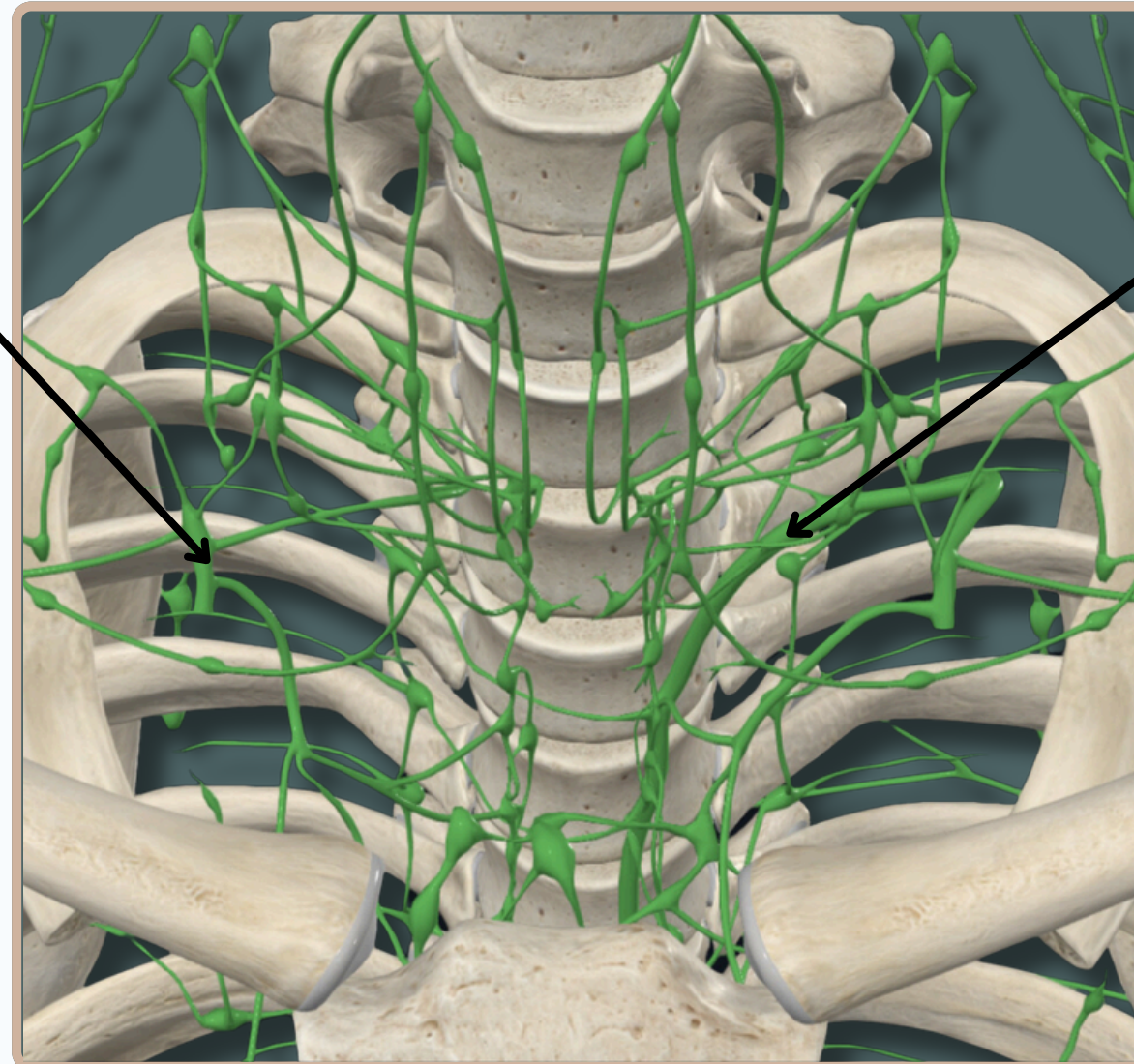
Anterior View

LYMPHATIC SYSTEM



Right Lymphatic Duct

Receives Lymph From The Right Side of The Head, Neck And Thorax And Right Upper Limb



Thoracic Duct

Receives From The Rest of The Body

Anterior View