

ANATOMY OF UPPER LIMB

PRACTICAL LECTURE - 10 -

MUSCLES / PART 5

MUSCLES OF THE ANTERIOR COMPARTMENT OF FOREARM

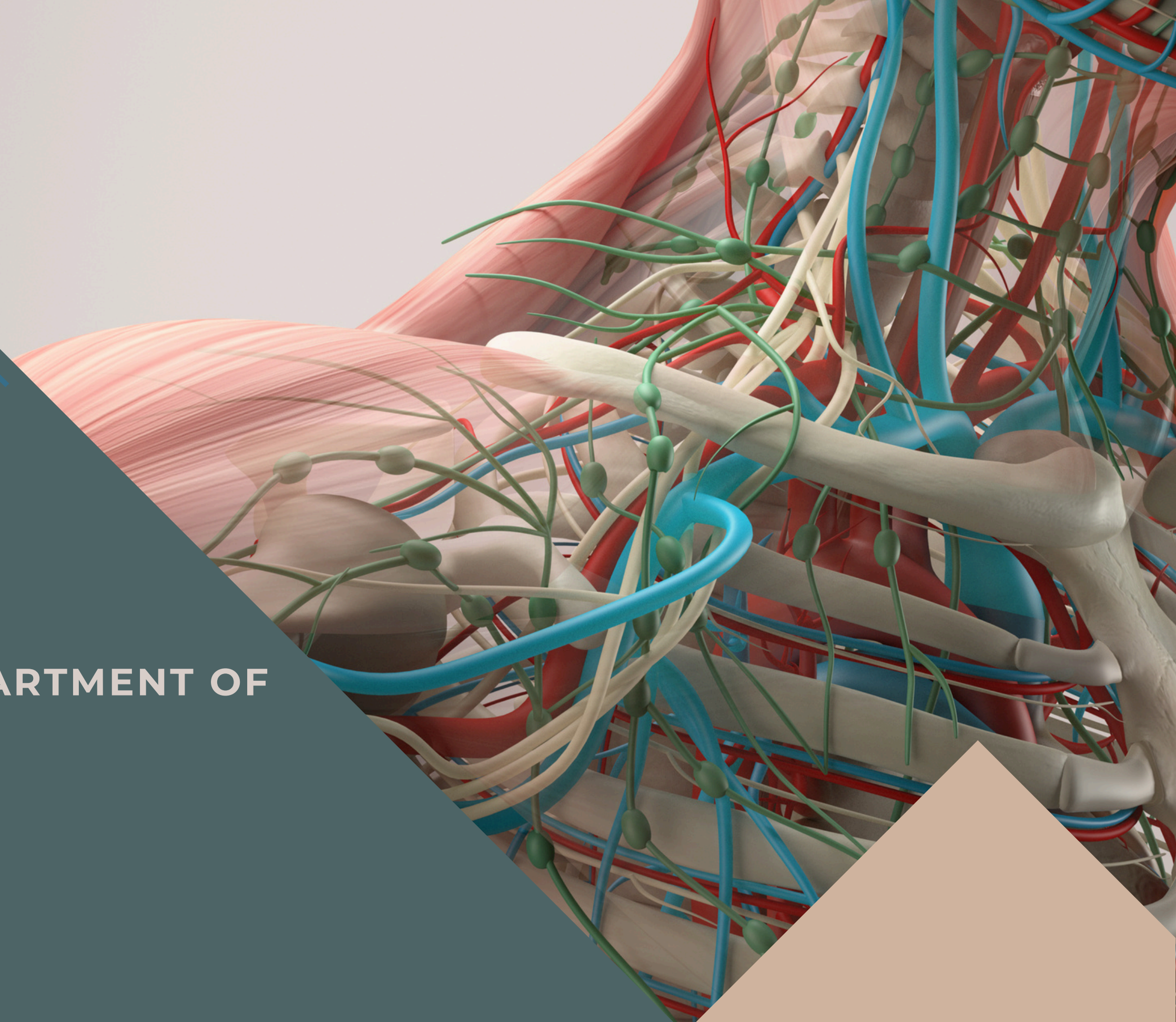
EDITED BY



SATURN
MEDIC



ARECH

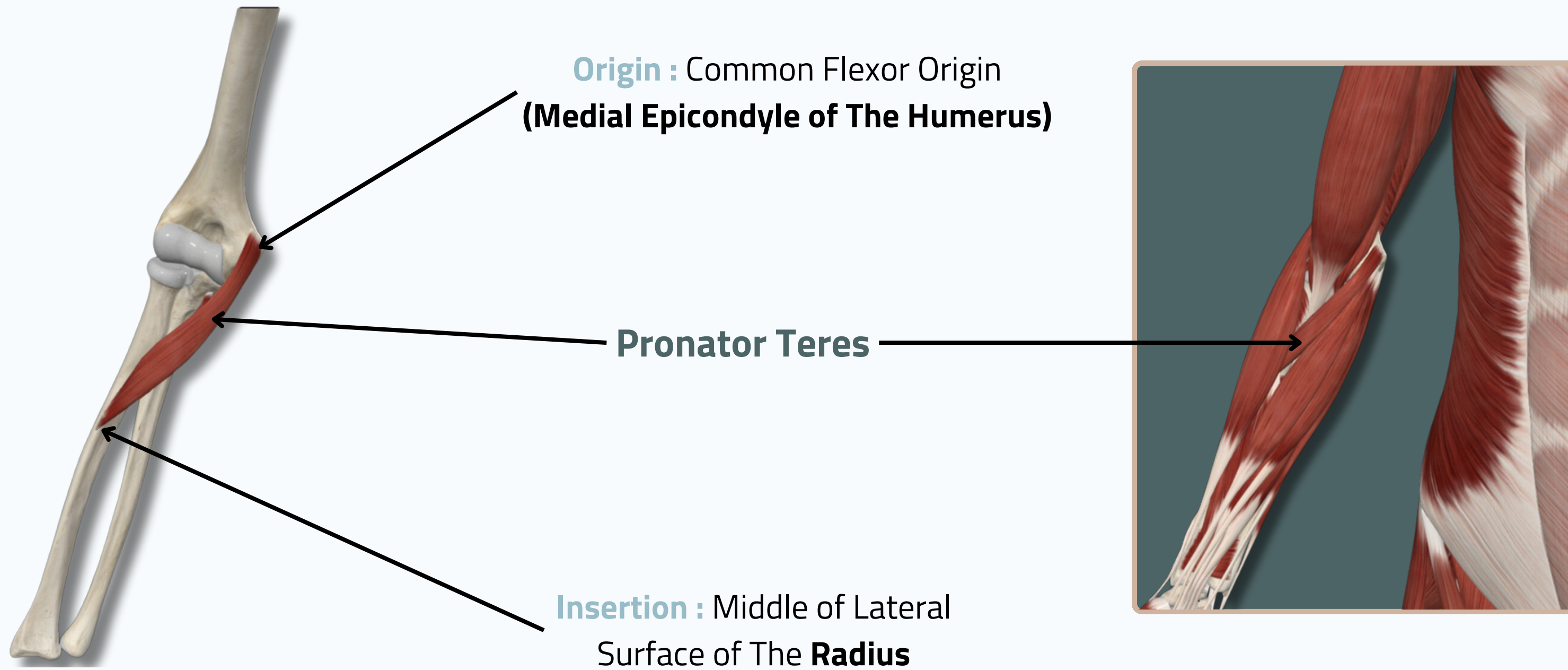


ALL COPYRIGHT ARE RESERVED FOR
SATURN MEDIC AND ARECH

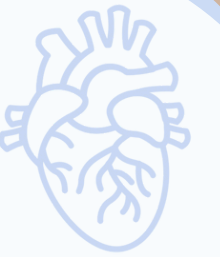WWW.SATURNMEDIC.COM



PRONATOR TERES



Anterior View

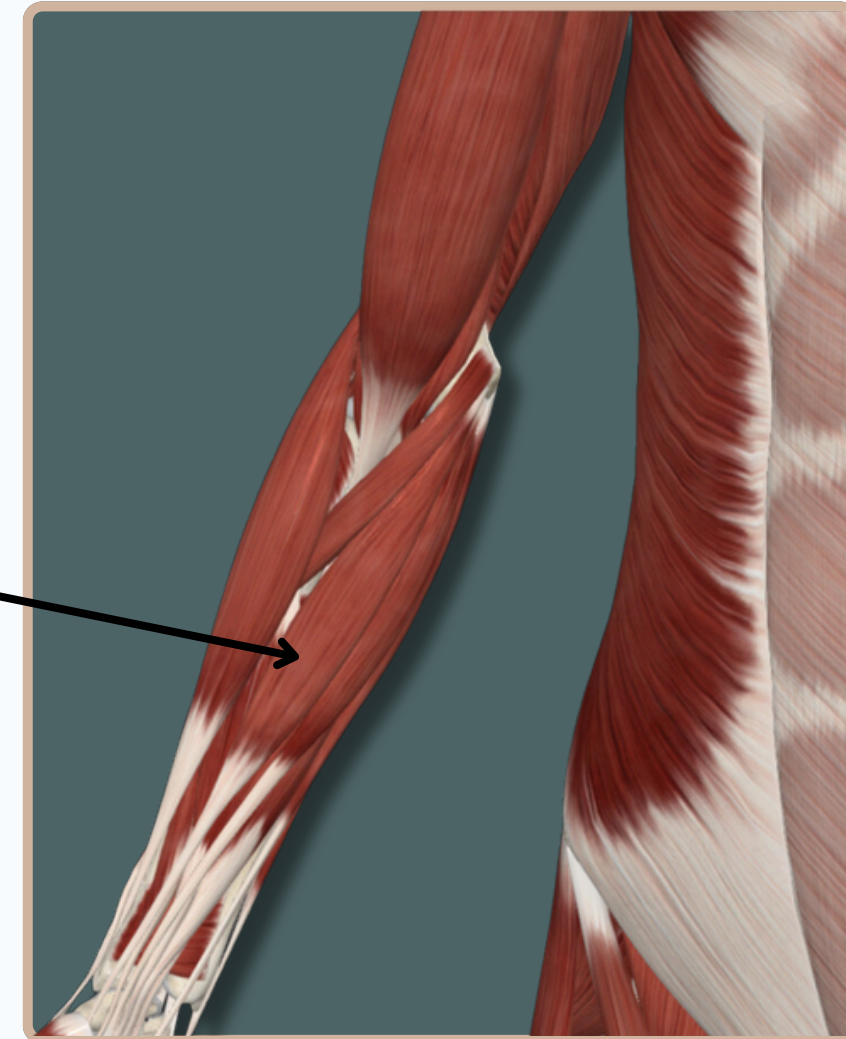
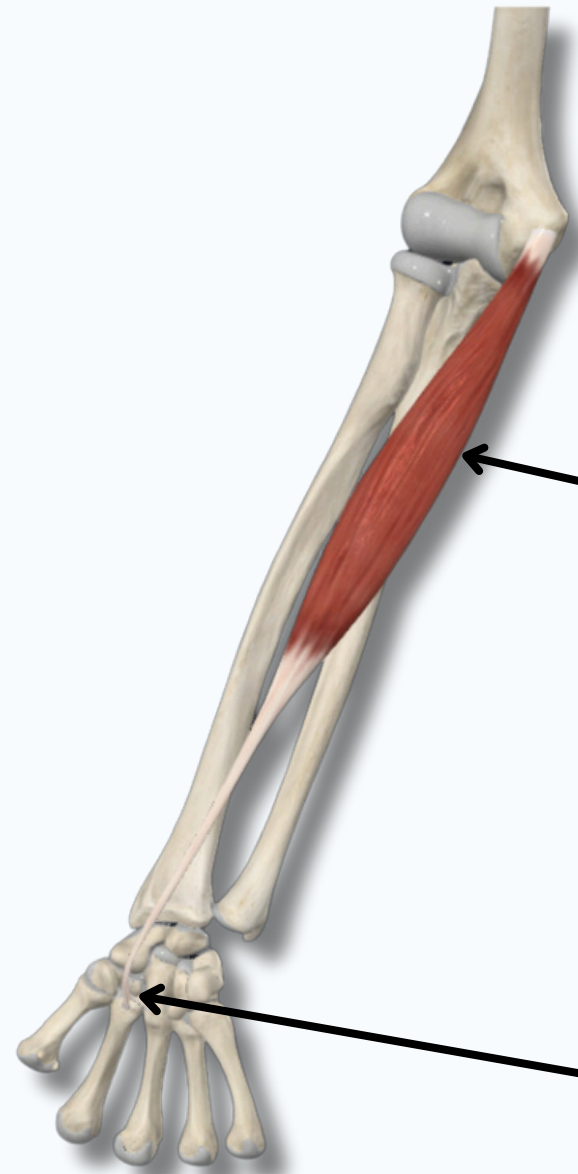


FLEXOR CARPI RADIALIS

Origin : Common Flexor Origin
(Medial Epicondyle of The Humerus)

Flexor Carpi Radialis

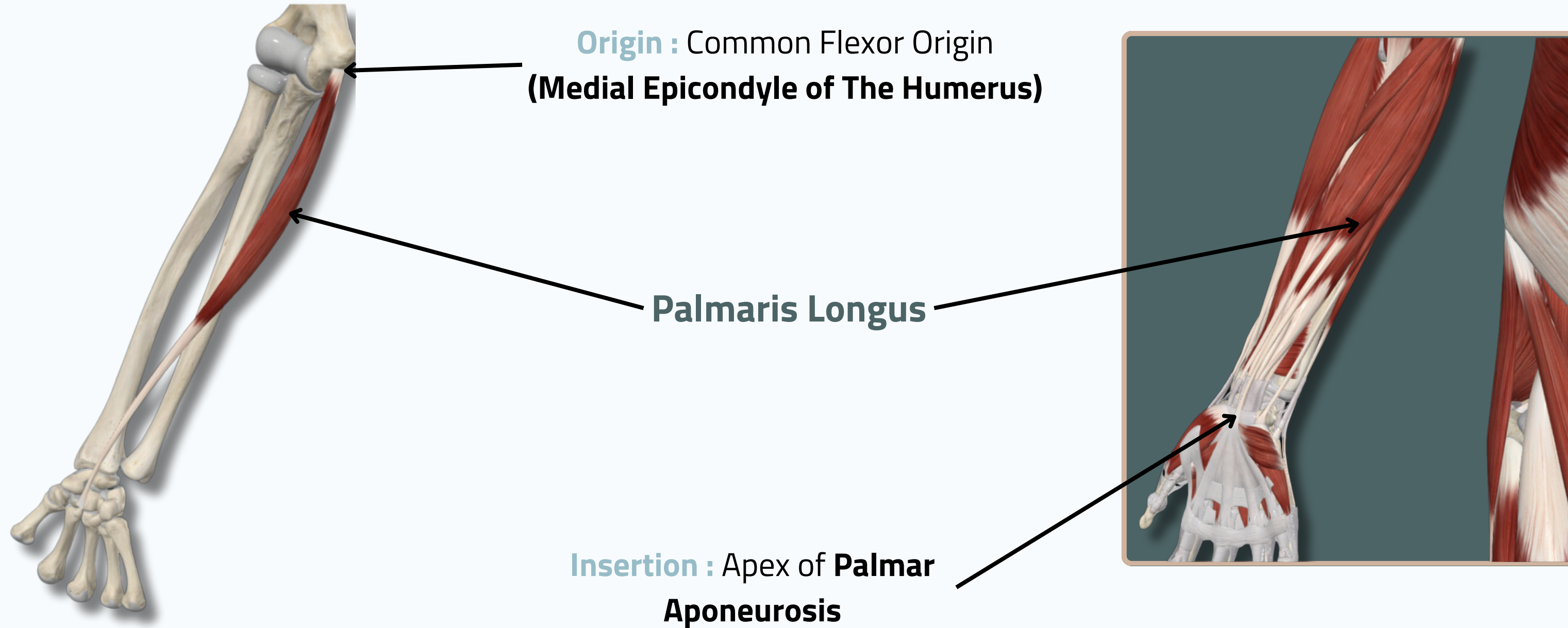
Insertion : Base of Second
And Third **Metacarpel Bones**



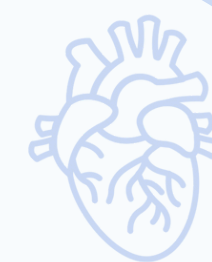Anterior View



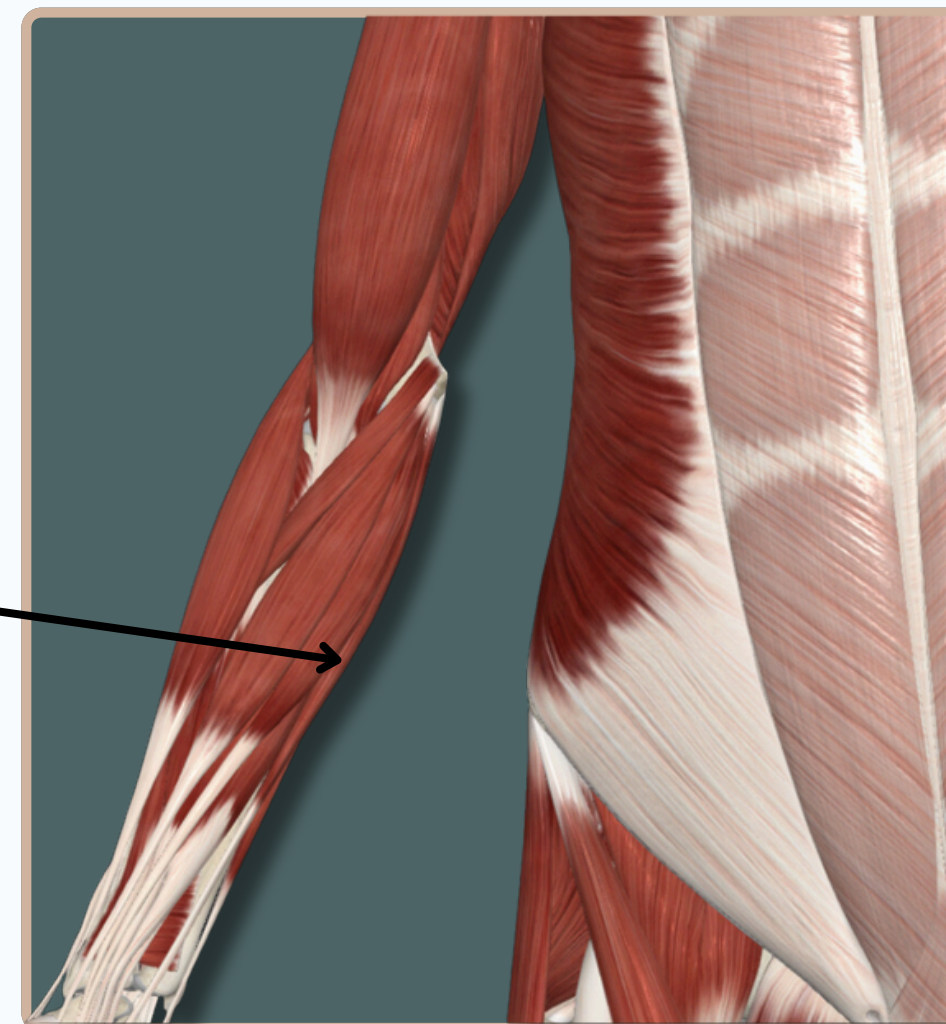
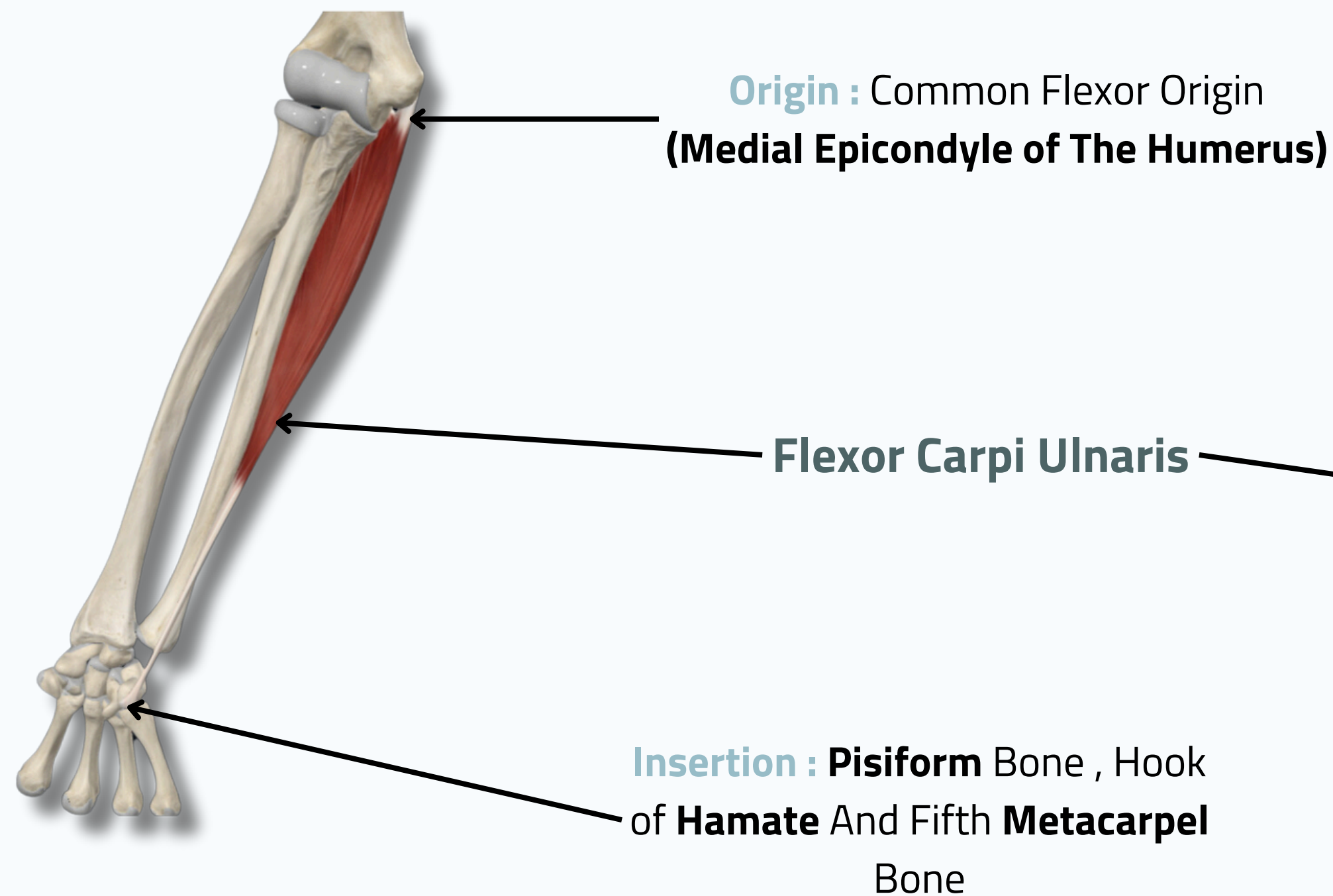
PALMARIS LONGUS



Anterior View



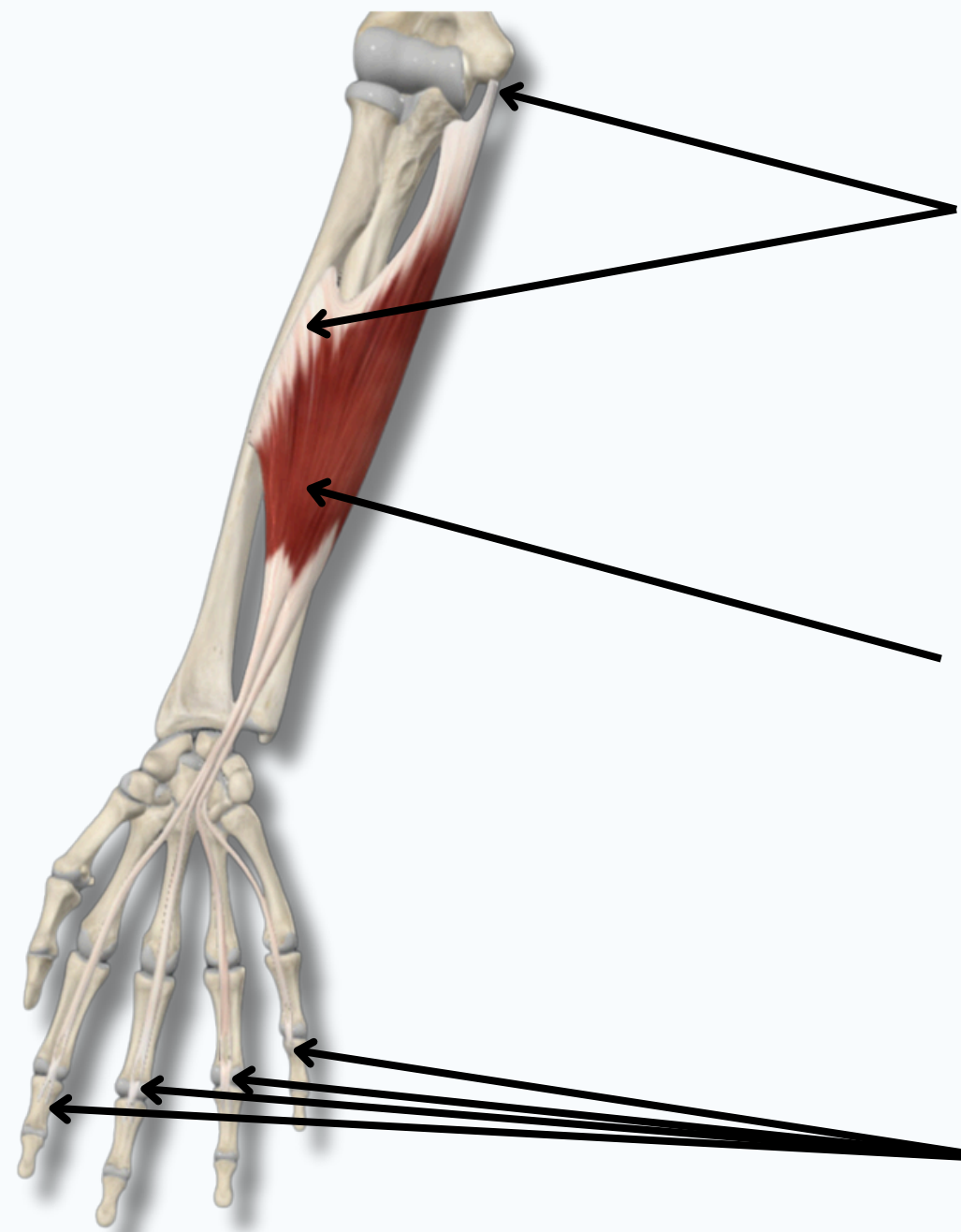
FLEXOR CARPI ULNARIS



Anterior View

MUSCLES OF THE ANTERIOR COMPARTMENT OF FOREARM

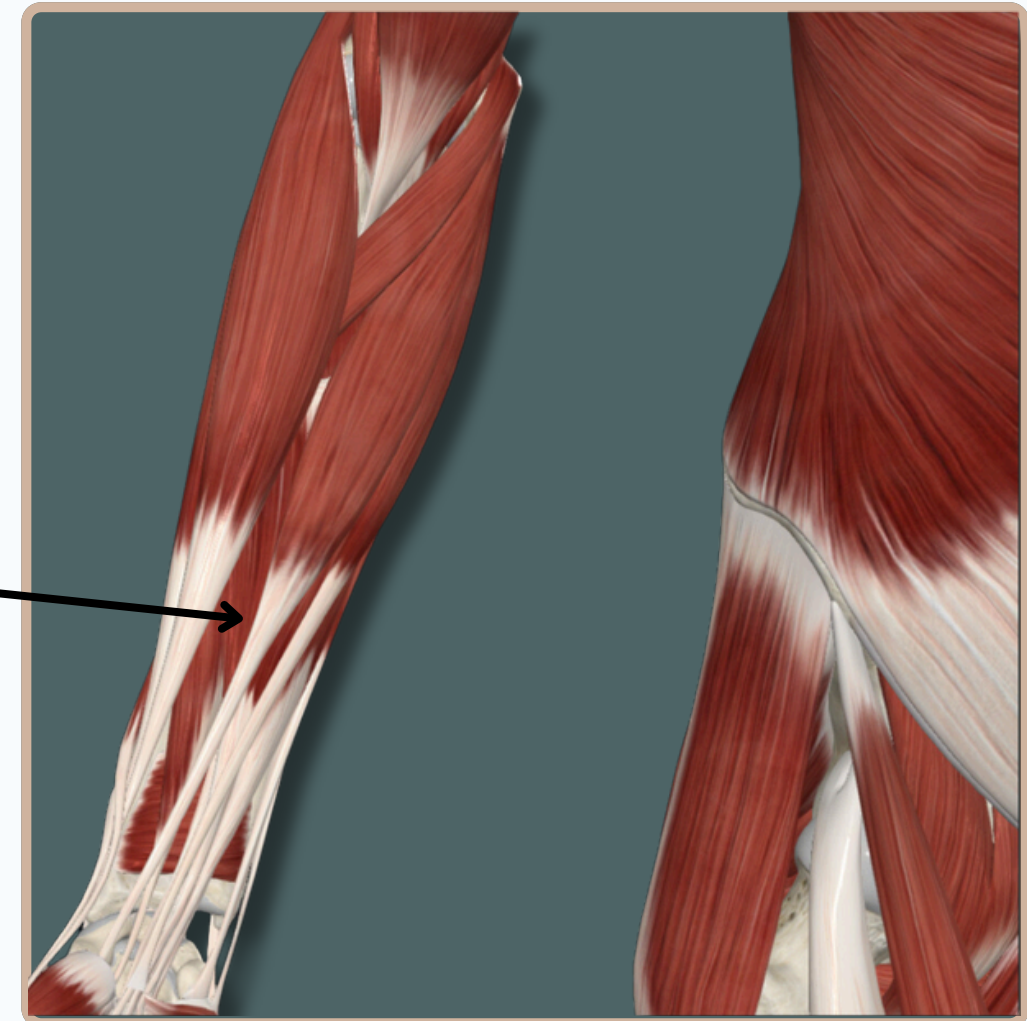
FLEXOR DIGITORUM SUPERFICIALIS



Origin : Common Flexor Origin And The Oblique Line of Anterior Surface of The **Radius**

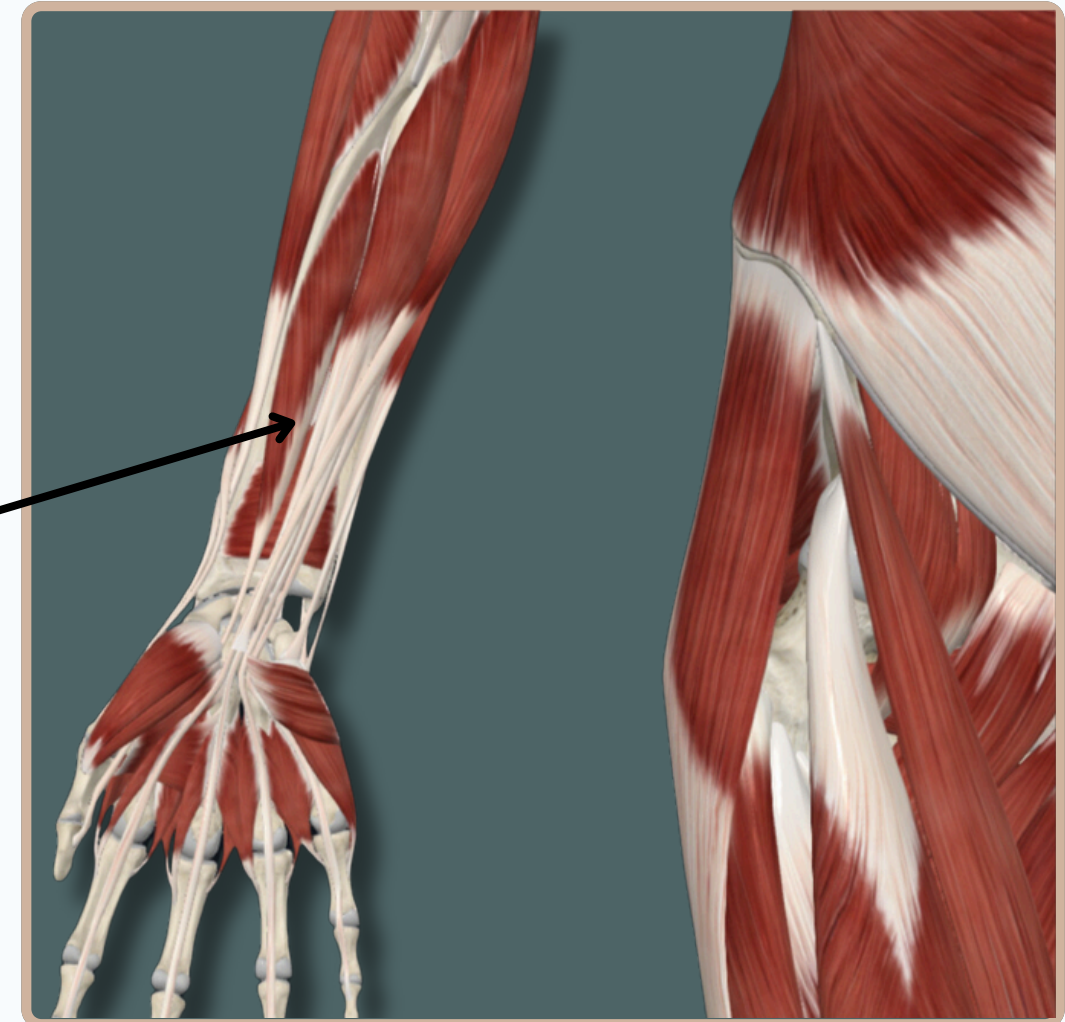
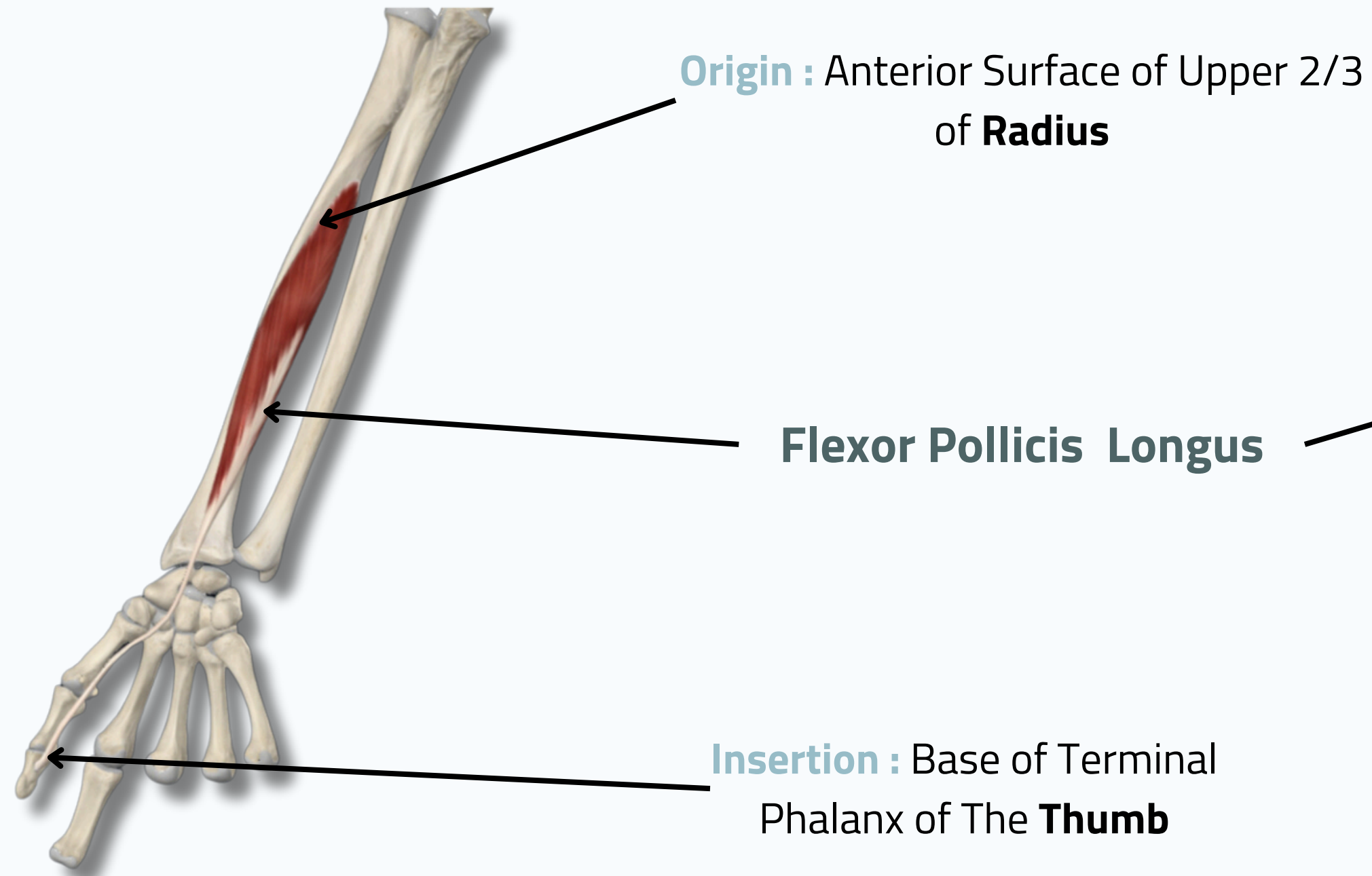
Flexor Digitorum Superficialis

Insertion : Base of Middle Phalanges of **Medial Four** **Fingers**



Anterior View

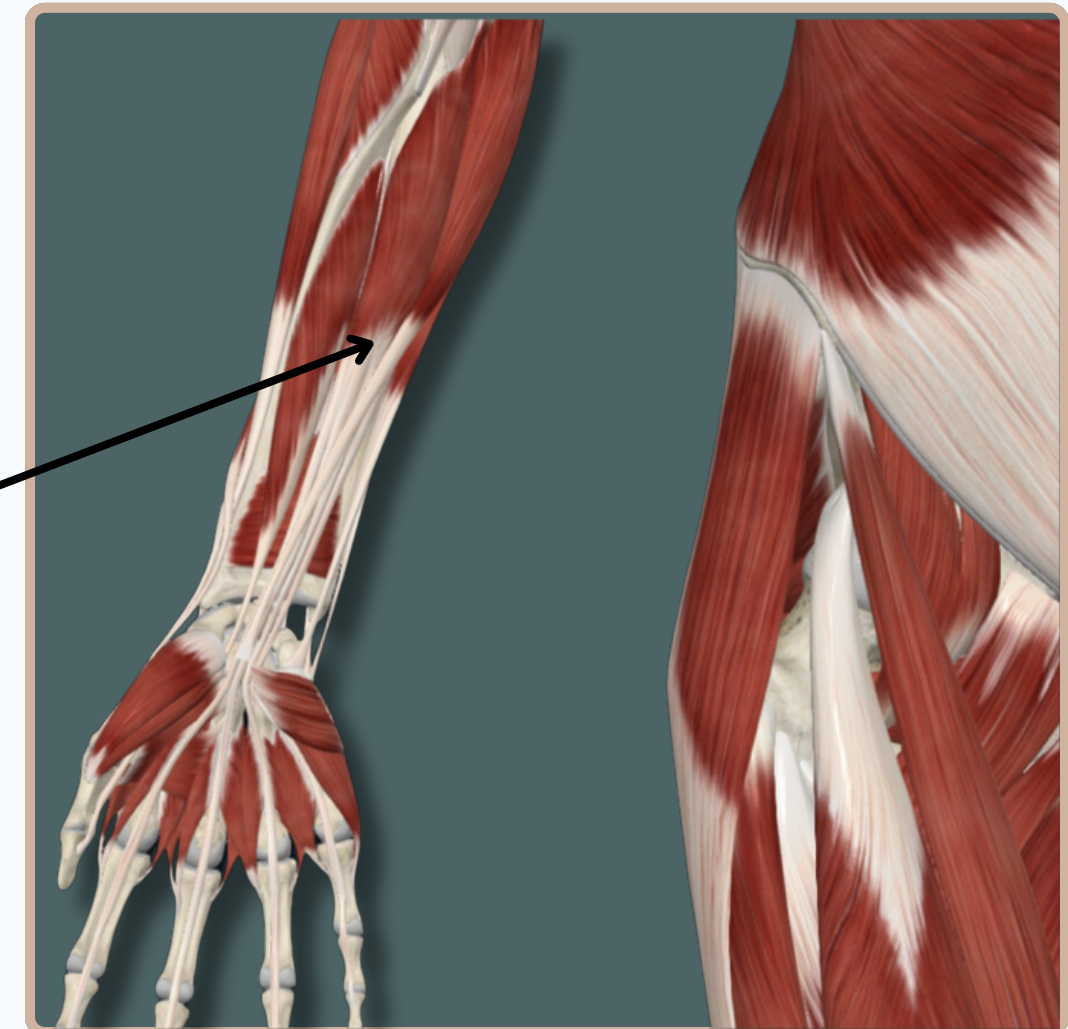
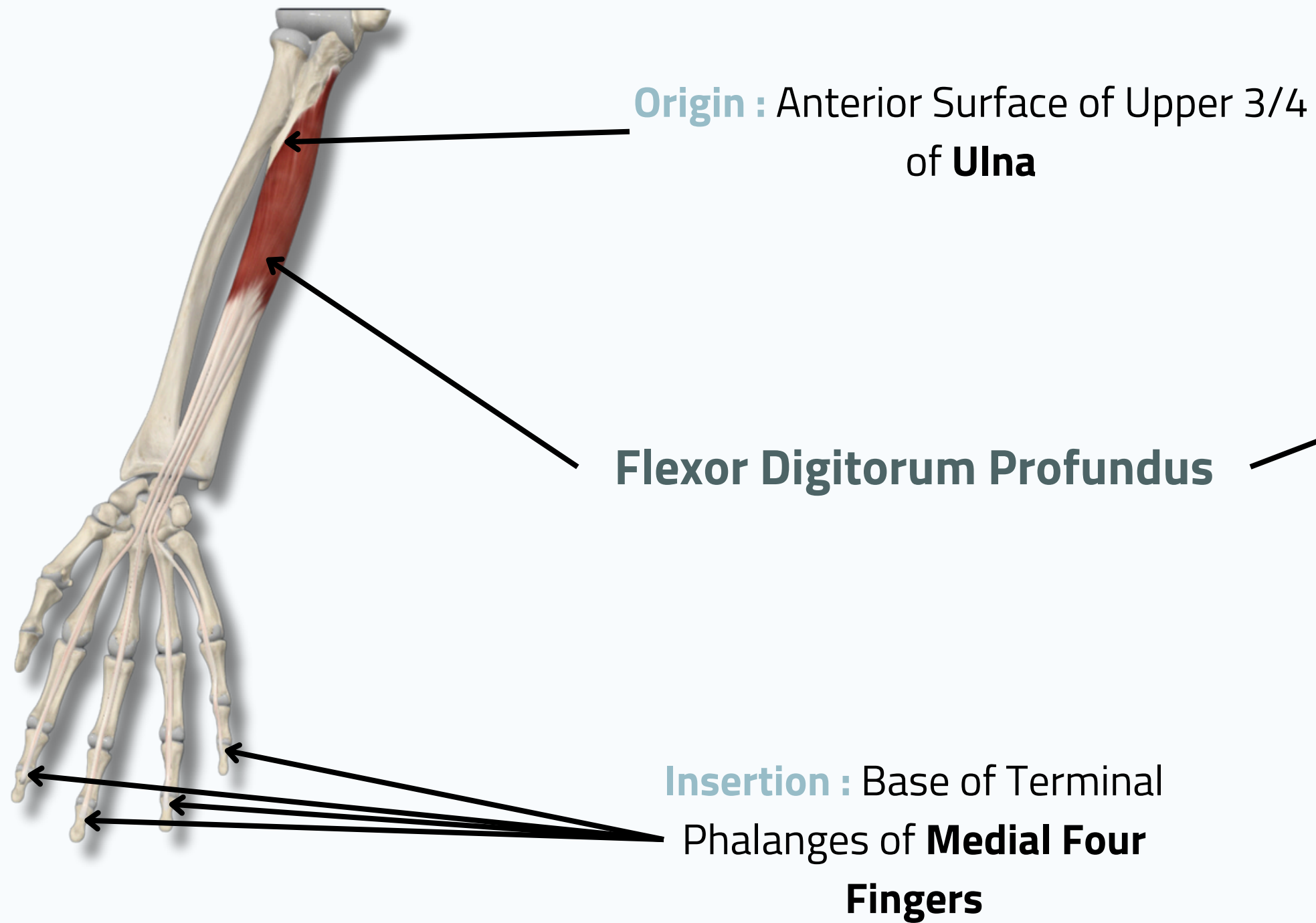
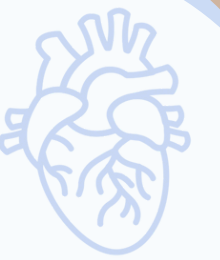FLEXOR POLLICIS LONGUS



Anterior View

MUSCLES OF THE ANTERIOR COMPARTMENT OF FOREARM

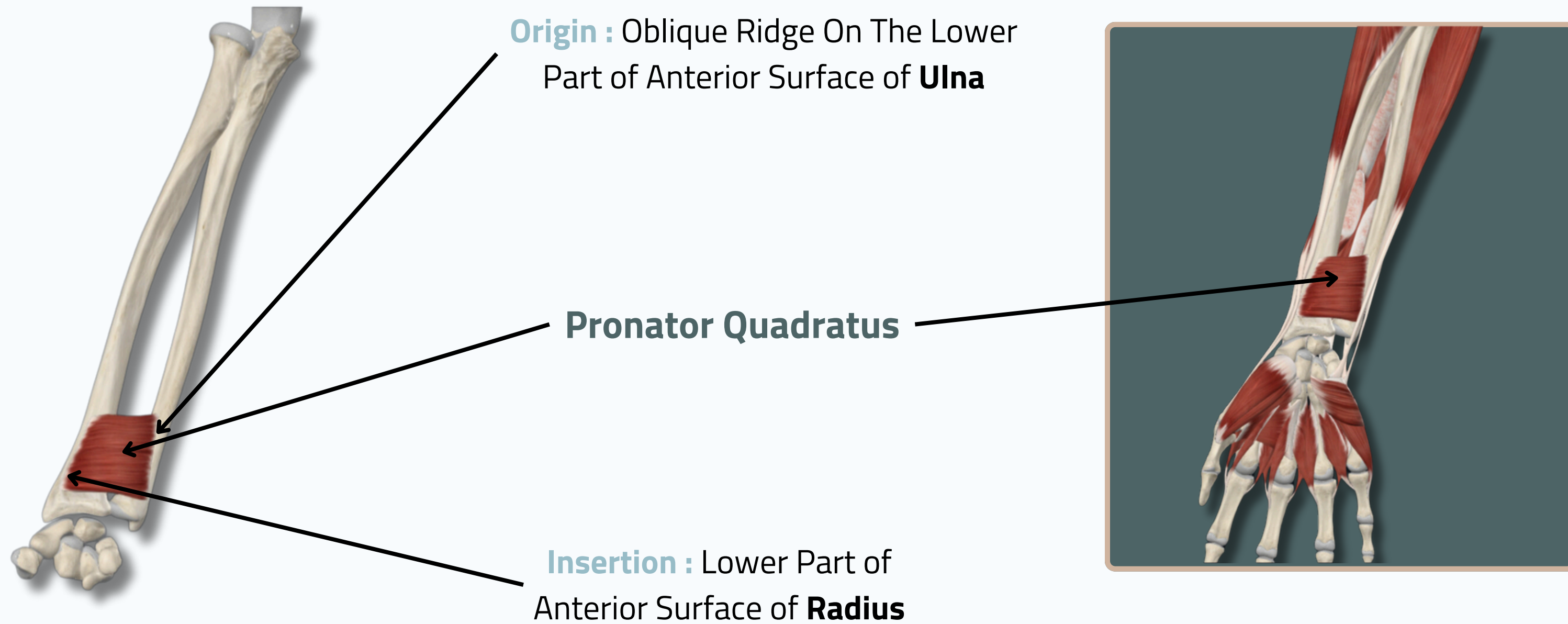
FLEXOR DIGITORUM PROFUNDUS



Anterior View



PRONATOR QUADRATUS



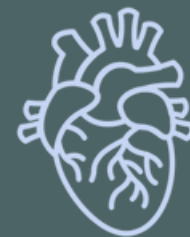Anterior View

THANK YOU

EDITED BY



SATURN
MEDIC



ARECH

© ALL COPYRIGHT ARE RESERVED FOR
SATURN MEDIC AND ARECH

WWW.SATURNMEDIC.COM