

ANATOMY OF UPPER LIMB

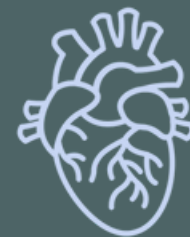PRACTICAL LECTURE - 11 - MUSCLES / PART 6

EXTENSOR MUSCLES OF THE FOREARM

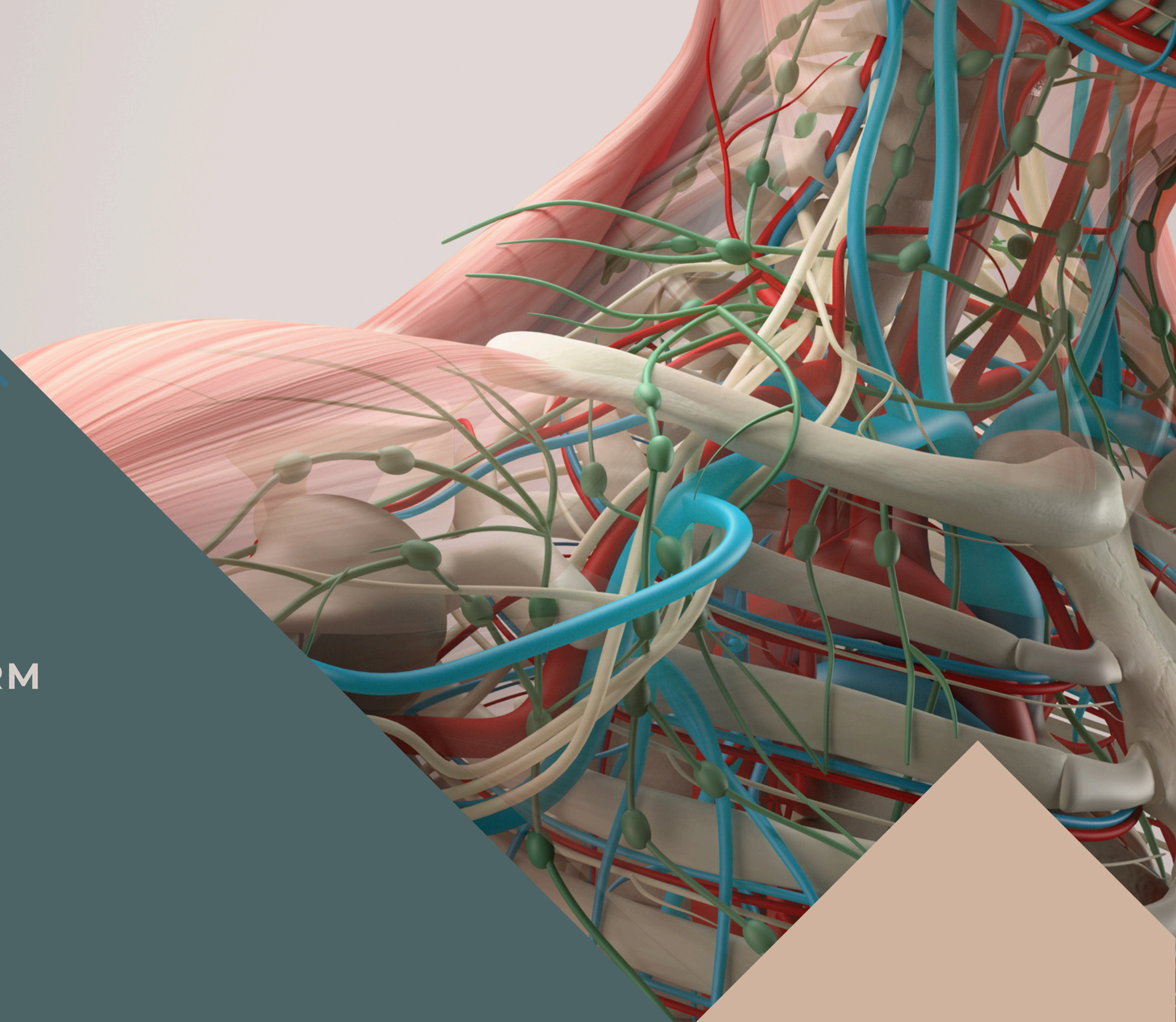
EDITED BY



SATURN
MEDIC



ARECH

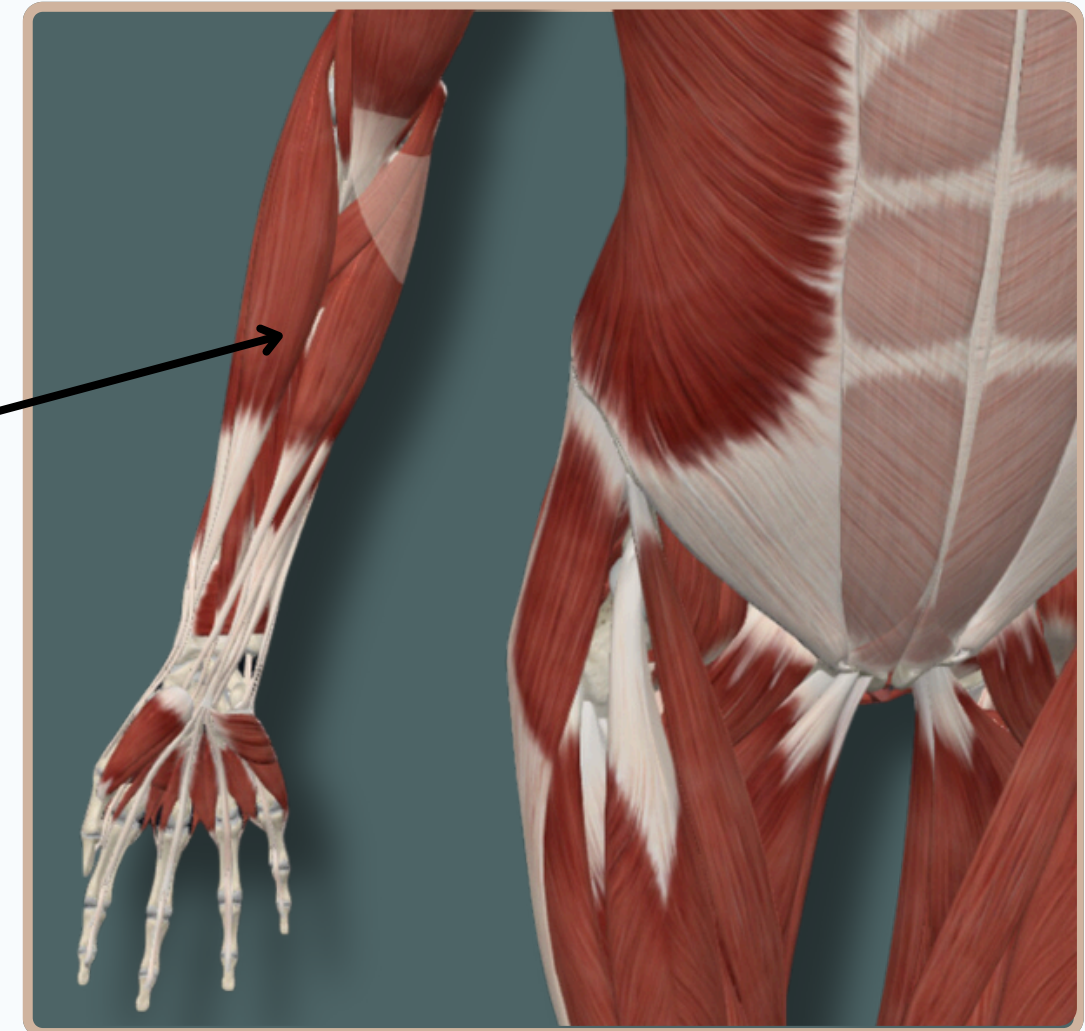
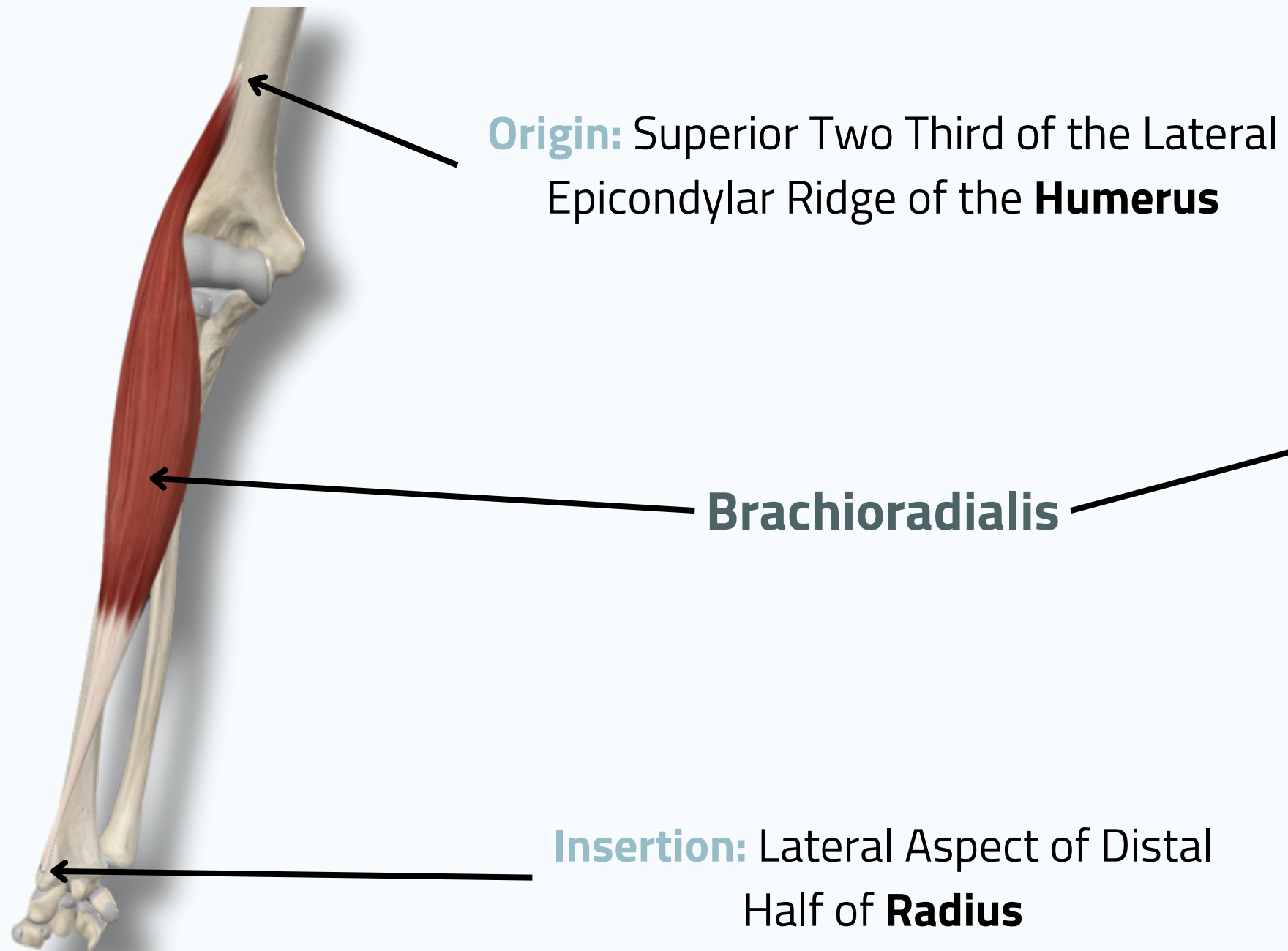


ALL COPYRIGHT ARE RESERVED FOR
SATURN MEDIC AND ARECH

WWW.SATURNMEDIC.COM

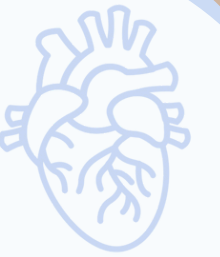EXTENSOR MUSCLES OF THE FOREARM

BRACHIORADIALIS





EXTENSOR MUSCLES OF THE FOREARM

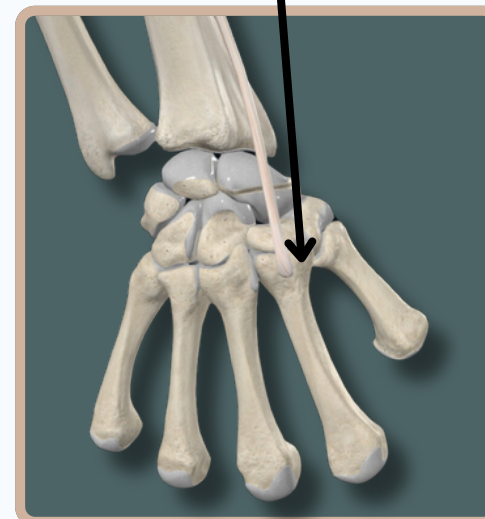
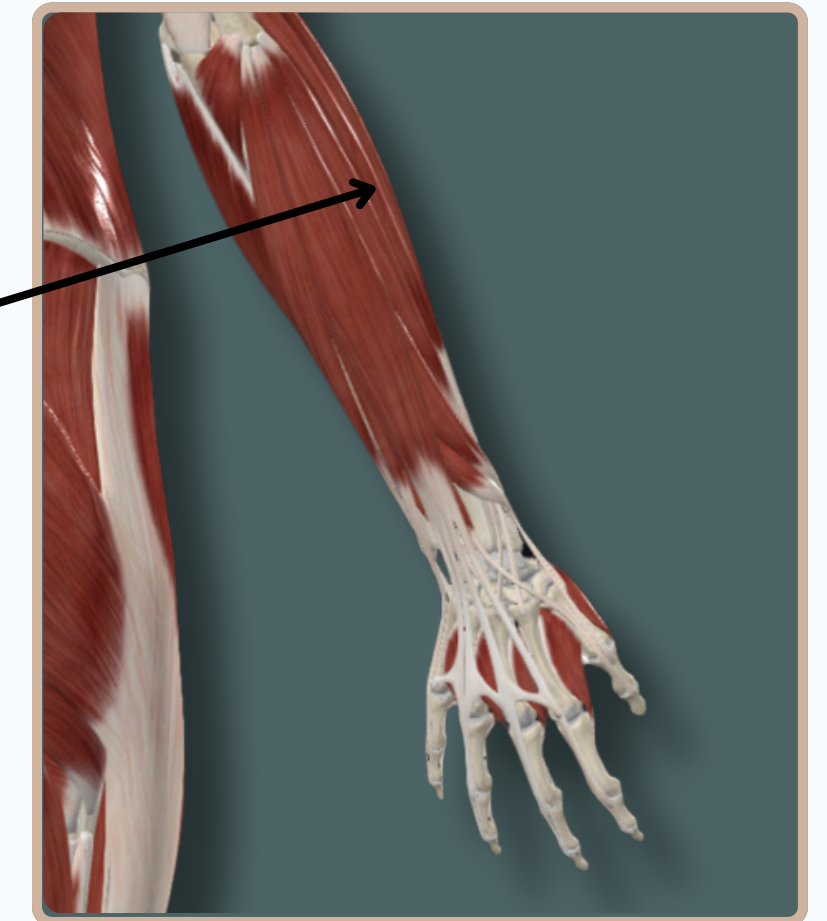
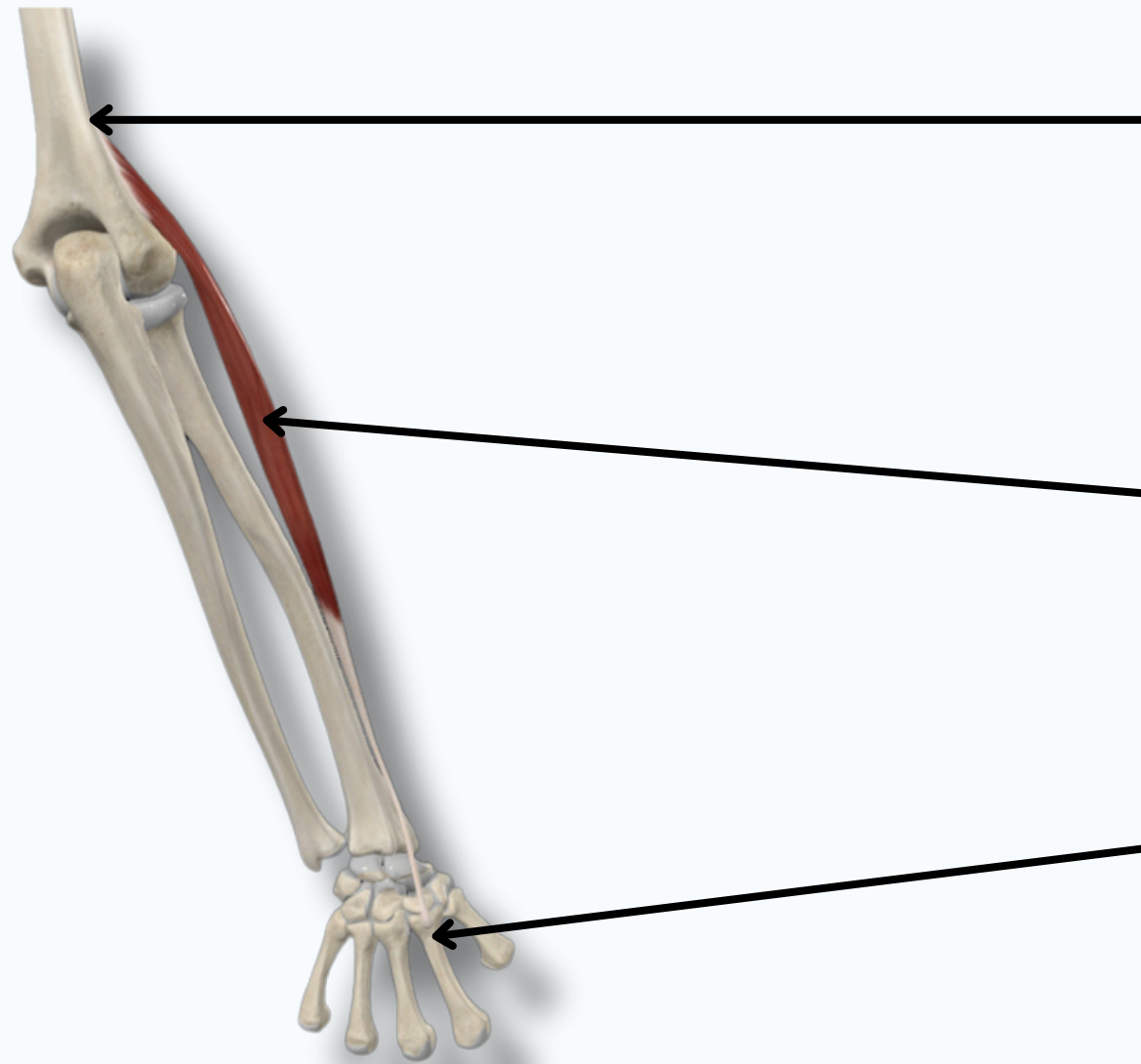


EXTENSOR CARPI RADIALIS LONGUS

Origin: Inferior One Third Lateral Supracondylar Ridge of **Humerus**

Extensor Carpi Radialis Longus

Insertion: Dorsal Aspect of the Base of **2nd Metacarpal Bone**



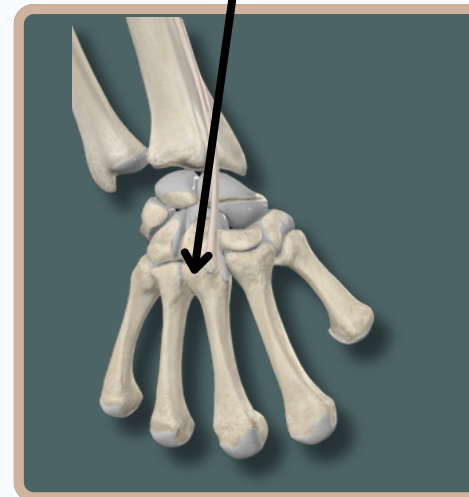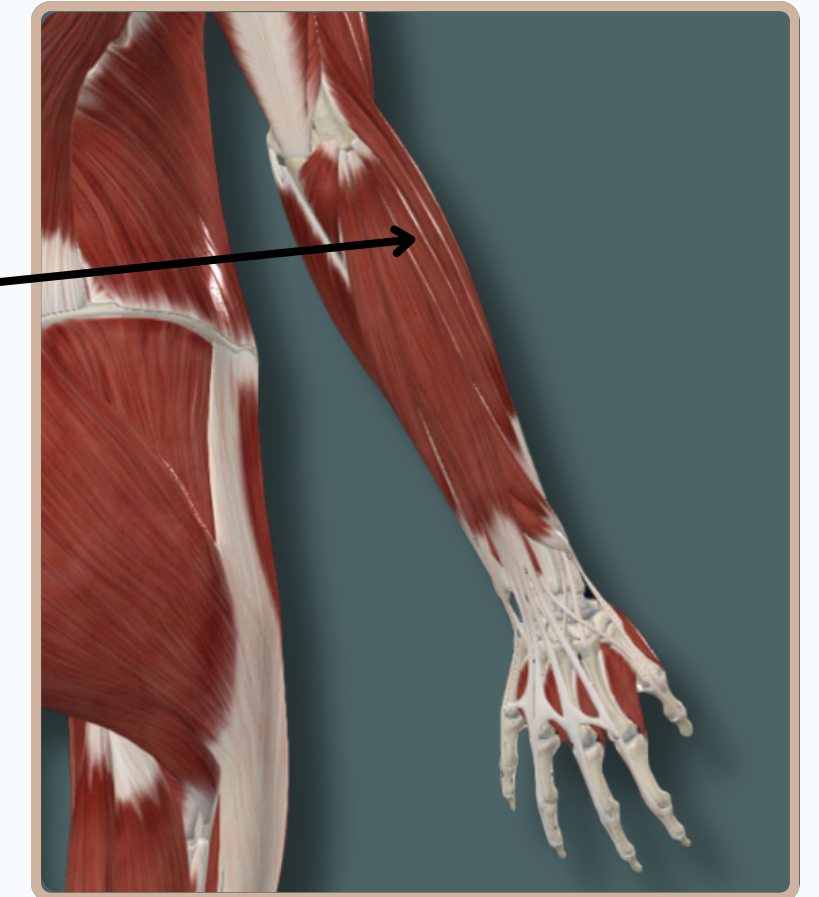
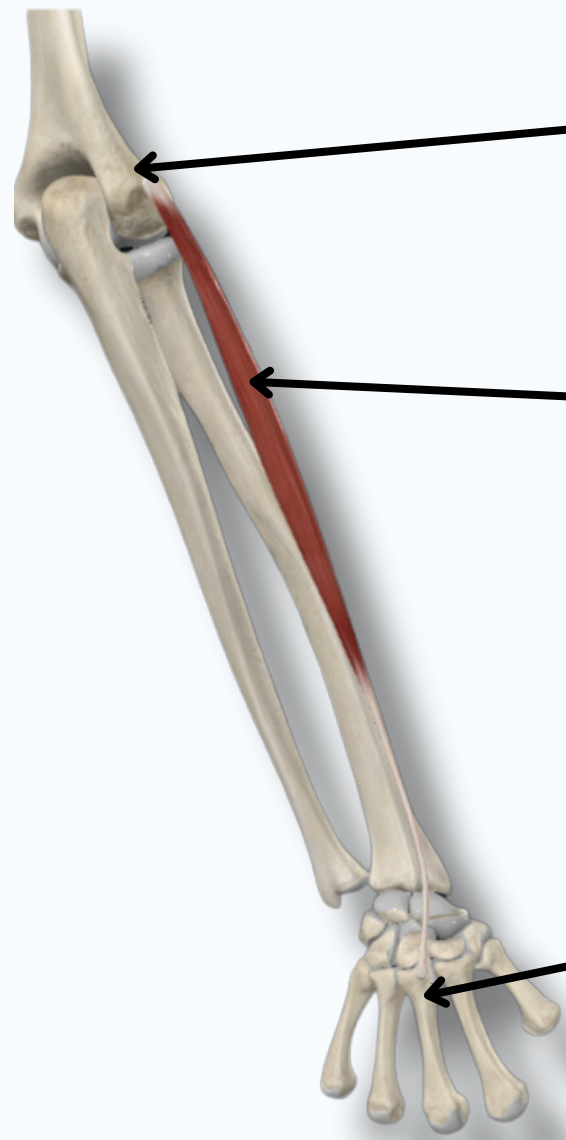
EXTENSOR MUSCLES OF THE FOREARM

EXTENSOR CARPI RADIALIS BREVIS

Origin: Lateral Epicondyle of the **Humerus**
Via Common Extensor Tendon

Extensor Carpi Radialis Brevis

Insertion: Dorsal Aspect of the
Base of **3rd Metacarpal Bone**



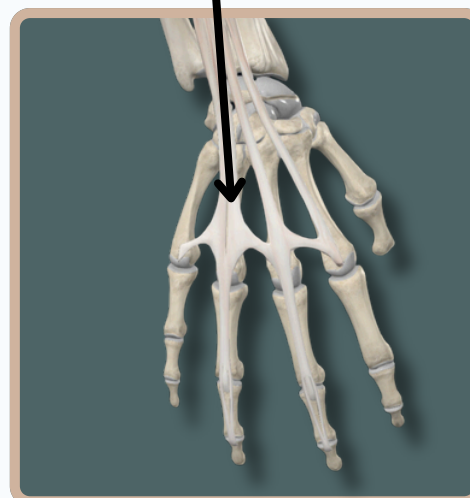
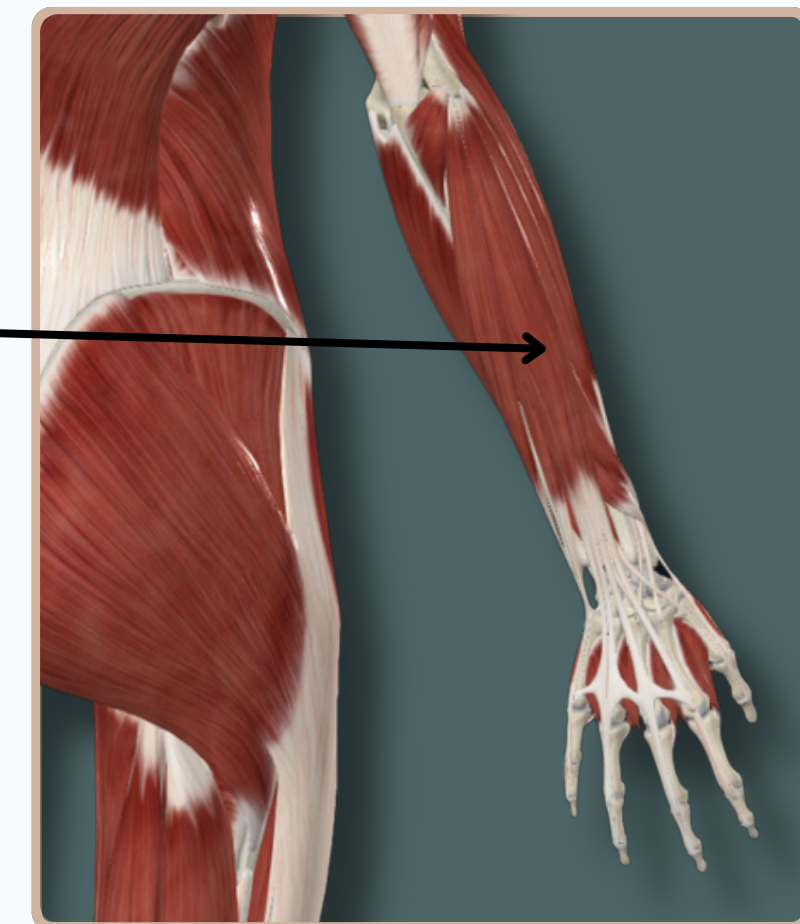
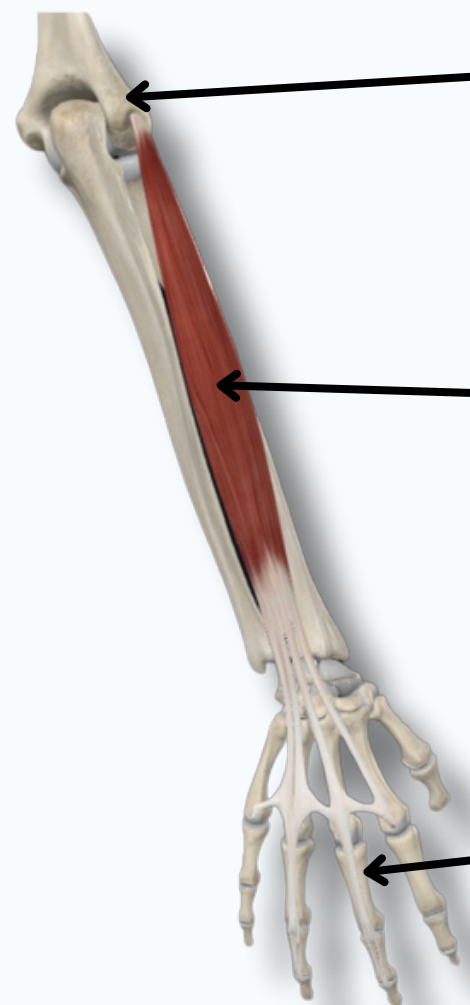
EXTENSOR MUSCLES OF THE FOREARM

EXTENSOR DIGITORUM

Origin: Lateral Epicondyle of the **Humerus**
Via Common Extensor Tendon

Extensor Digitorum

Insertion: Extensor Expansion of
the **Medial Four Finger**



EXTENSOR MUSCLES OF THE FOREARM

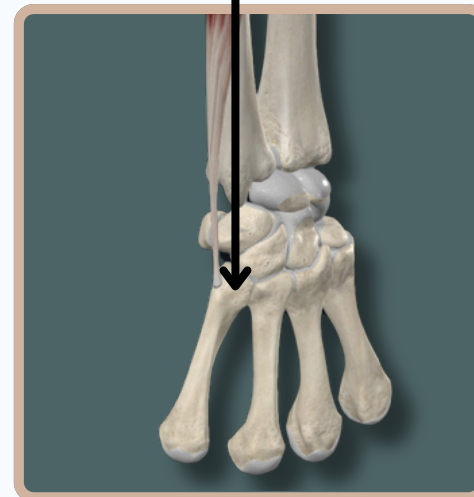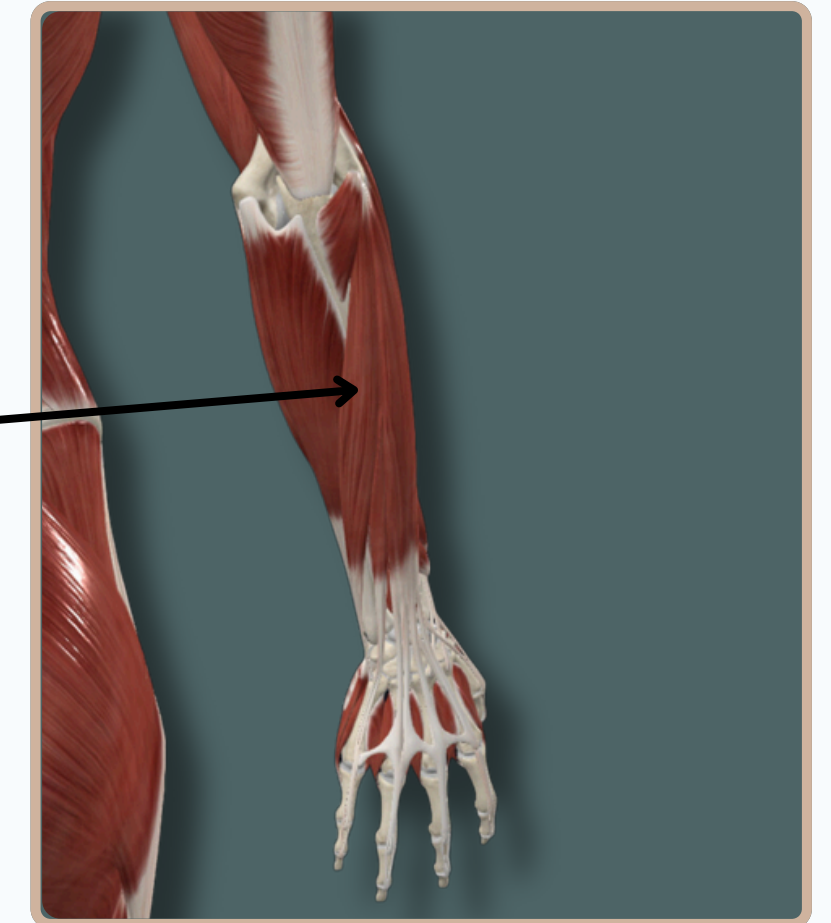

EXTENSOR CARPI ULNARIS

Origin: Lateral Epicondyle of the **Humerus**
Via Common Extensor Tendon

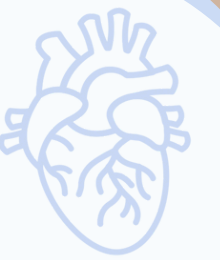Origin: Posterior Border of **Ulna**

Extensor Carpi Ulnaris

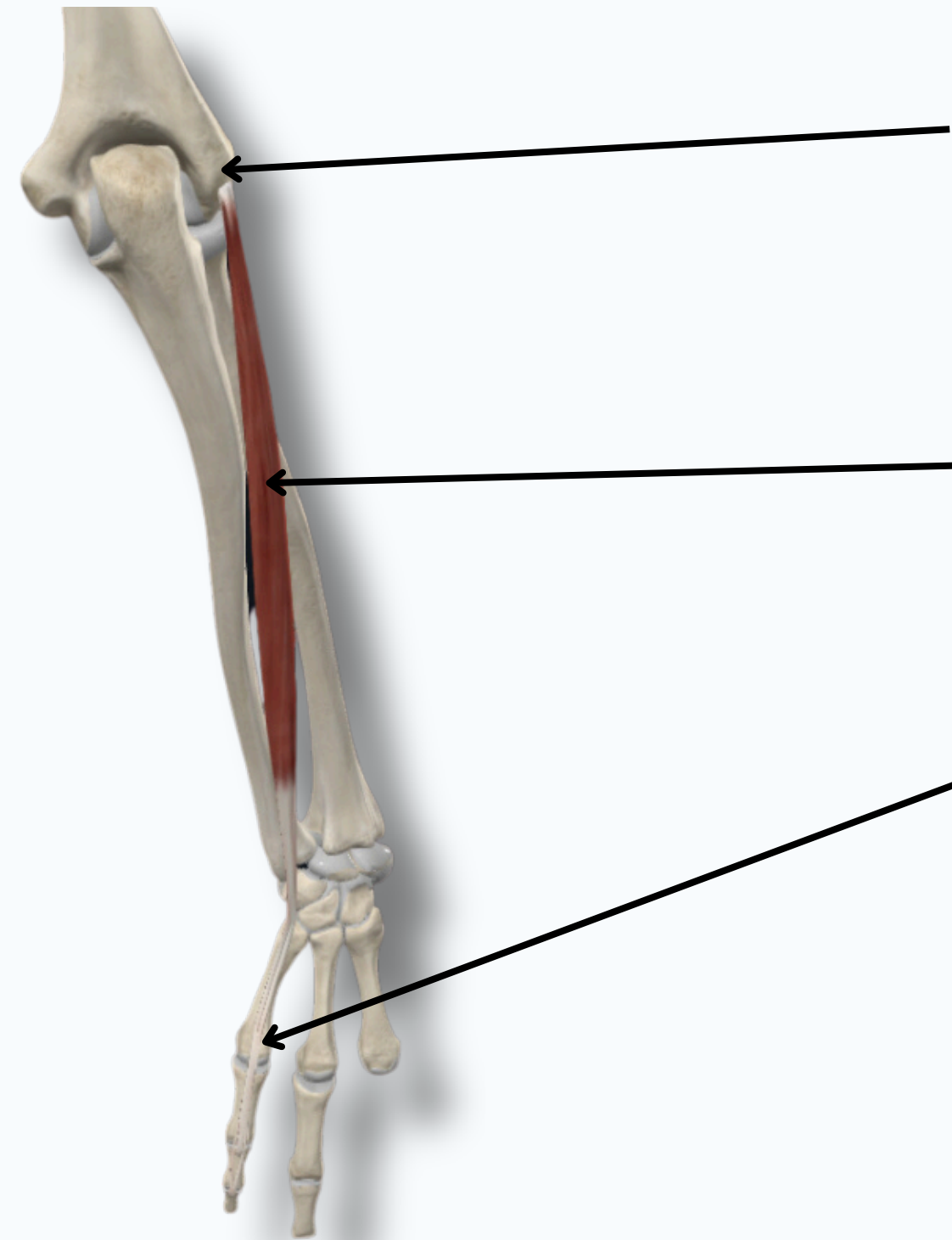
Insertion: Medial Aspect of the
Base of **5th Metacarpal Bone**



EXTENSOR MUSCLES OF THE FOREARM



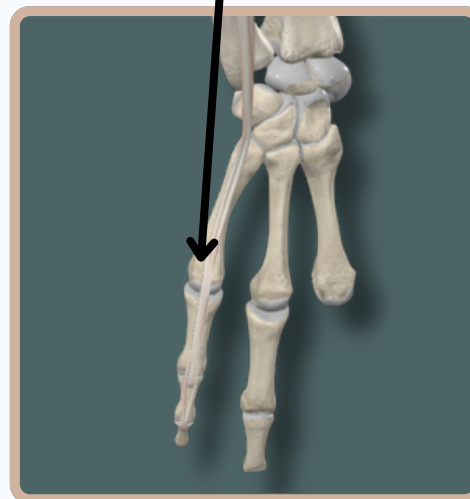
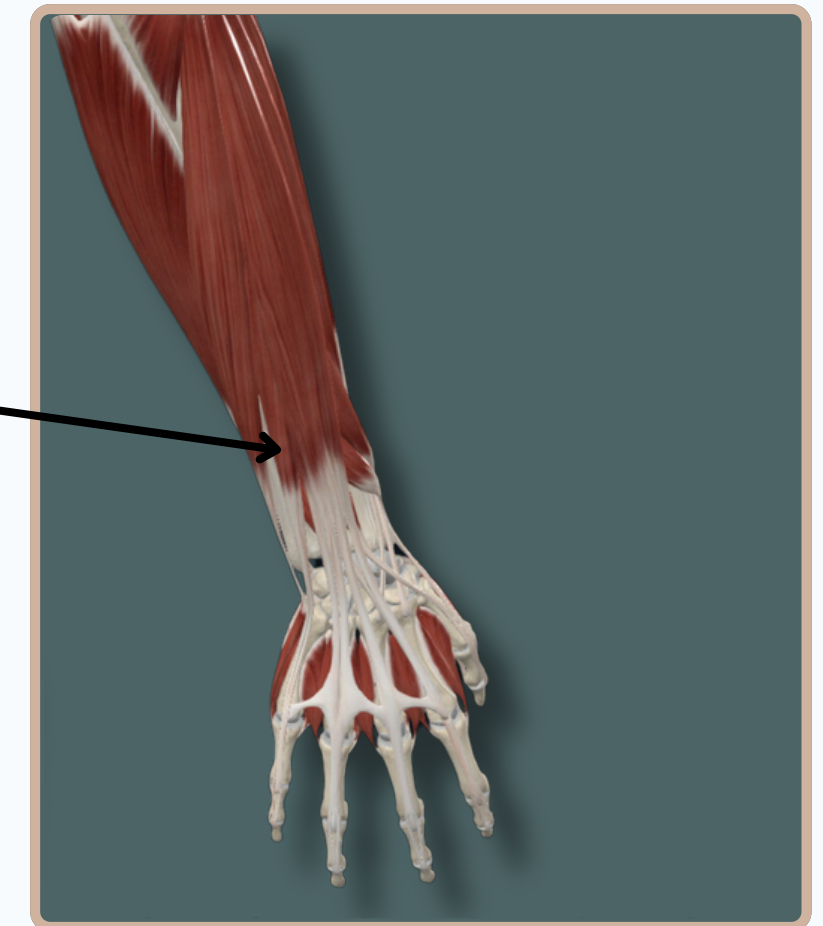
EXTENSOR DIGITI MINIMI



Origin: Lateral Epicondyle of the **Humerus**
Via Common Extensor Tendon

Extensor Digiti minimi

Insertion: Extensor Expansion of
the **Little Finger**



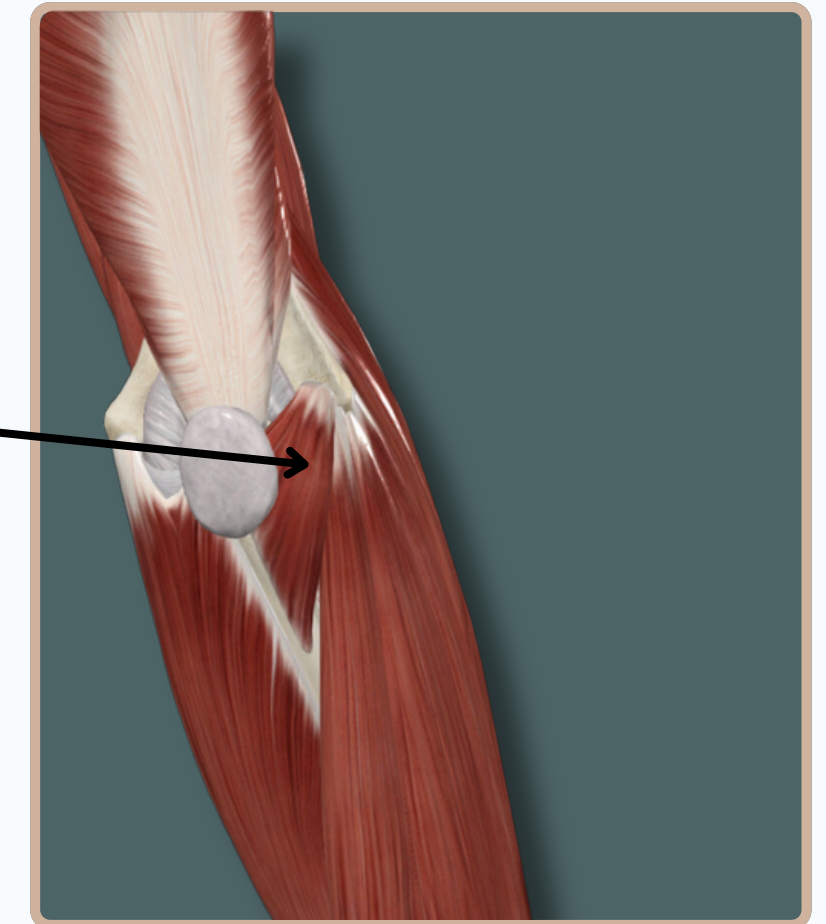
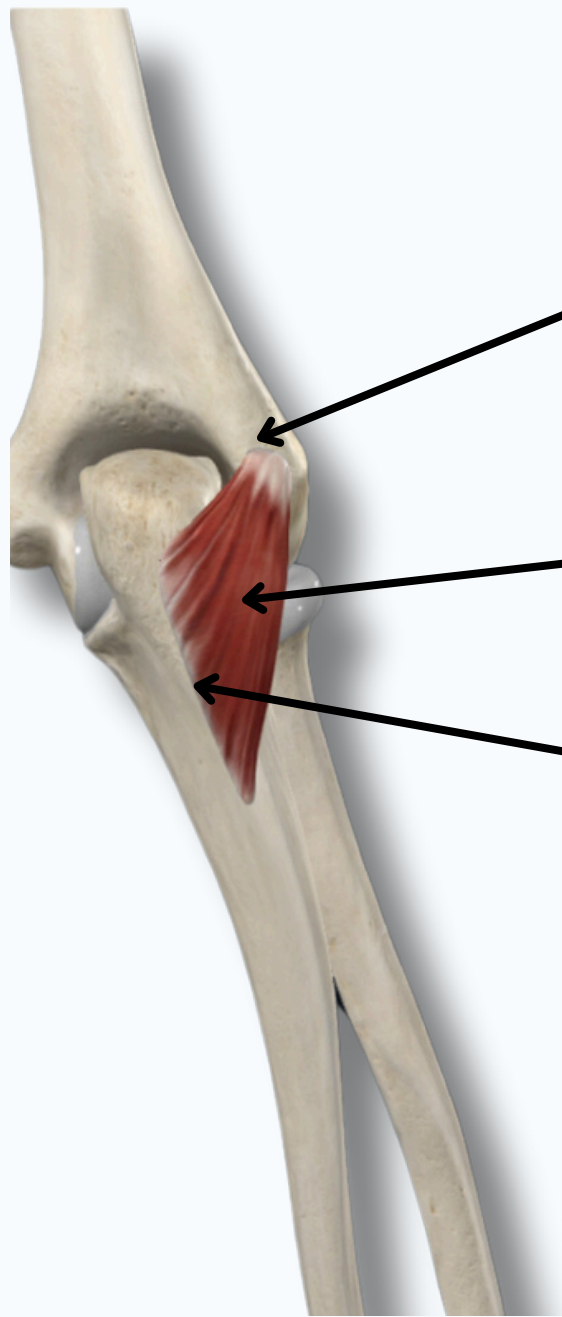
EXTENSOR MUSCLES OF THE FOREARM

ANCONEOUS

Origin: Posterior Aspect of the Lateral Epicondyle of **Humerus**

Anconeus

Insertion: Olecranon Process and Proximal End of the Body of **Ulna**



EXTENSOR MUSCLES OF THE FOREARM

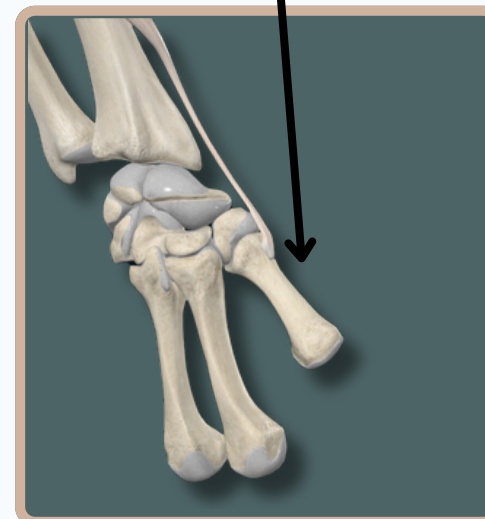
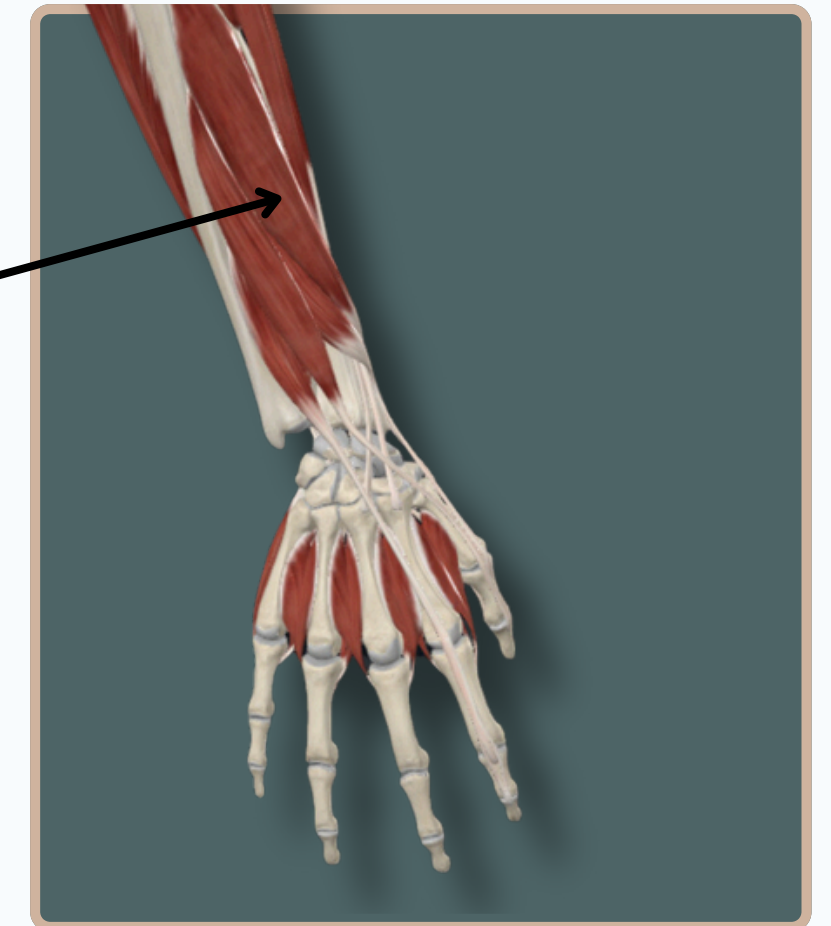
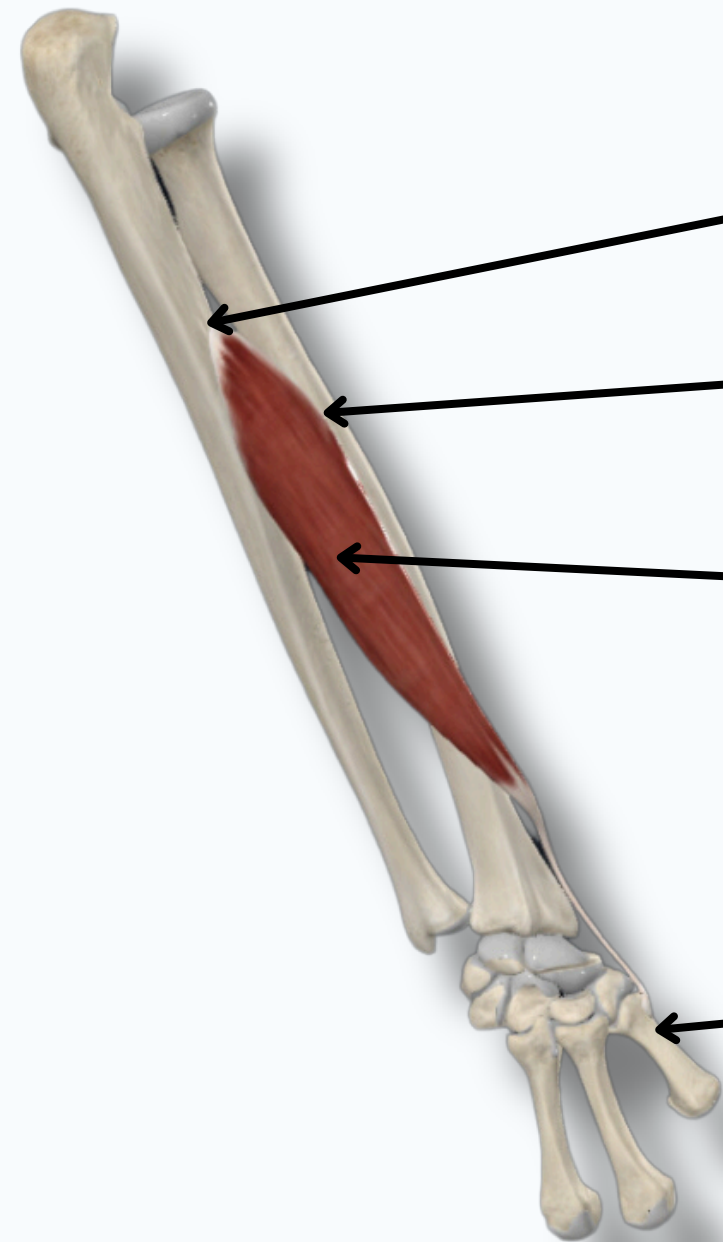
ABDUCTOR POLLICIS LONGUS

Origin: Posterior Aspects of Proximal Half of **Ulna** and Middle one Third of **Radius**

Origin: Middle one Third of **Radius**

Abductor pollicis longus

Insertion: Lateral Aspect of Base of **1st Metacarpal Bone**



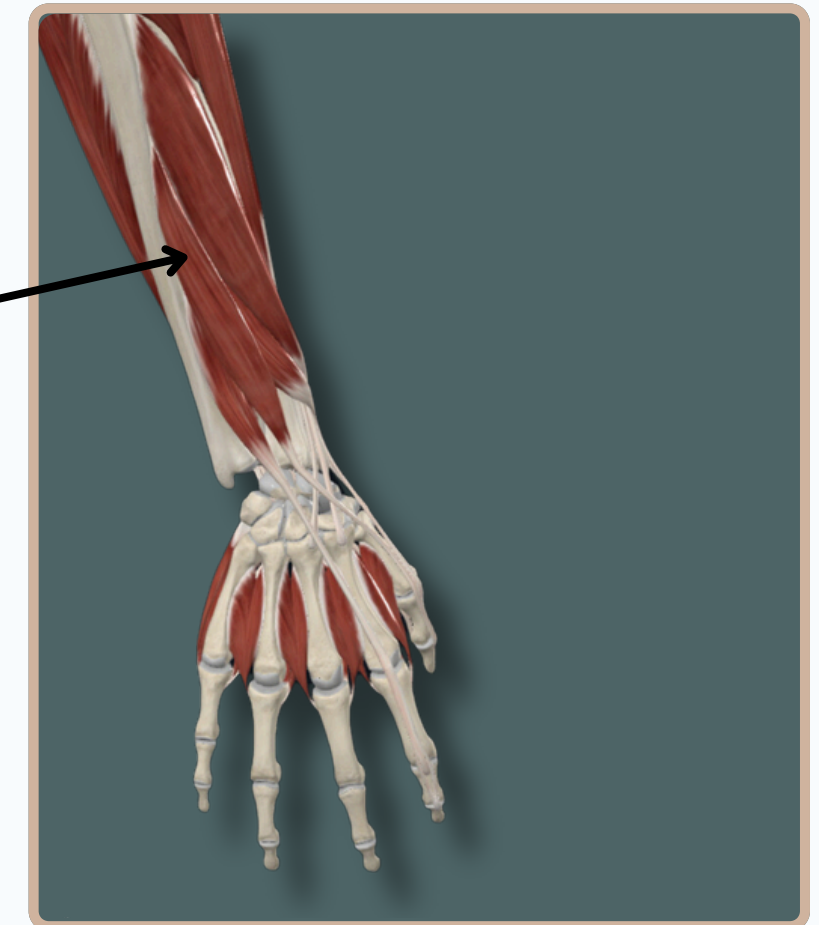
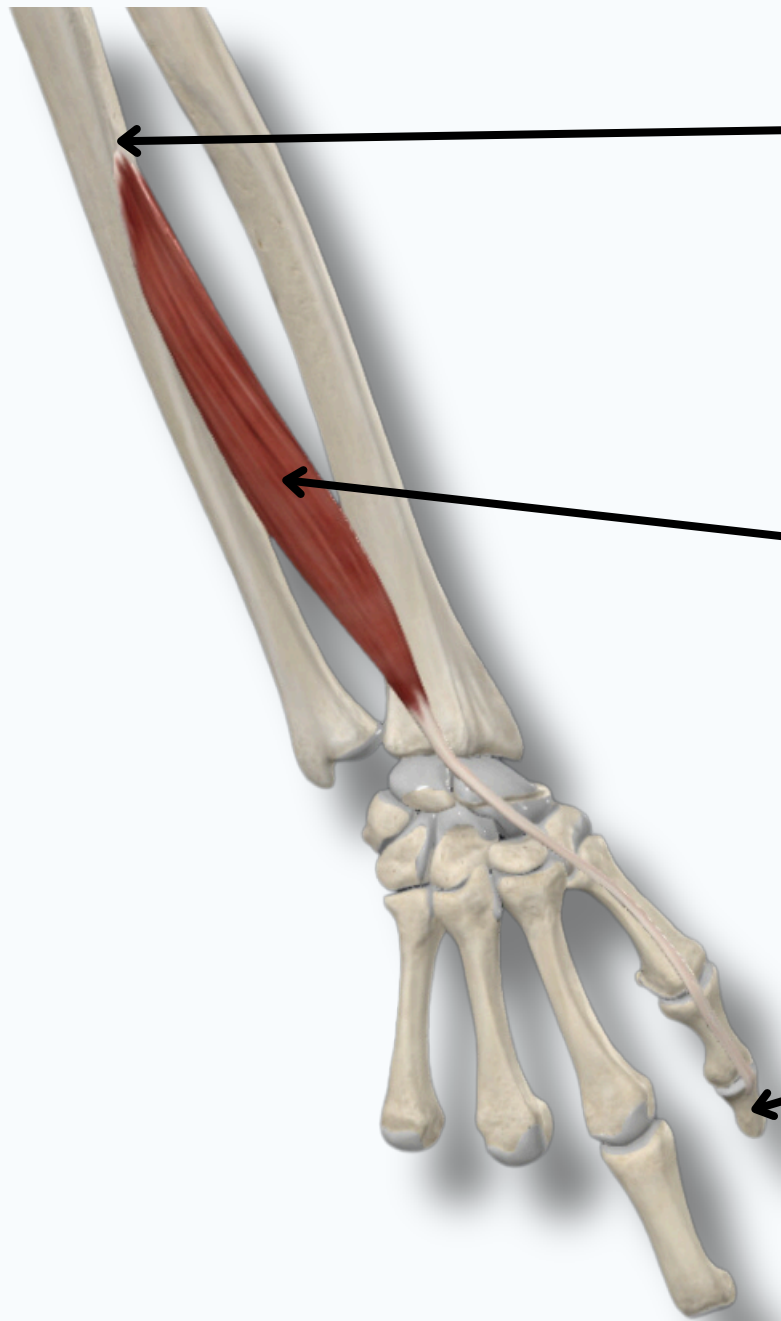
EXTENSOR MUSCLES OF THE FOREARM

EXTENSOR POLLICIS LONGUS

Origin: Posterior surface of middle one third of **ulna**

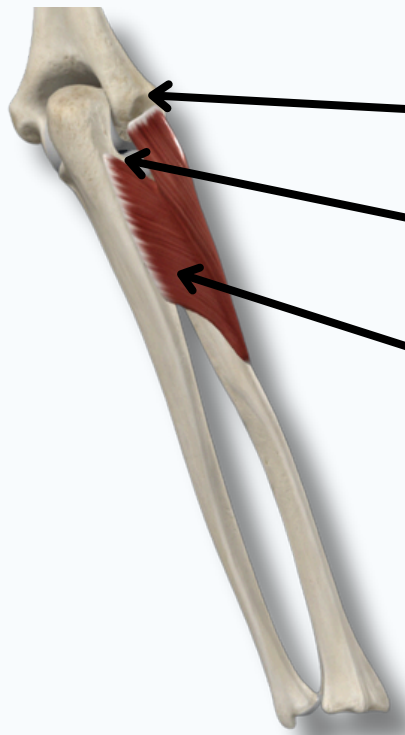
Extensor Pollicis Longus

Insertion: Dorsal Aspect of Base of Distal Phalanx of **Thumb**



EXTENSOR MUSCLES OF THE FOREARM

SUPINATOR

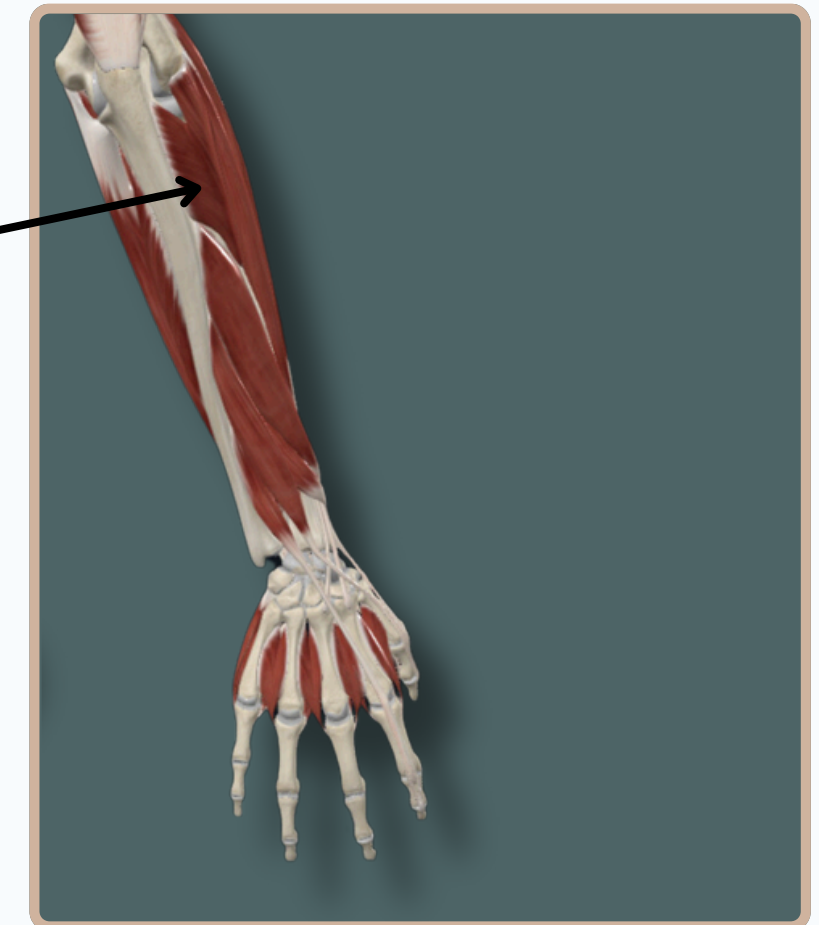


Origin: Lateral Epicondyle of **Humerus**

Origin: Supinator Crest and Supinator Fossa of **Ulna**

Supinator

Insertion: Anterior, Lateral, and Posterior Aspects of Proximal One Third of **Radius**



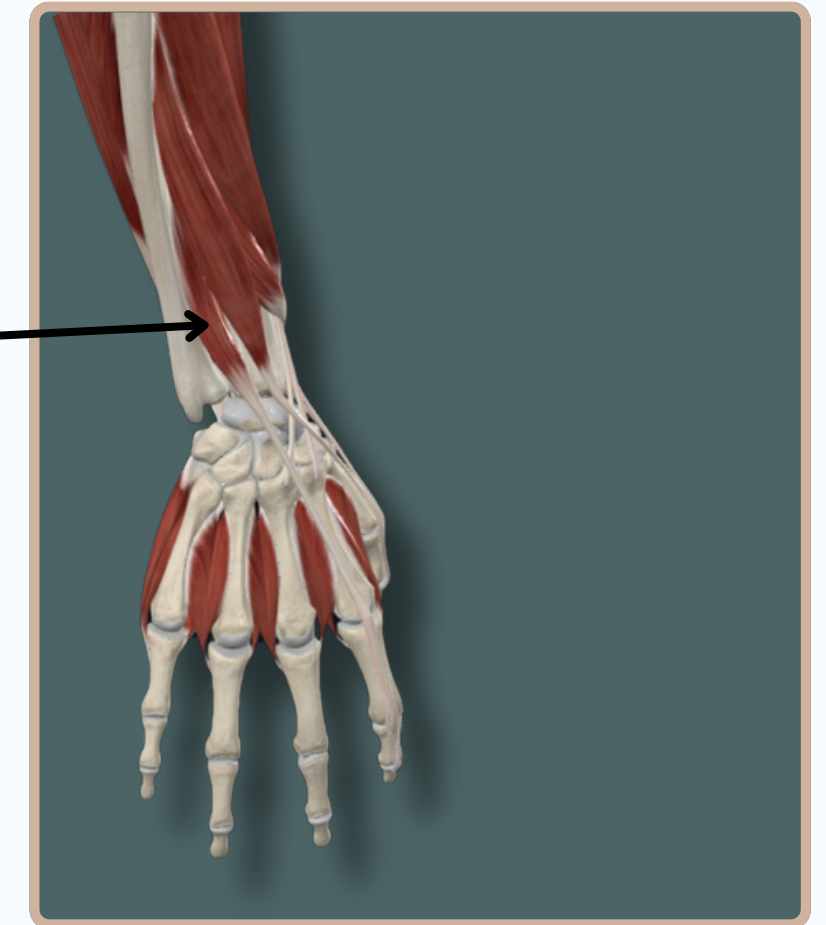
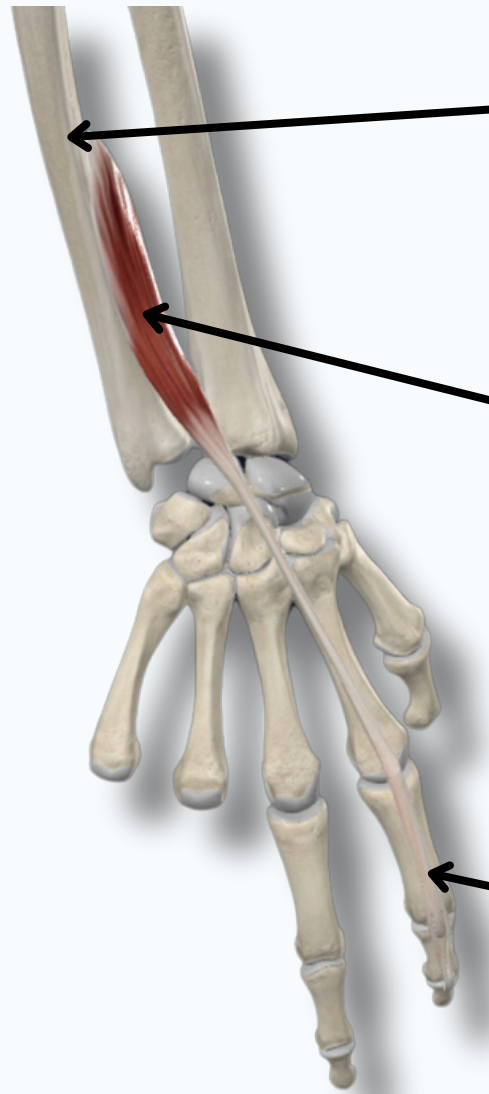
EXTENSOR MUSCLES OF THE FOREARM

EXTENSOR INDICIS

Origin: Posterior Surface of Distal One Third Of **Ulna**

Extensor Indicis

Insertion: Extensor Expansion of **Index Finger**



THANK YOU

EDITED BY



SATURN
MEDIC



ARECH

© ALL COPYRIGHT ARE RESERVED FOR
SATURN MEDIC AND ARECH

WWW.SATURNMEDIC.COM