

ANATOMY OF UPPER LIMB

PRACTICAL LECTURE - 12 -

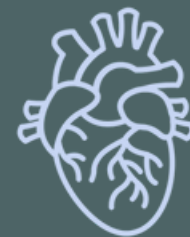MUSCLES / PART 7

MUSCLES OF THE HAND

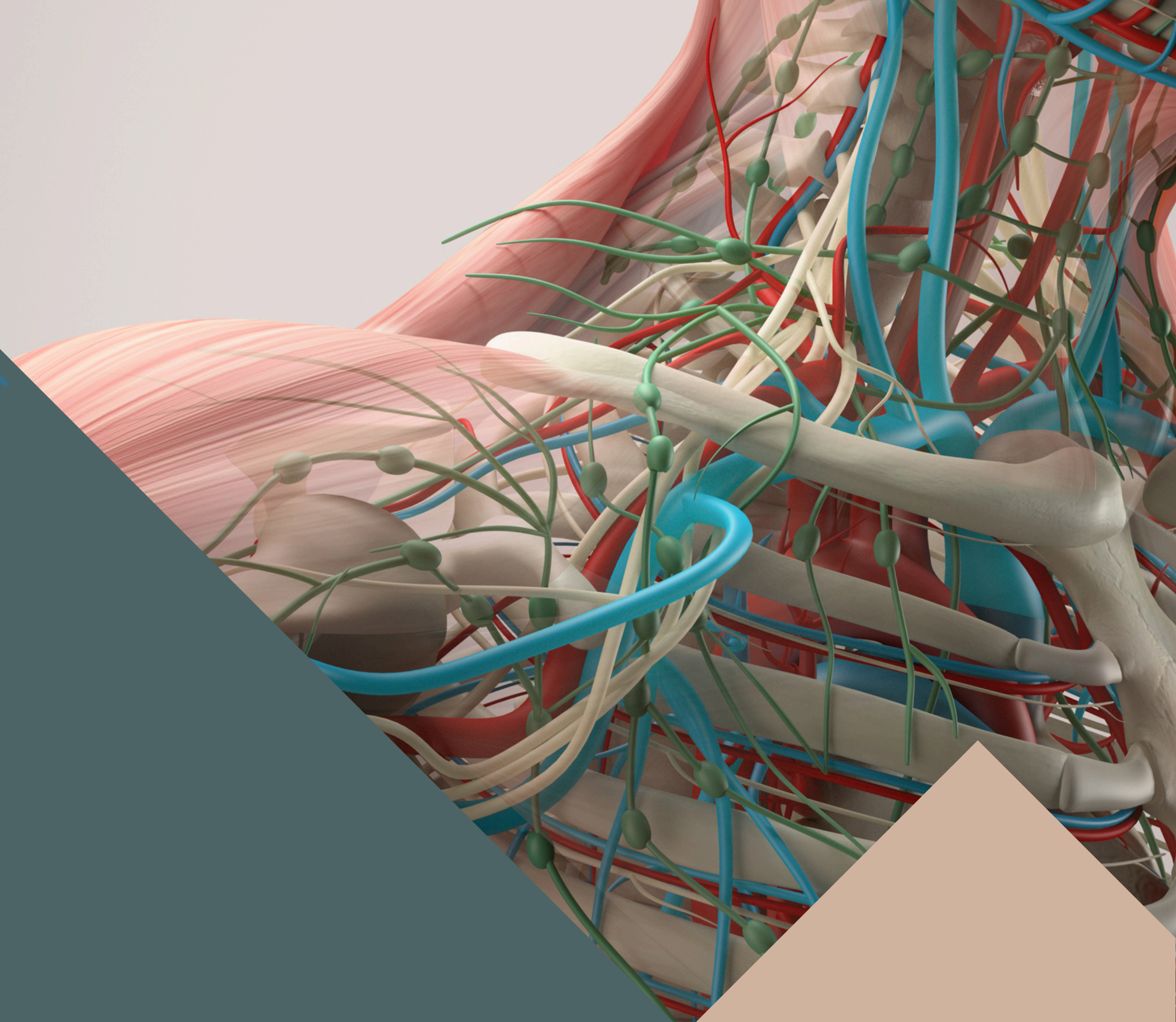
EDITED BY



SATURN
MEDIC



ARECH

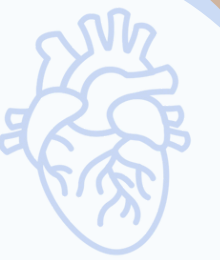

ALL COPYRIGHT ARE RESERVED FOR
SATURN MEDIC AND ARECH

WWW.SATURNMEDIC.COM

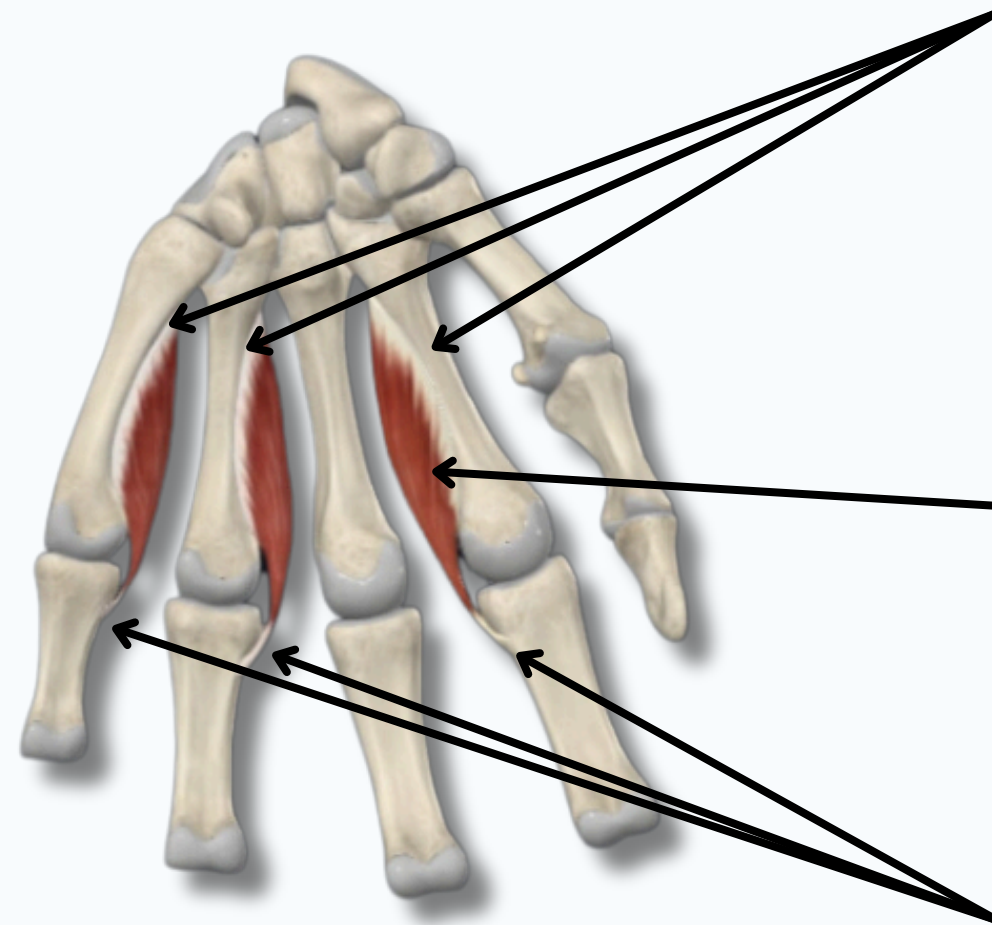


MUSCLES OF THE HAND



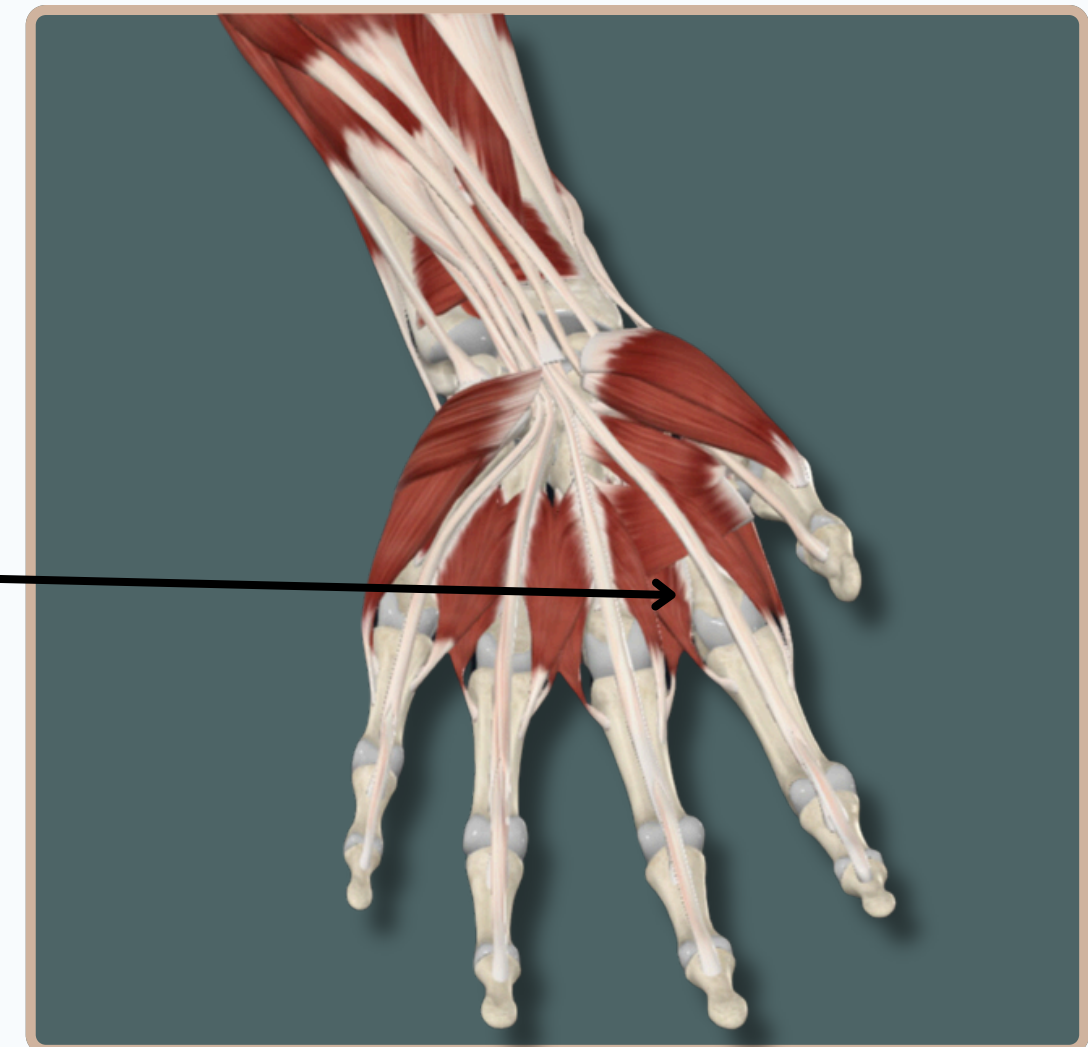
PALMAR INTEROSSEOUS

Origin : Palmar aspect of second ,
Forth And Fifth **metacarpal bones**



Palmar Interosseous

Insertion : Medial Aspect of Base of
Proximal Phalanx And Extensor
Expansion



Anterior View

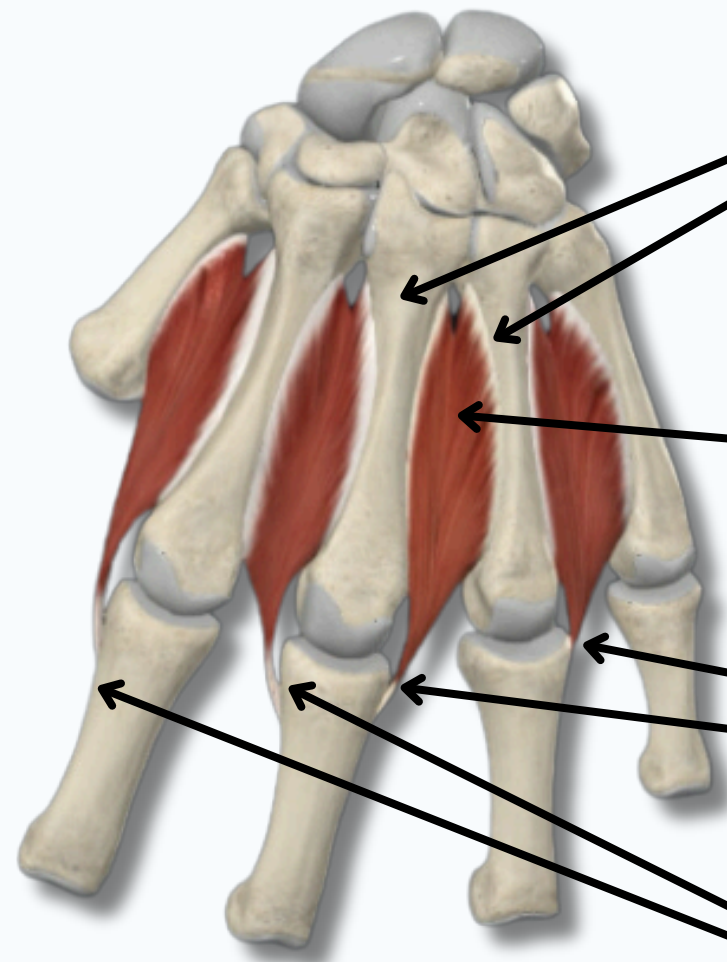


MUSCLES OF THE HAND



DORSAL INTEROSSEOUS

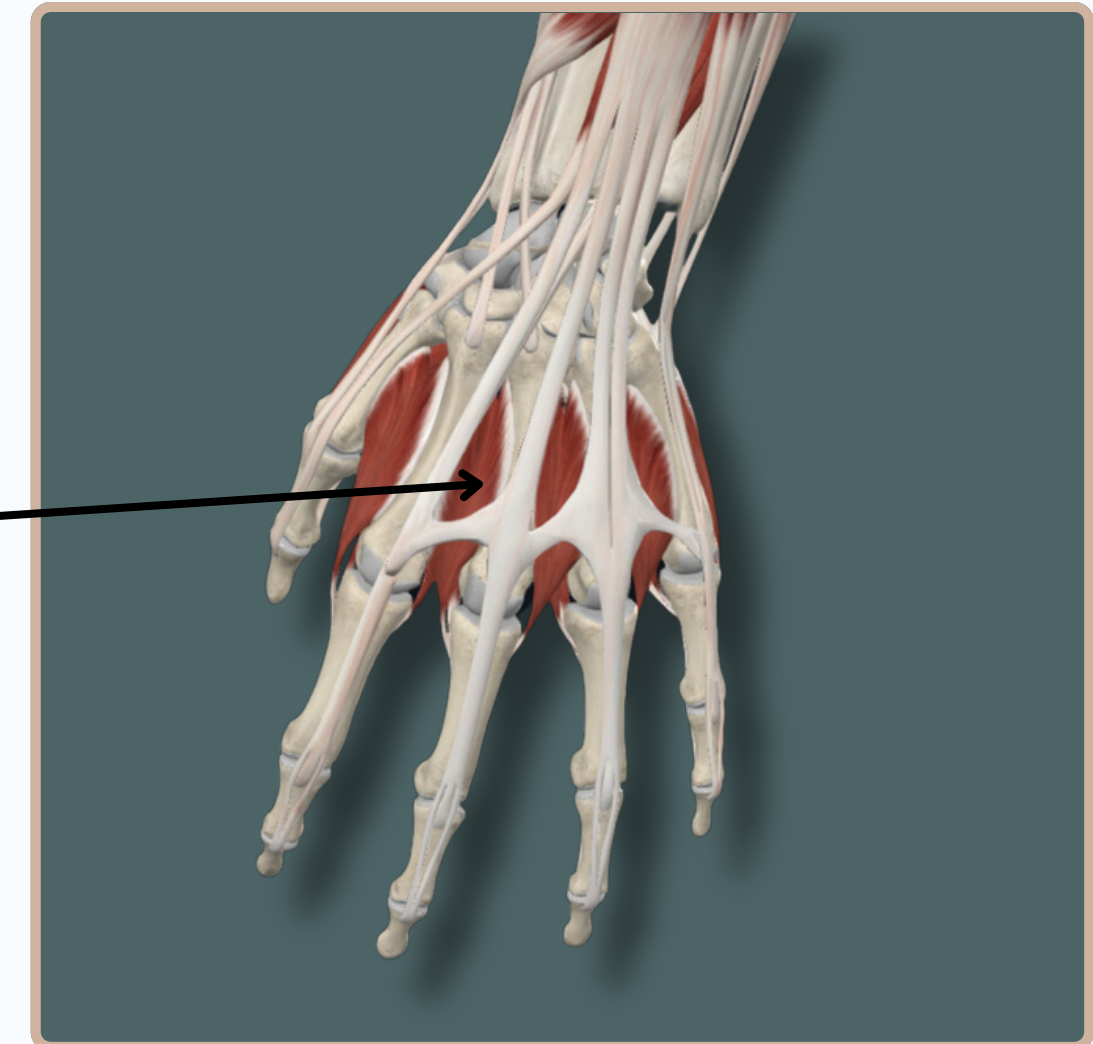
Origin : Medial Aspect of Body of Metacarpal Bone and Lateral Aspect of Body of Next **Metacarpal Bone**



Posterior View

Dorsal Interosseous

Insertion : Lateral aspect (For The **First** And **Second** Dorsal Interossei) And **Medial Aspect** (For **Third** And **Fourth** Dorsal Interossei) of Base of **Proximal Phalanx** and **Extensor Expansion**



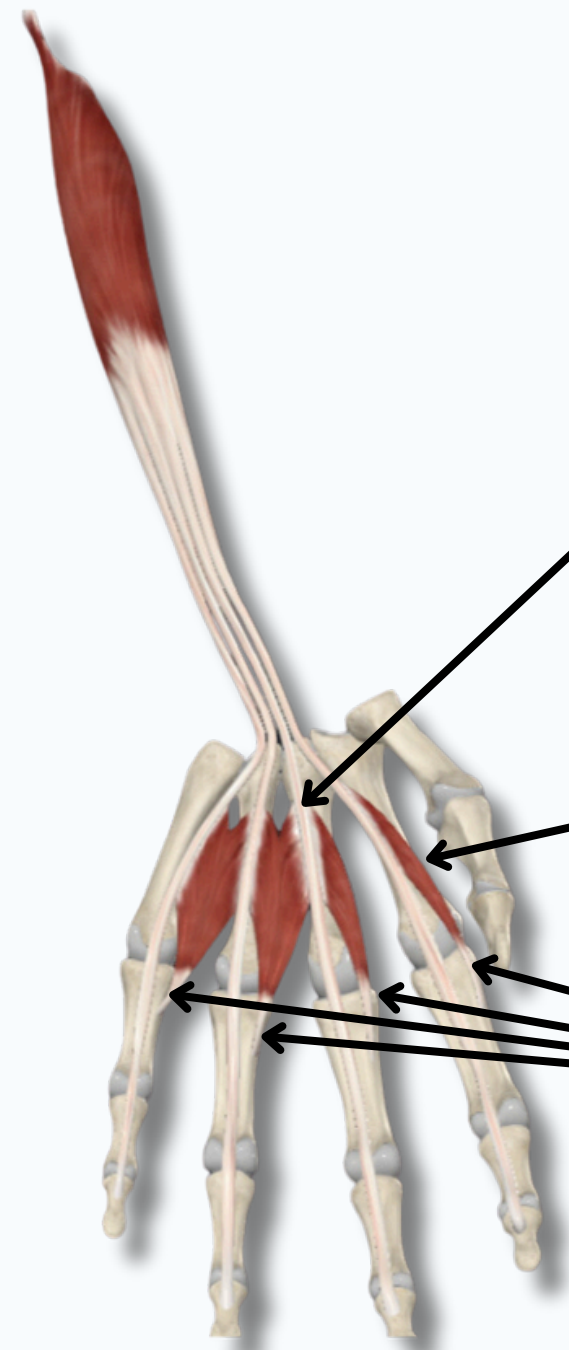
Posterior View



MUSCLES OF THE HAND



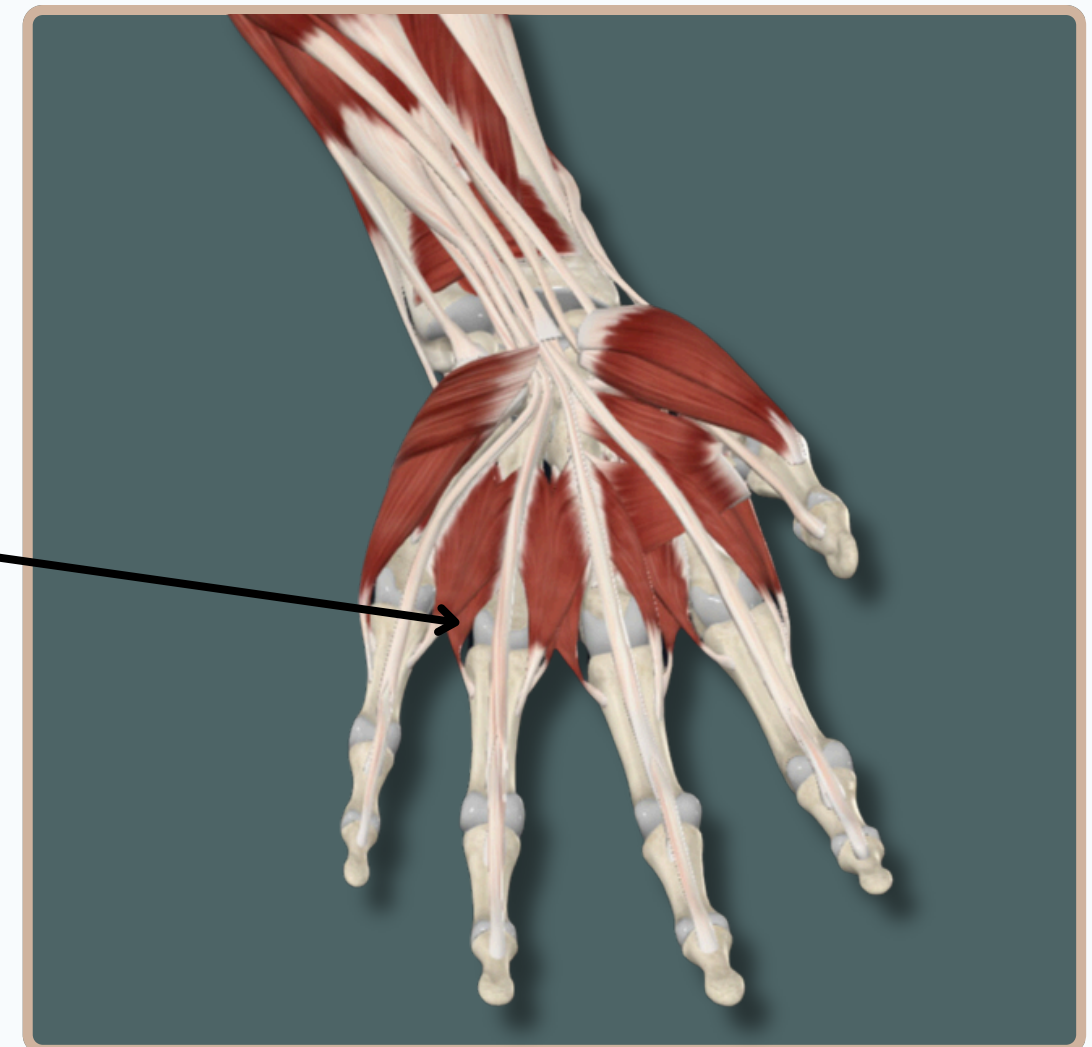
LUMBRICALS



Origin : Tendons of flexor **digitorum profundus**

Lumbricals

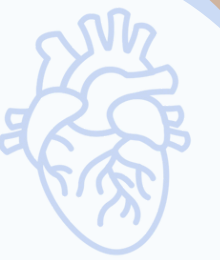Insertion : Lateral aspect of the **extensor expansion**



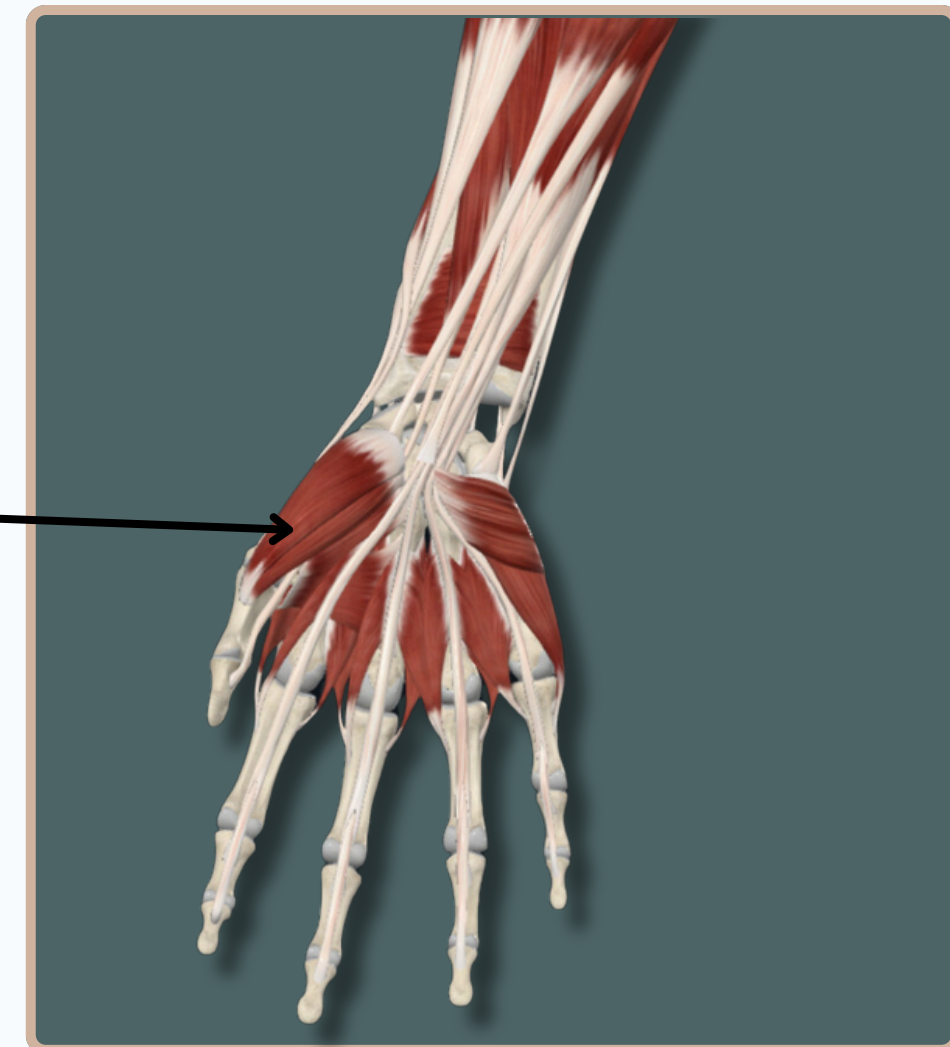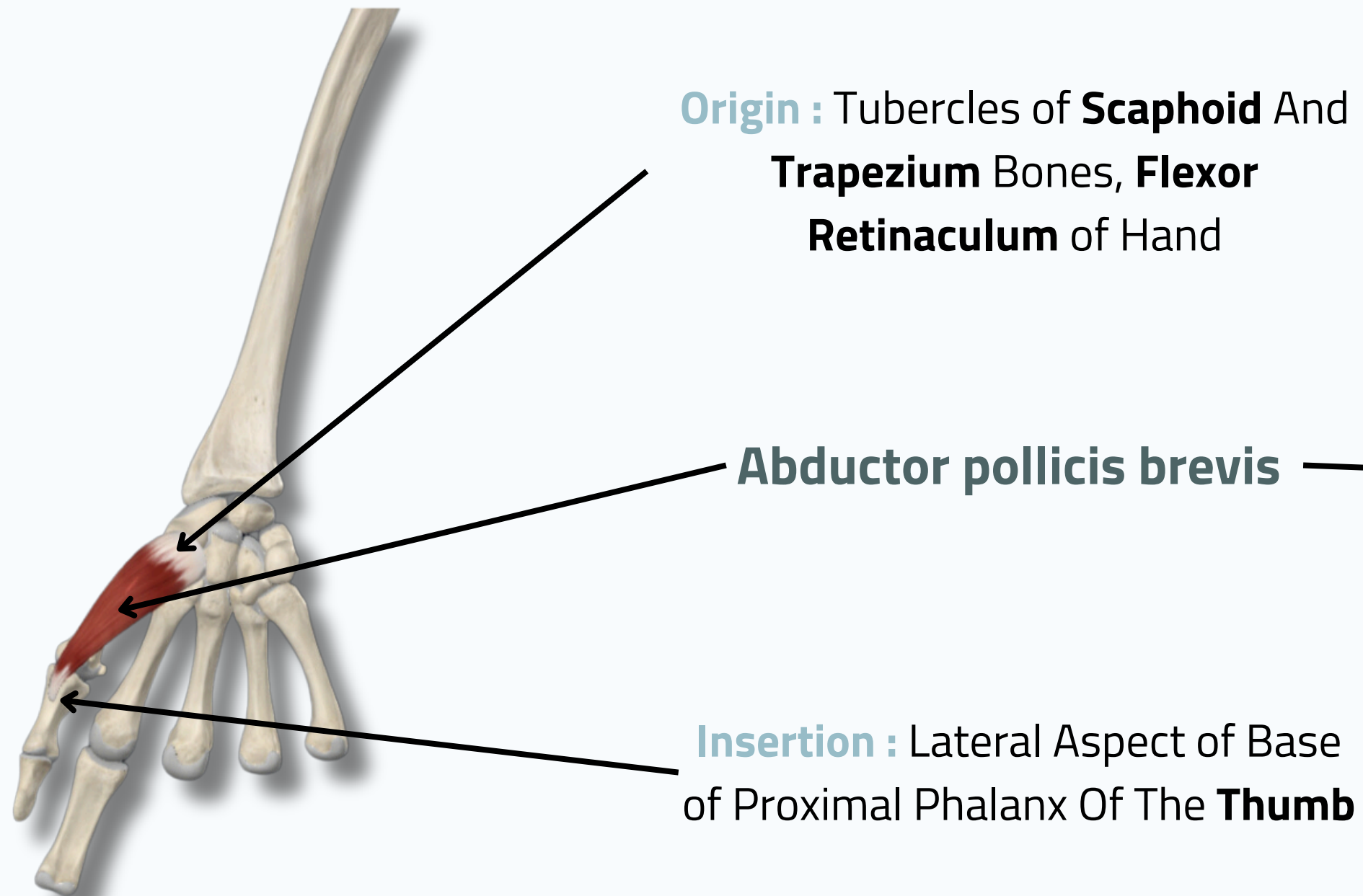
Anterior View



MUSCLES OF THE HAND



ABDUCTOR POLLICIS BREVIS



Anterior View

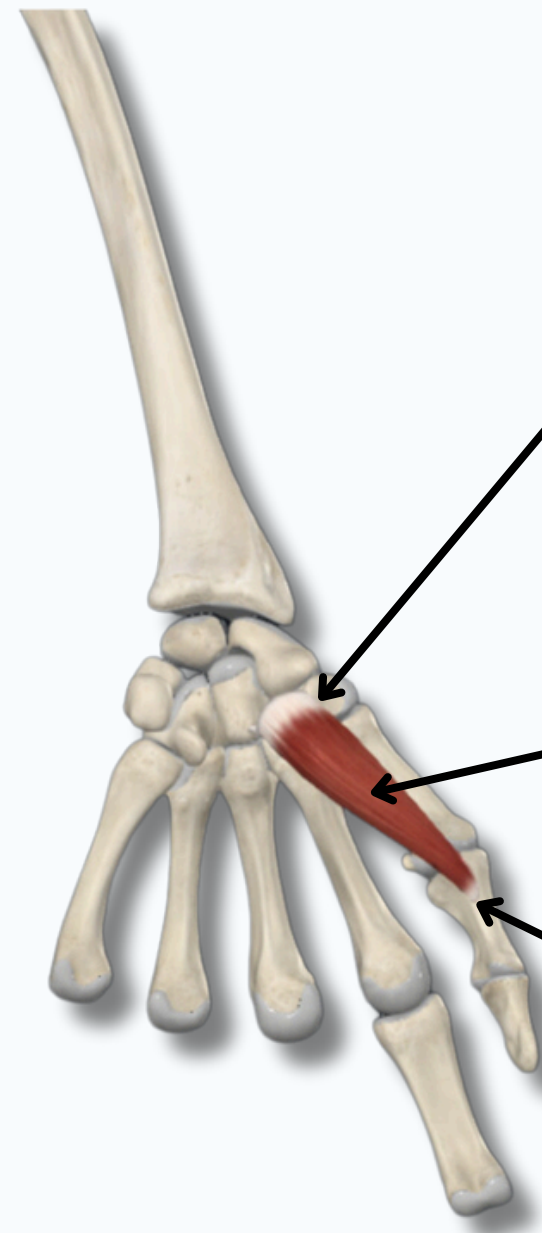


MUSCLES OF THE HAND



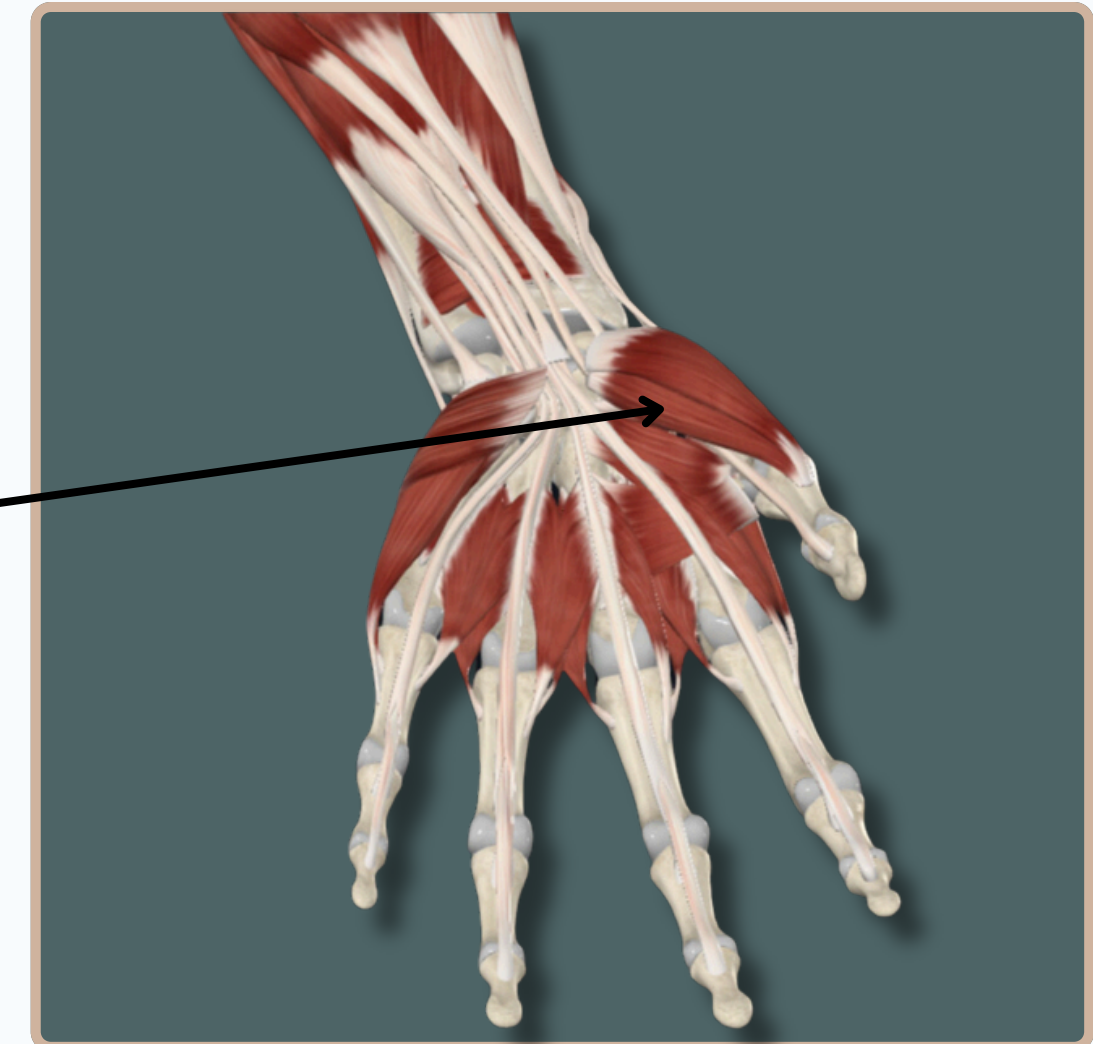FLEXOR POLLICIS BREVIS

Origin : a large superficial head, which originates from the tubercle of trapezium bone and the flexor retinaculum of hand;
- a **small deep head**, which originates from the palmar aspects of the capitate and trapezoid bones.



Flexor Pollicis brevis

Insertion : Lateral Aspect of The Base of The Proximal Phalanx of **Thumb**



Anterior View



MUSCLES OF THE HAND

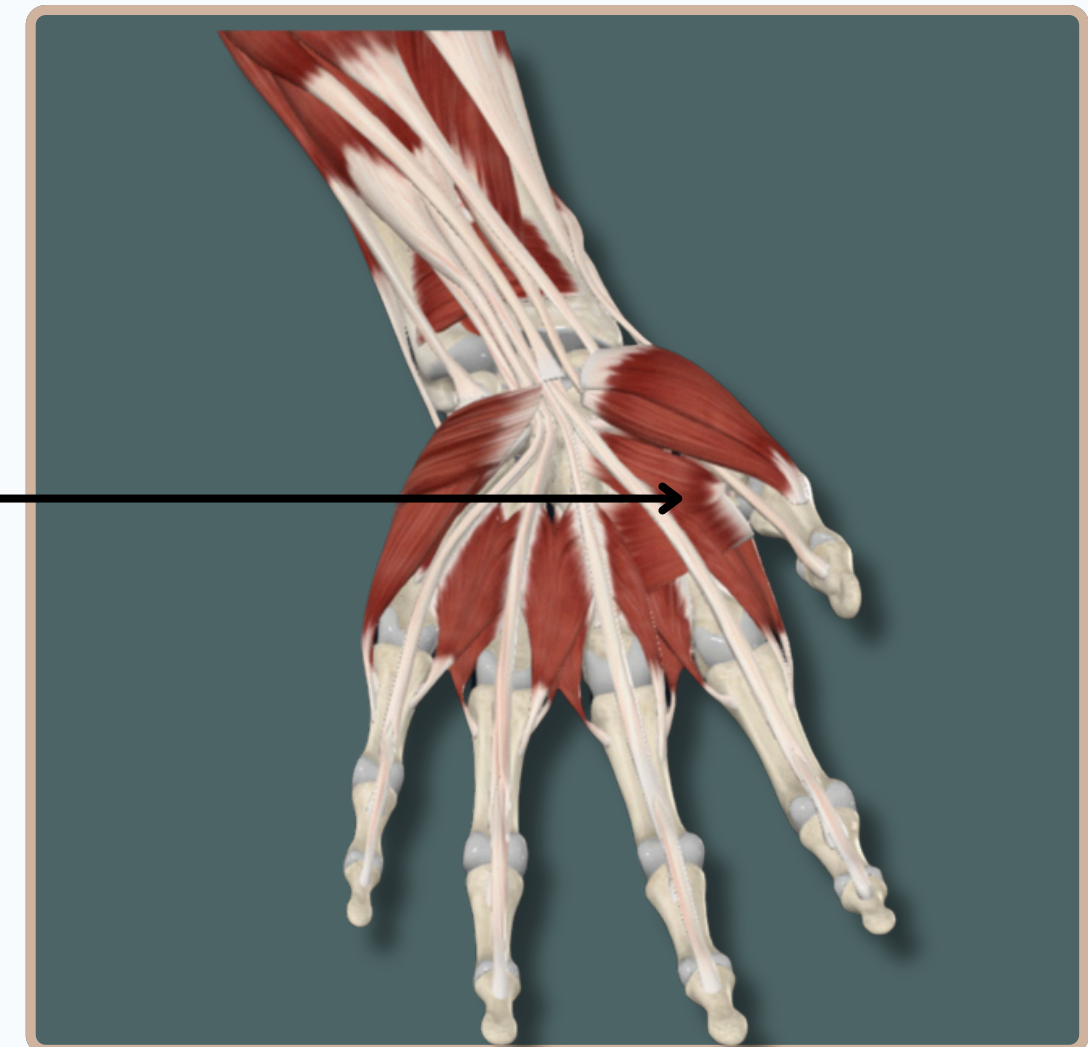
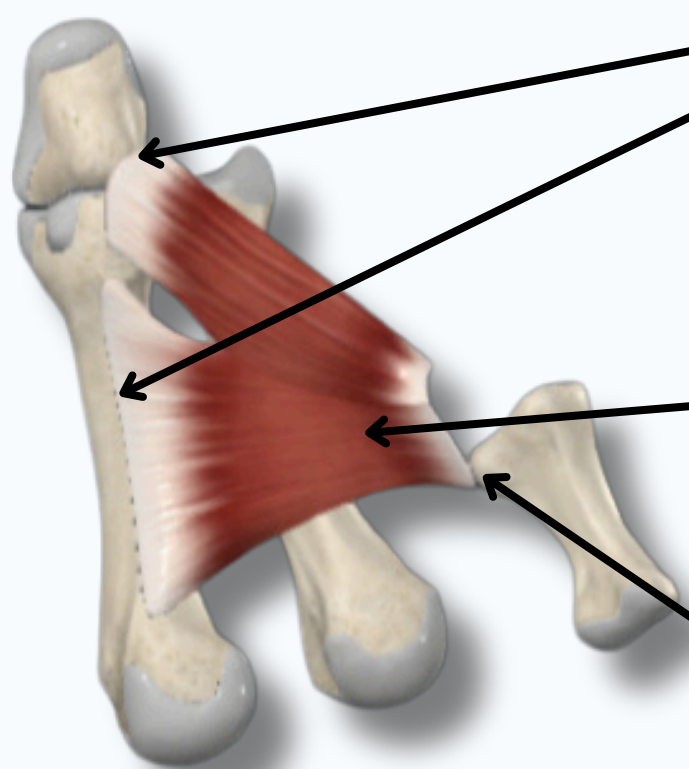


ADDUCTOR POLLICIS

Origin : Palmar Aspects of **Capitate** Bone, Bases of Second And Third **Metacarpal Bones**, and body of **Third Metacarpal Bone**

Adductor Pollicis

Insertion : Medial Aspect of Base of The Proximal Phalanx of **Thumb**



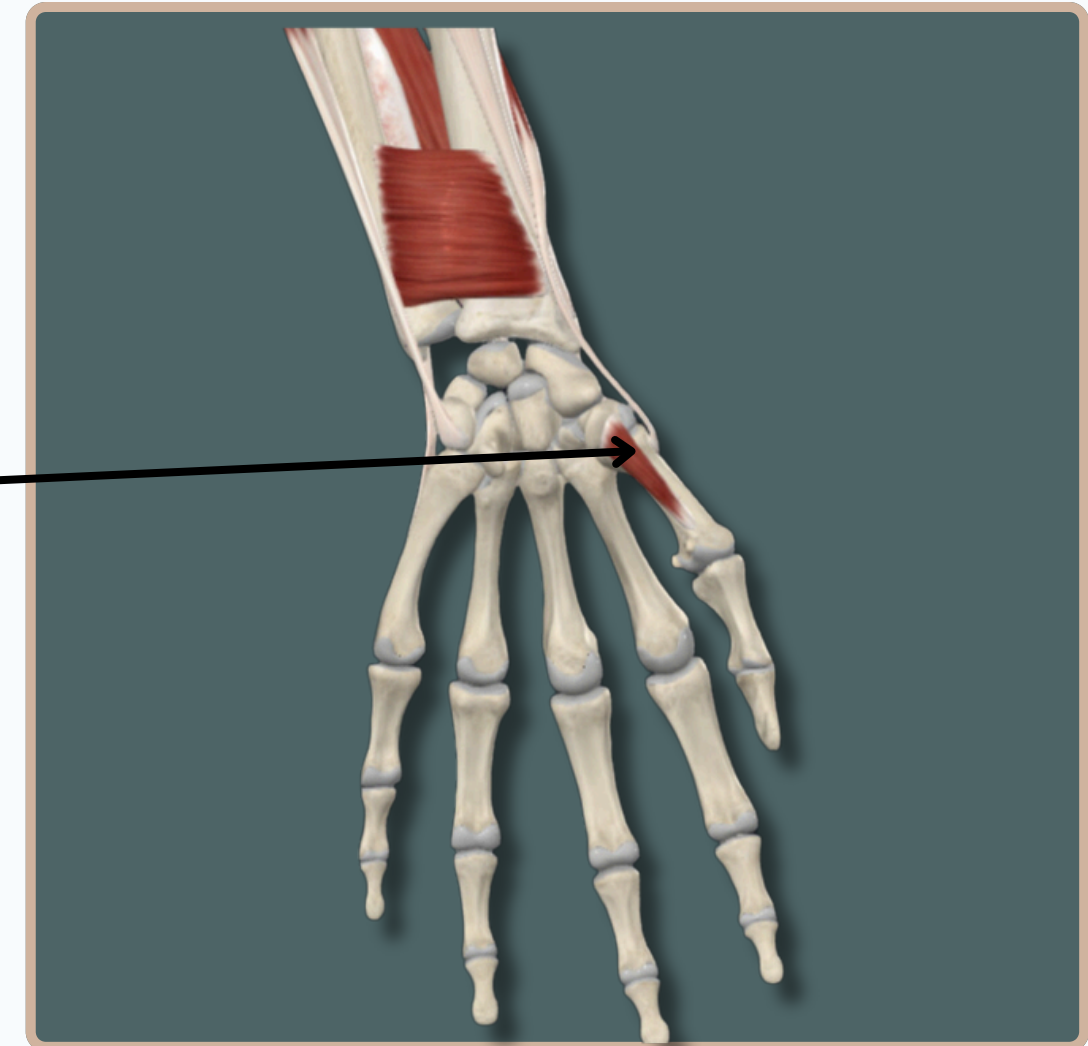
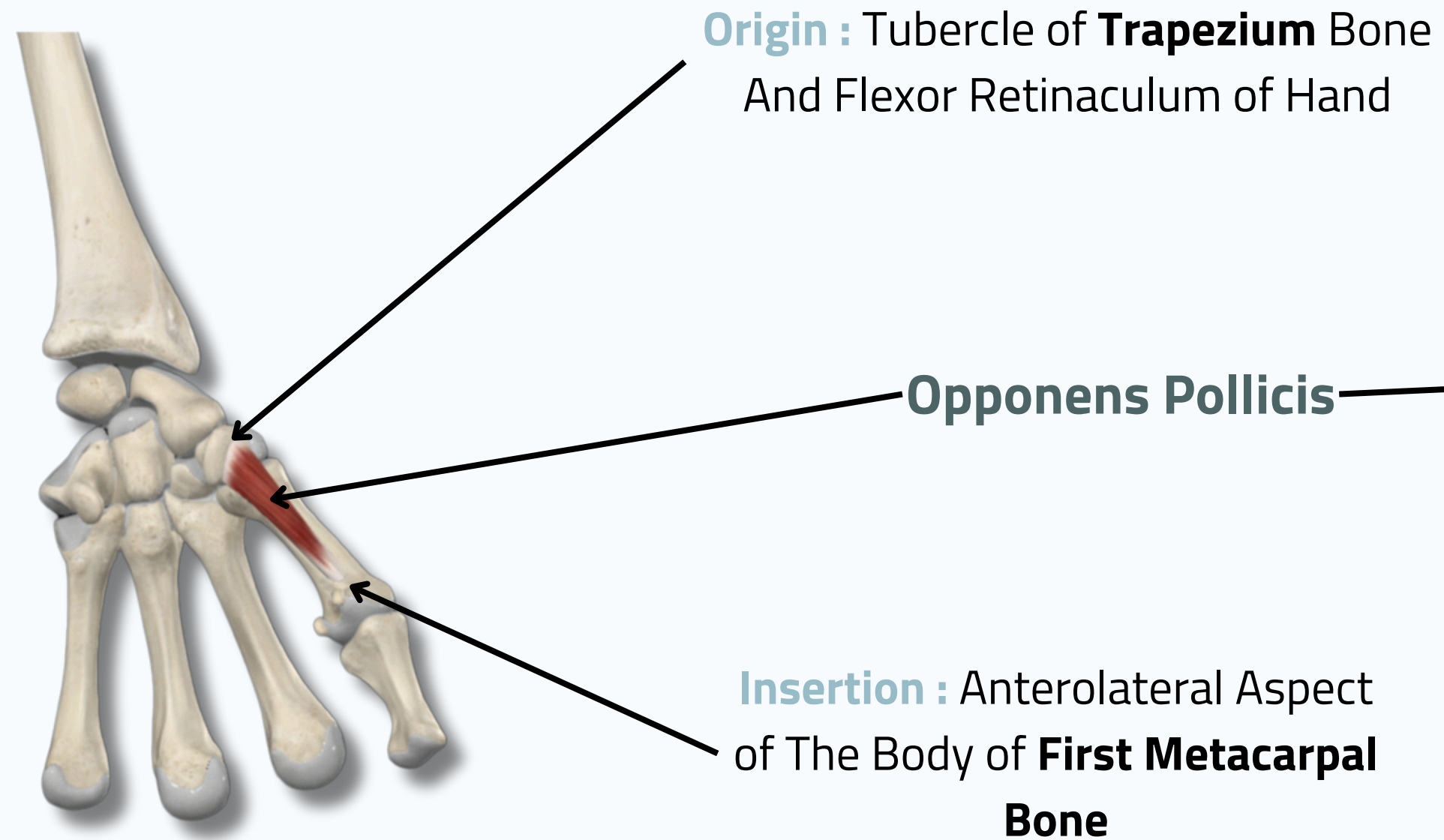
Anterior View



MUSCLES OF THE HAND



OPPONENS POLLICIS



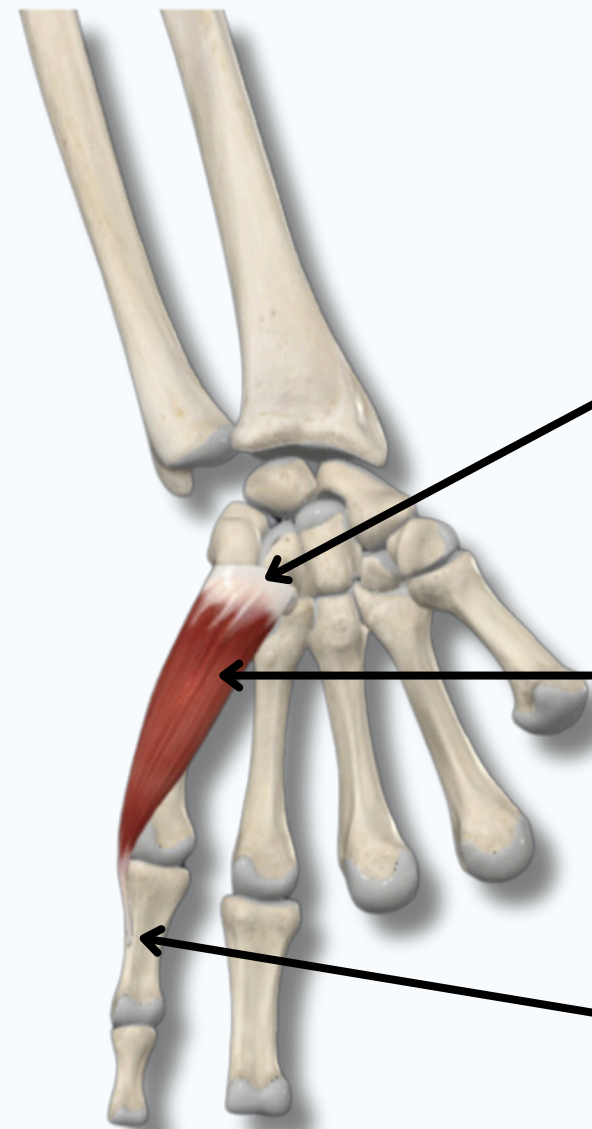
Anterior View



MUSCLES OF THE HAND



ABDUCTOR DIGITI MINIMI



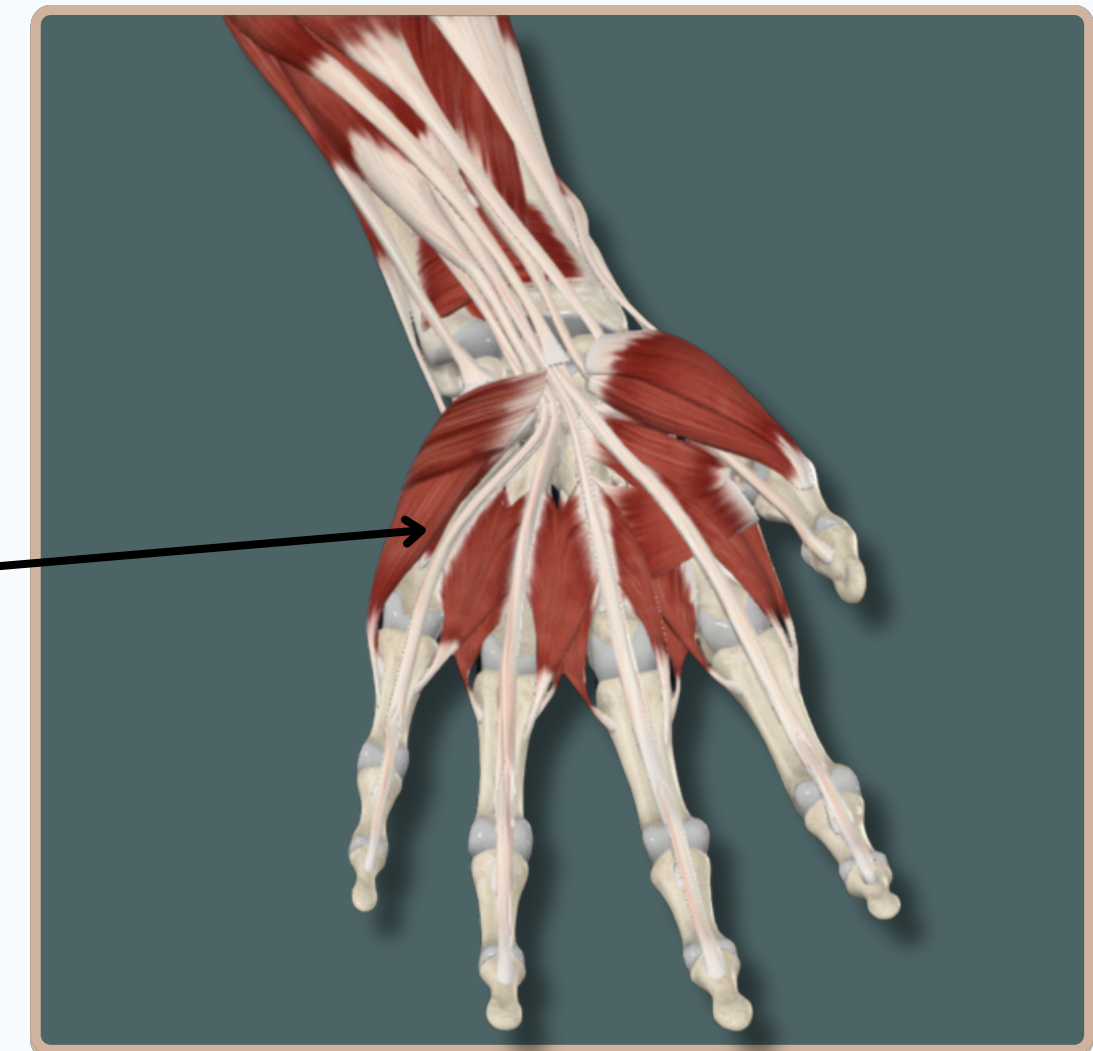
Origin : - **Pisiform** Bone

- Tendon of **Flexor Carpi Ulnaris**;
- Pisohamate **Ligament**

Abductor Digiti Minimi

Insertion : - Medial Aspect of The Base of The Proximal Phalanx of Little Finger

- Extensor Expansion of **Little Finger**



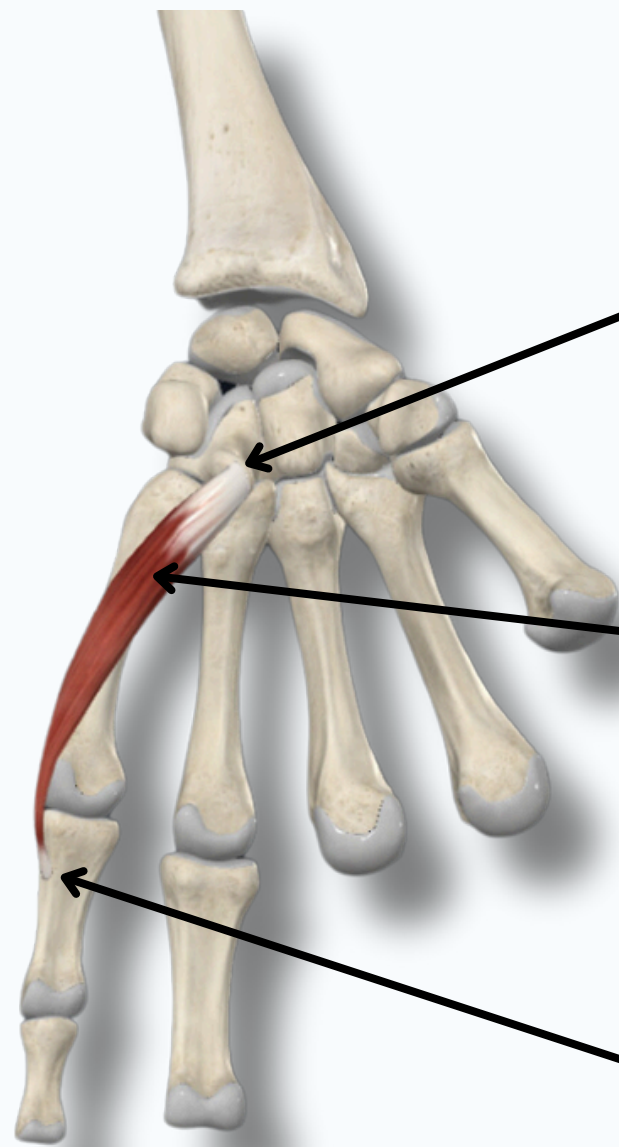
Anterior View



MUSCLES OF THE HAND



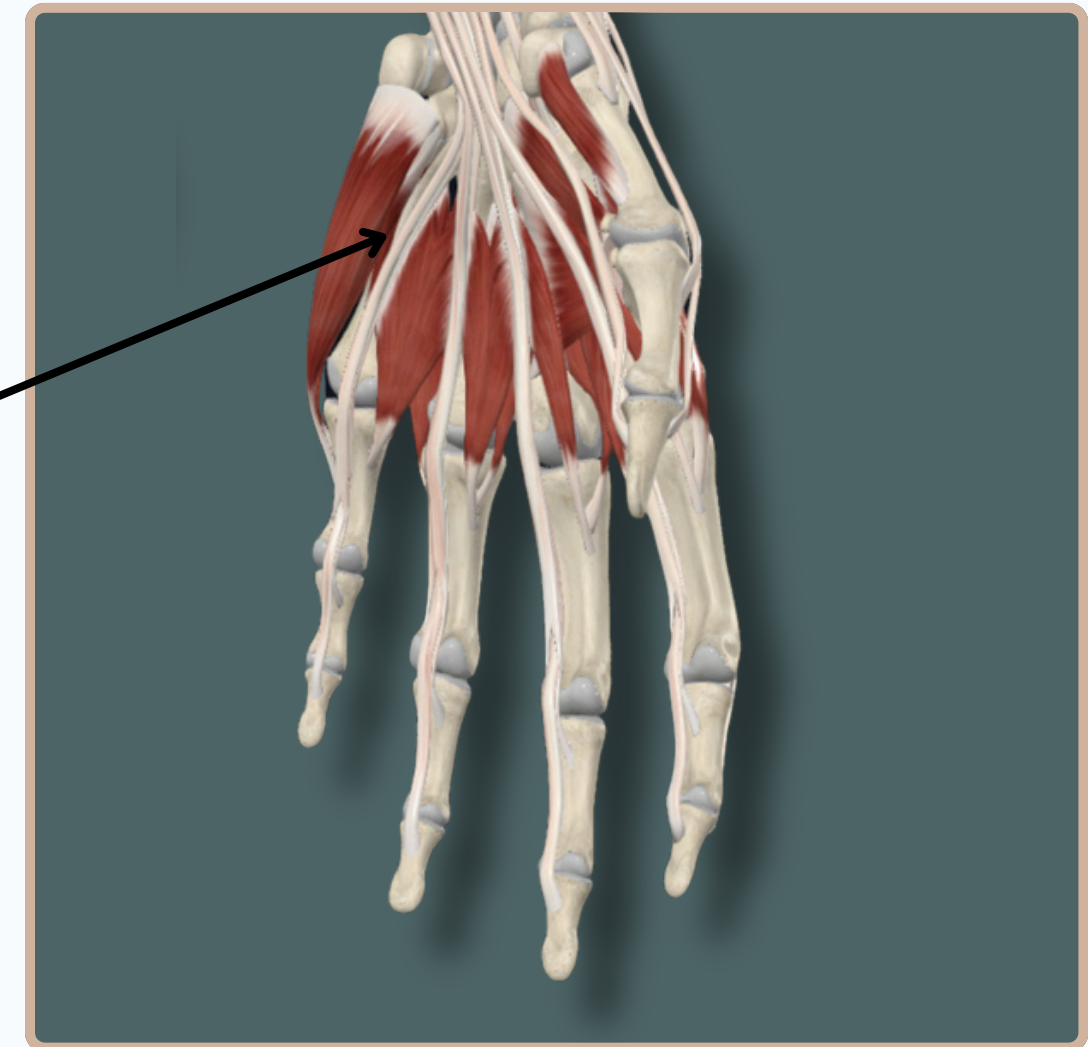
FLEXOR DIGITI MINIMI



Origin : - Hook of **Hamate Bone** and **Flexor Retinaculum** of Hand

Flexor Digiti Minimi

Insertion: Medial Aspect of Base of Proximal Phalanx of **Little Finger**



Anterior View



MUSCLES OF THE HAND

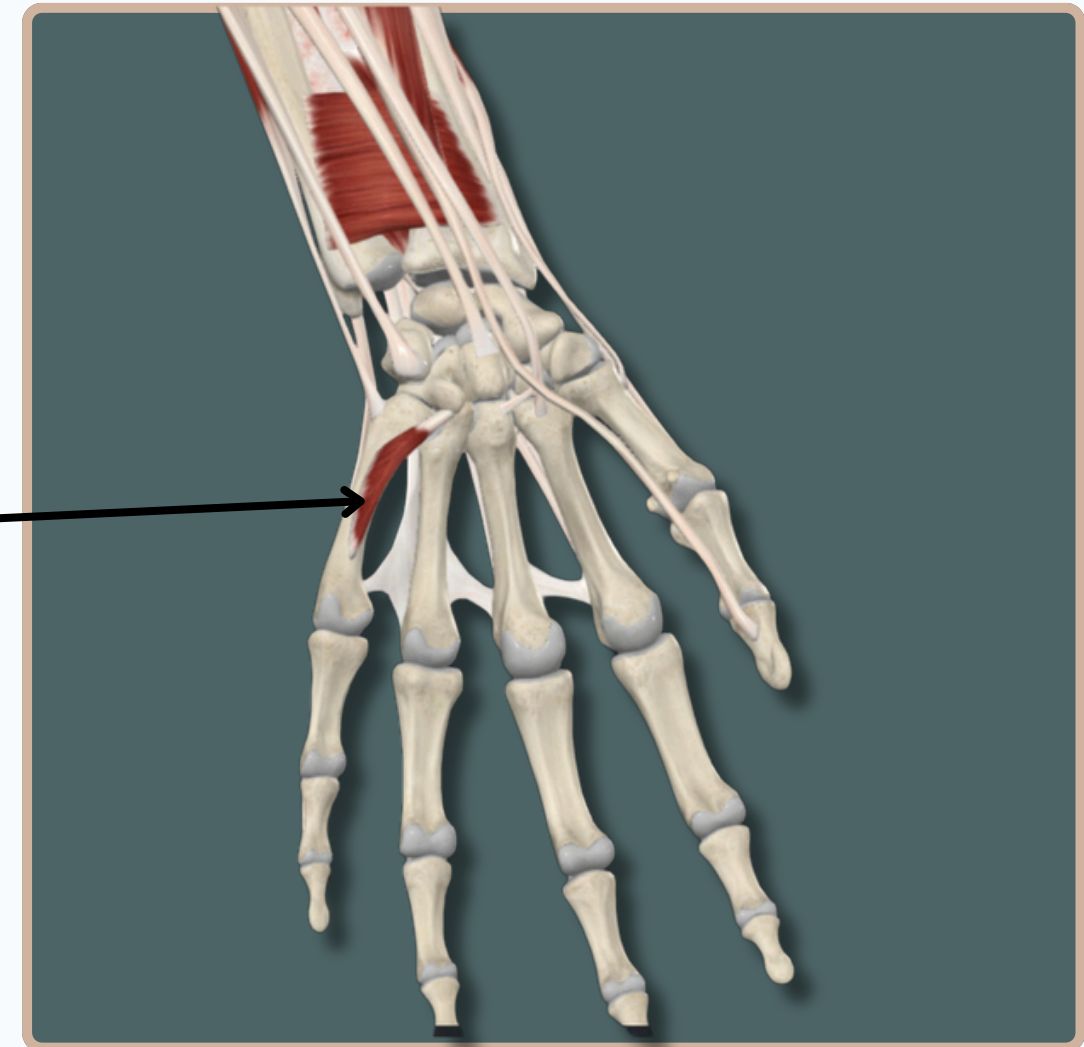
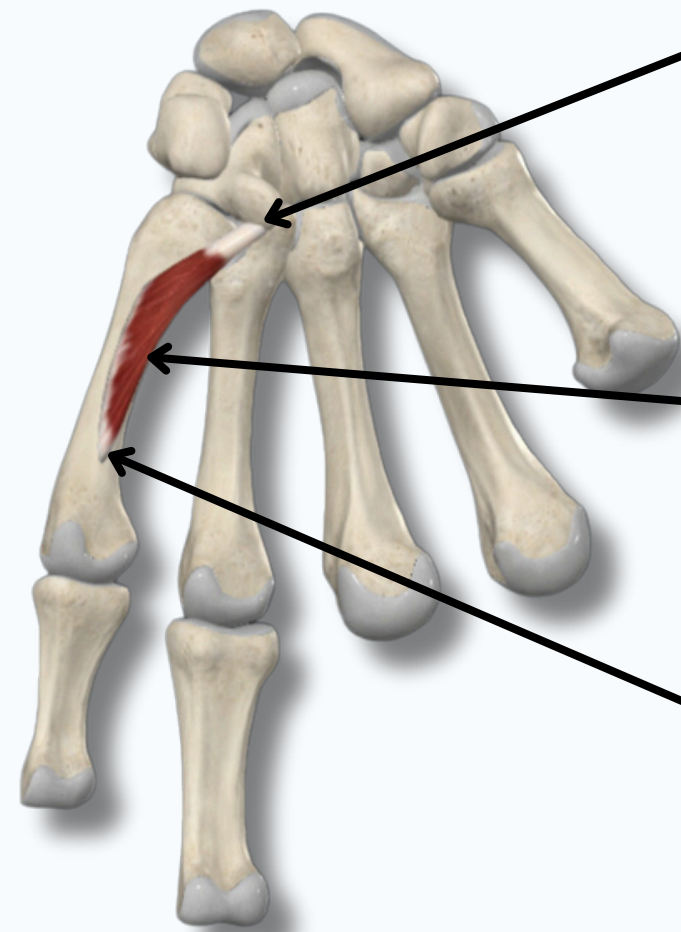


OPPONENS DIGITI MINIMI

Origin : Hook of Hamate Bone And Flexor Retinaculum of **Hand**

Opponens Digiti Minimi

Insertion : Medial Aspect of Fifth Metacarpal Bone



Anterior View

THANK YOU

EDITED BY



SATURN
MEDIC



ARECH

© ALL COPYRIGHT ARE RESERVED FOR
SATURN MEDIC AND ARECH

WWW.SATURNMEDIC.COM