

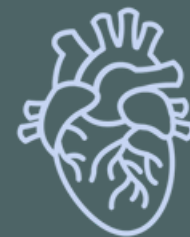ANATOMY OF UPPER LIMB

PRACTICAL LECTURE - 4 - OSTEOLOGY / PART 4 ULNA AND RADIUS

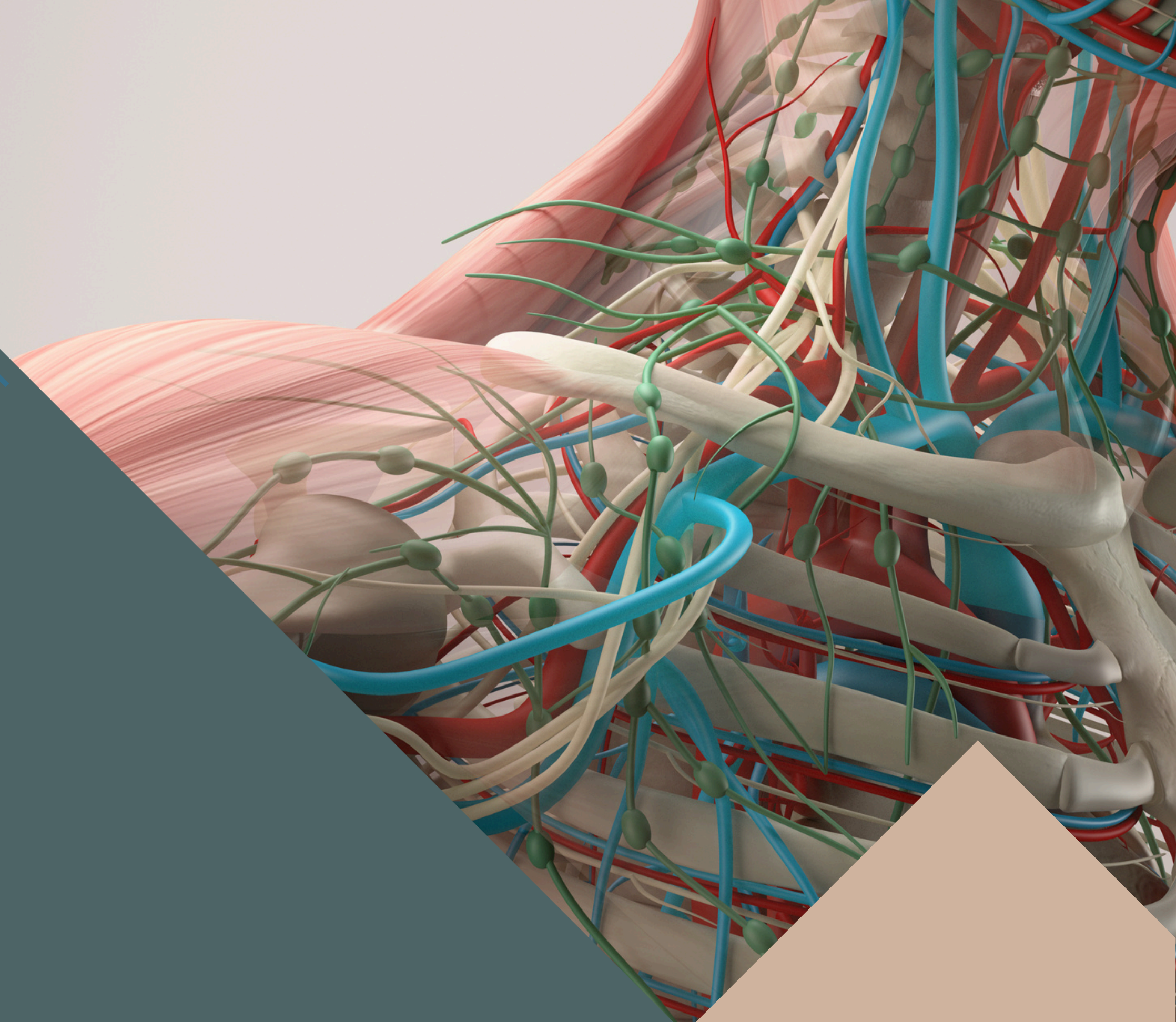
EDITED BY



SATURN
MEDIC



ARECH



ALL COPYRIGHT ARE RESERVED FOR
SATURN MEDIC AND ARECH

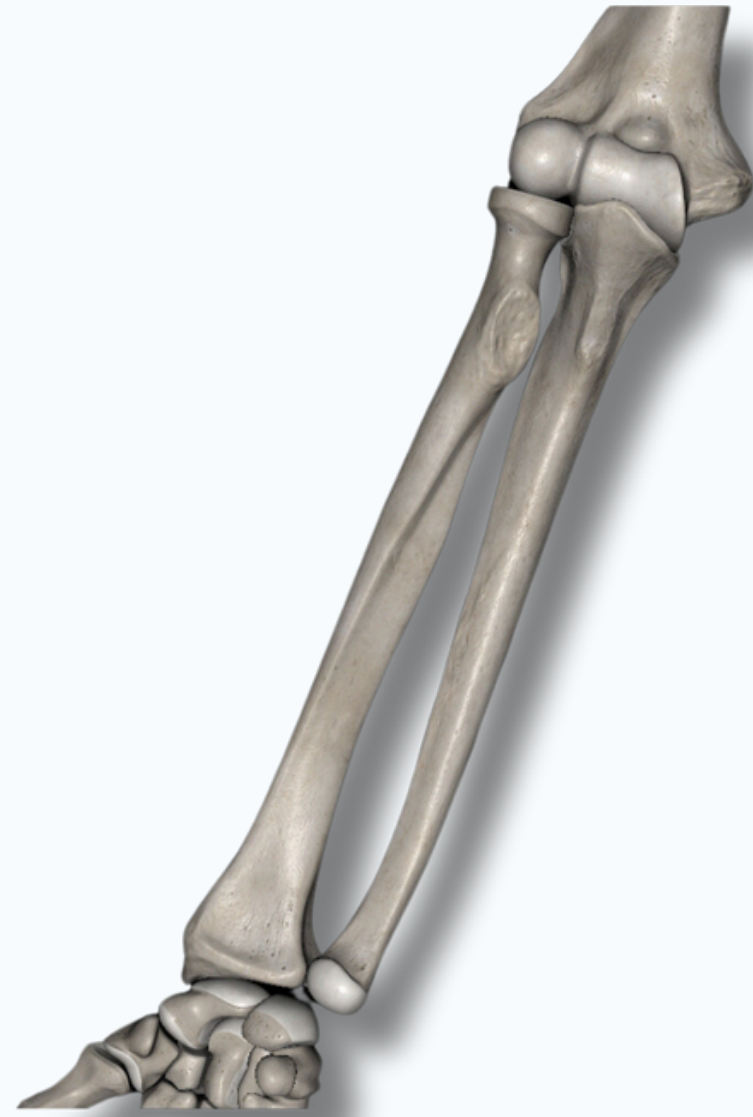WWW.SATURNMEDIC.COM



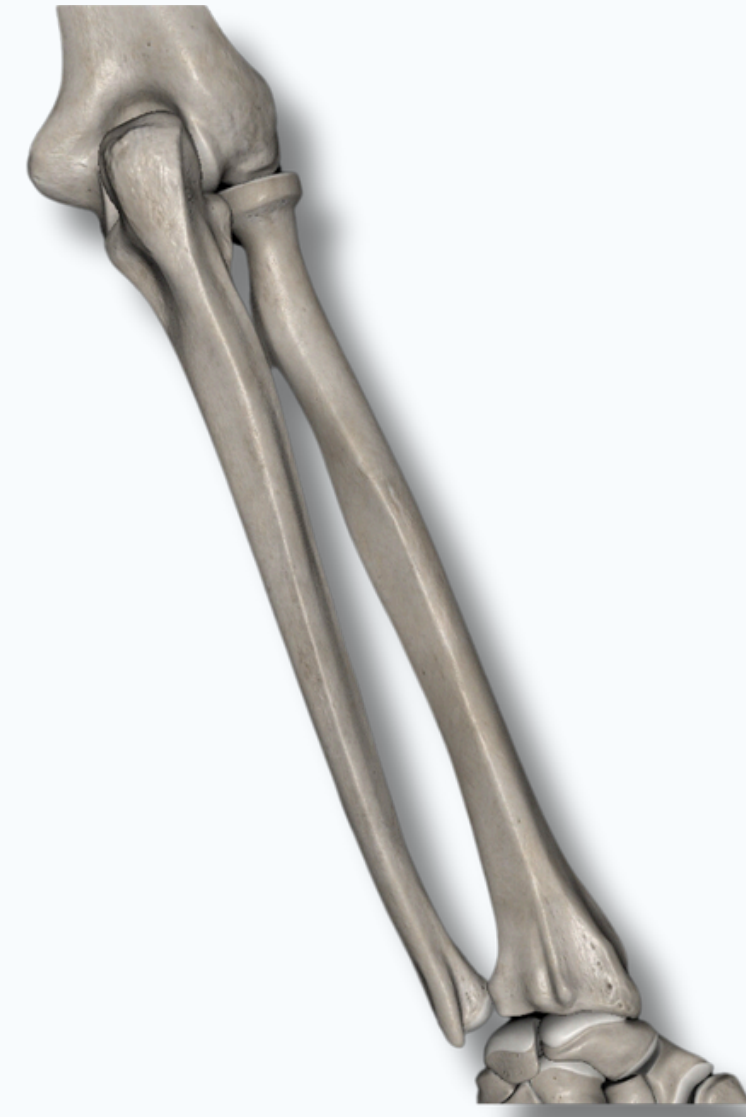OSTEOLOGY



ULNA AND RADIUS



Anterior View



Posterior View

OSTEOLOGY

ULNA



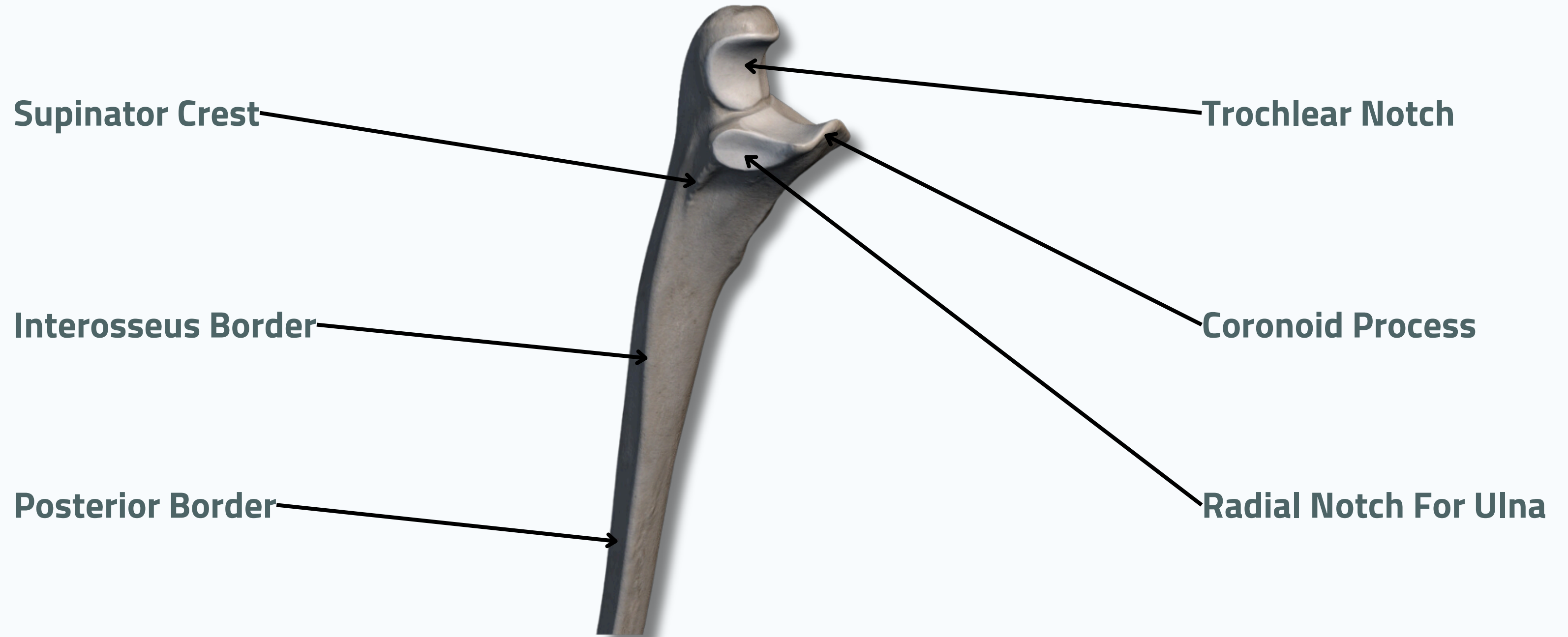
Medial View



Lateral View

OSTEOLOGY

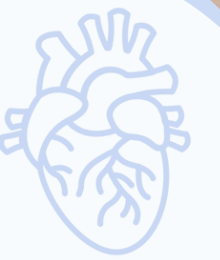ULNA



Anterior View



OSTEOLOGY



ULNA

Head of Ulna

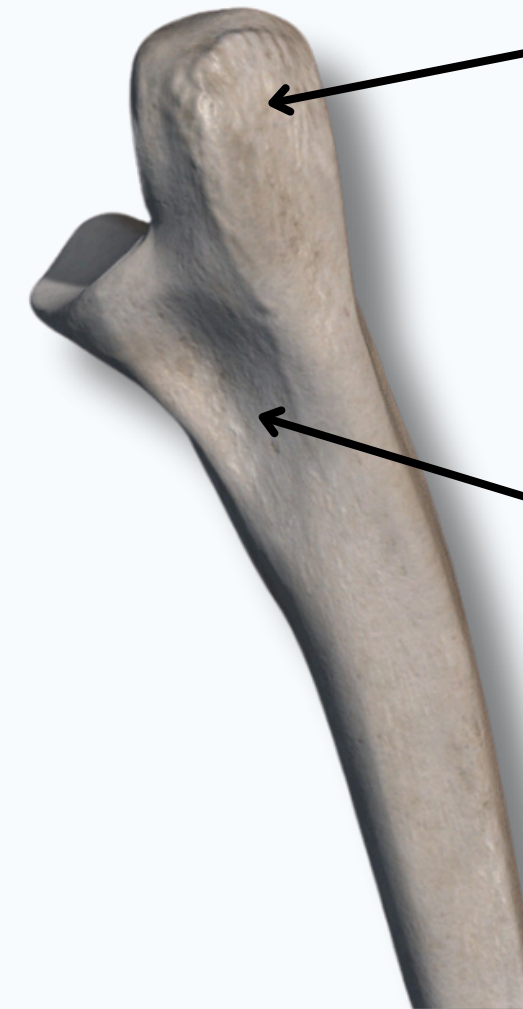


Anterior View

Articular Circumference

Styloid Process of Ulna

Olecranon

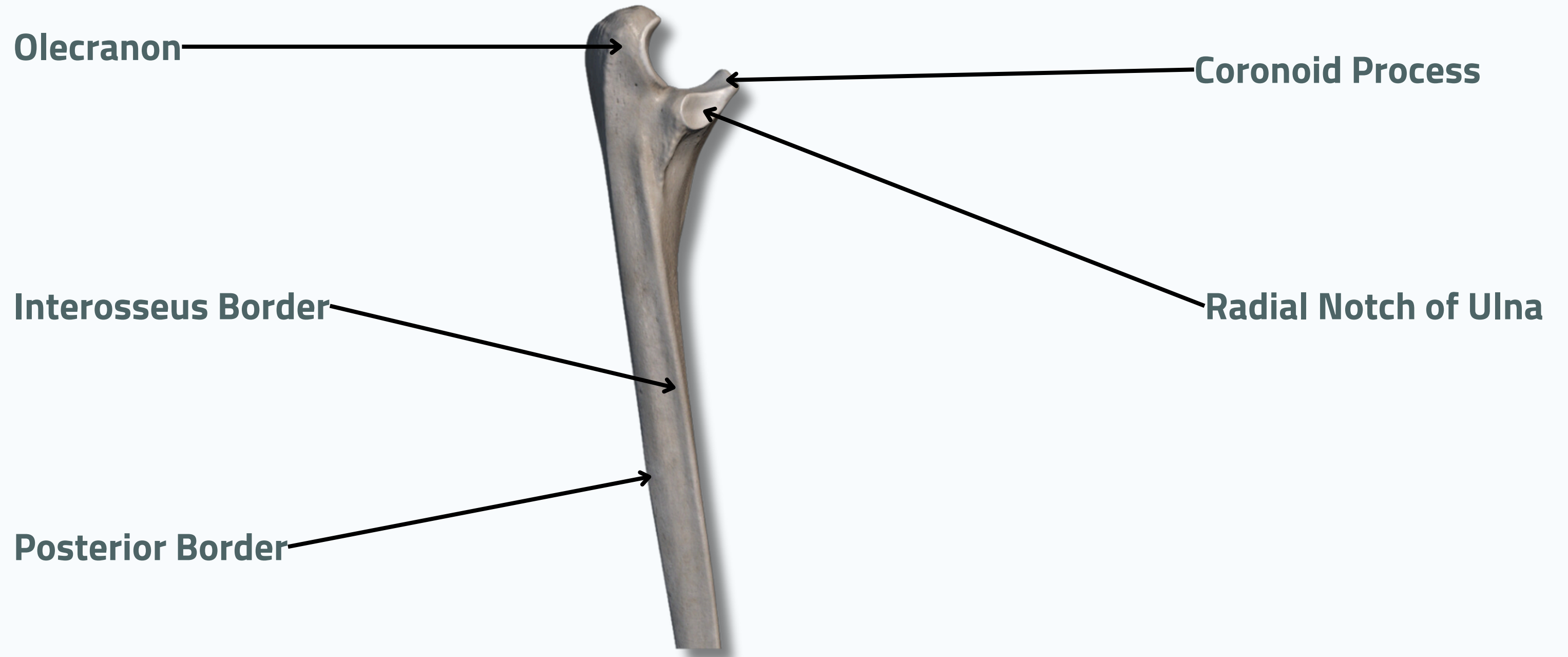


Posterior View

Ulnar Tuberosity

OSTEOLOGY

ULNA



Lateral View

OSTEOLOGY

RADIUS



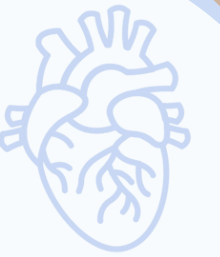Anterior View



Posterior View

OSTEOLOGY

RADIUS



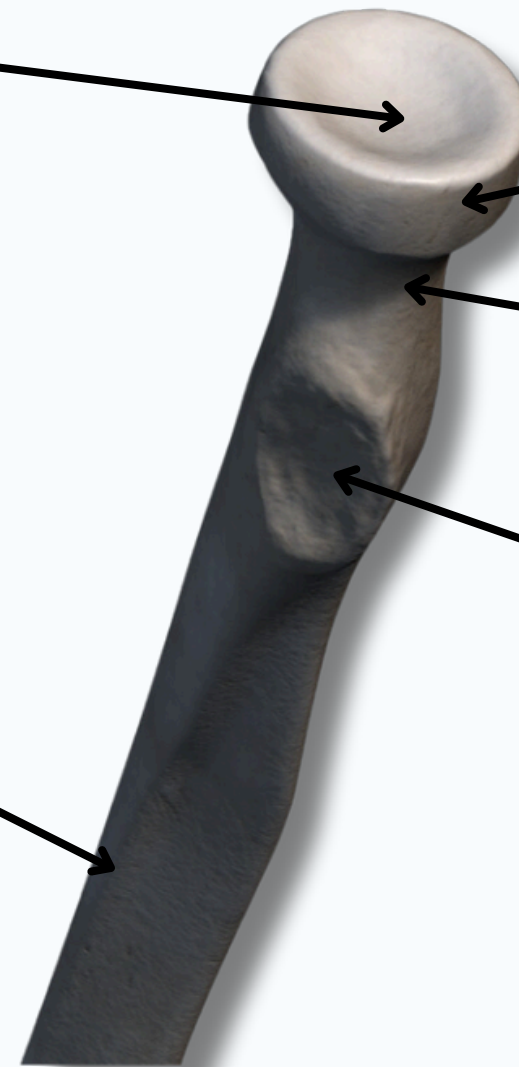
Articular Fovea

Head of Radius

Anterior Border

Neck of Radius

Radial Tuberosity



Anterior View



OSTEOLOGY



RADIUS


Styloid Process



Ulnar Notch

Anterior View

Articular Surface For Scaphoid



Articular Surface For Lunate

OSTEOLOGY

RADIUS

Head of Radius

Posterior Border

Ulnar Notch

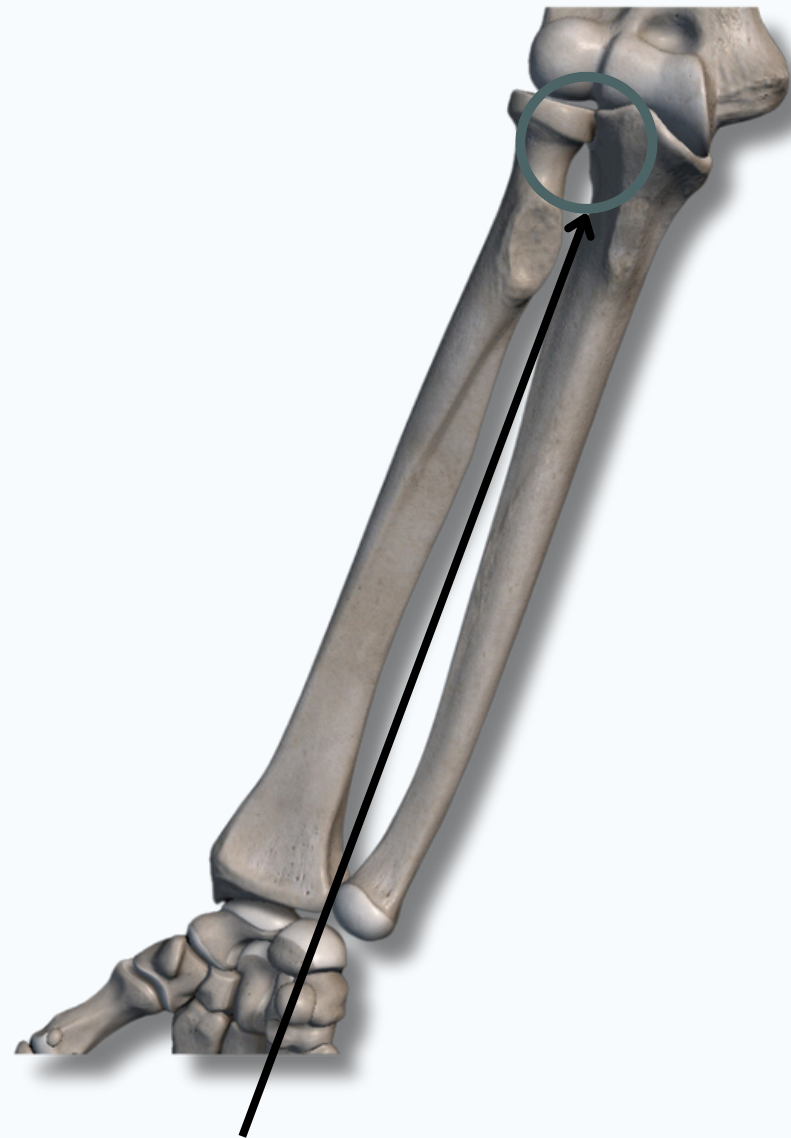Dorsal (Lister's) Tubercle

Styloid Process

Posterior View



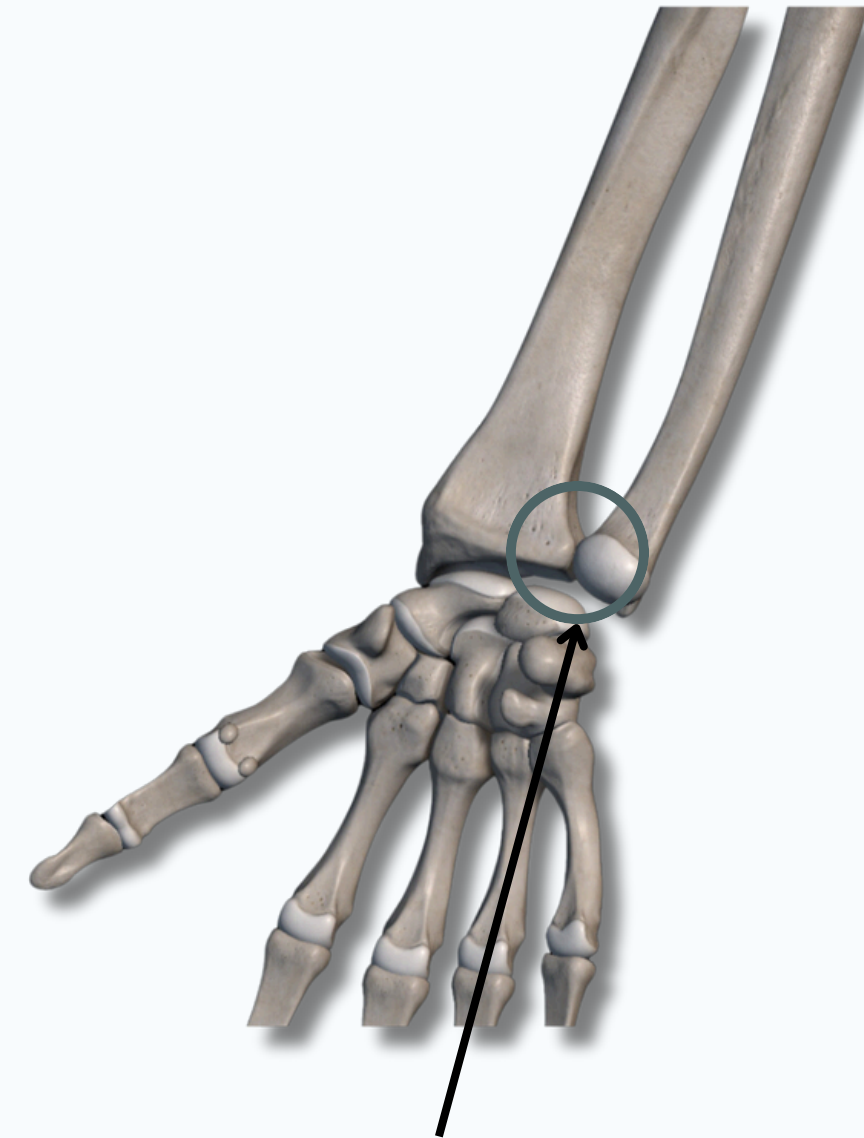
ULNA AND RADIUS



Proximal Radio-Ulnar Joint

Formed By :

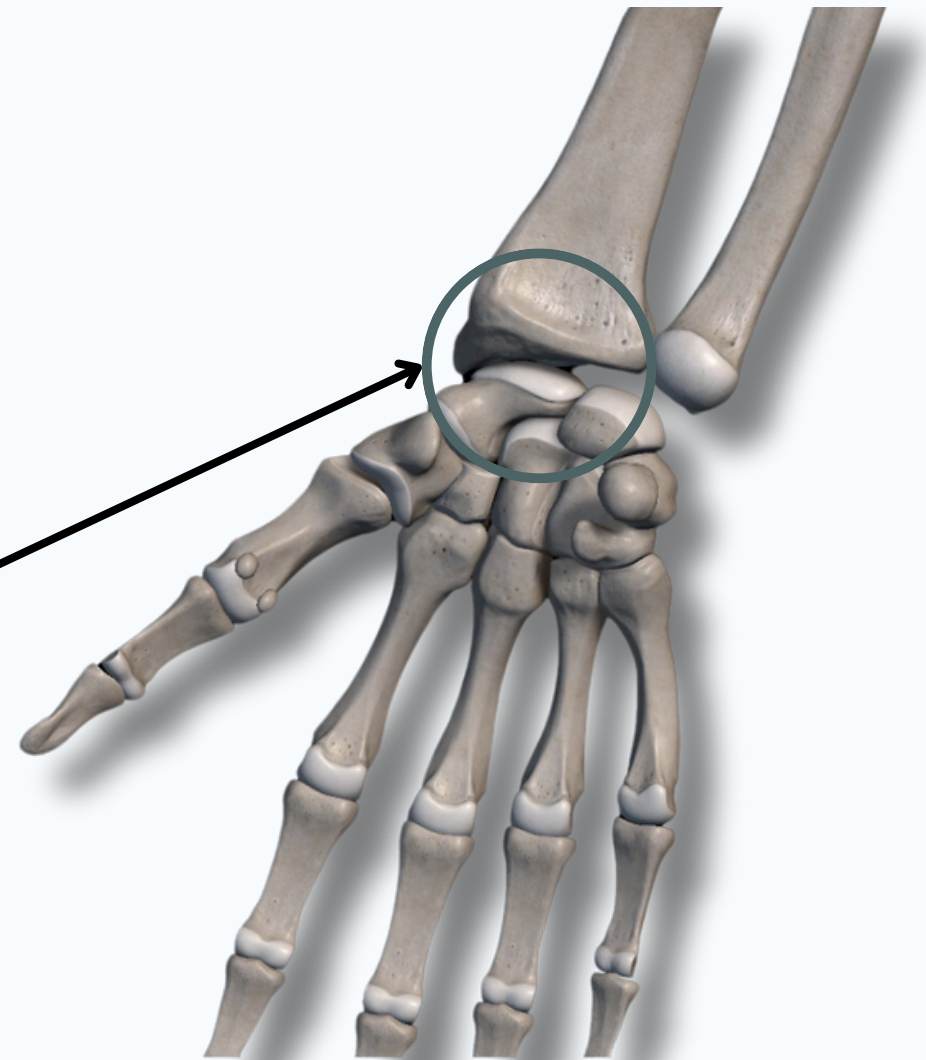
- **Head of Radius**
- Radial Notch of **Ulna**



Distal Radio-Ulnar Joint

Formed By :

- **Head of Ulna**
- Ulnar Notch of **Radius**



Wrist Joint

Formed By :

- Distal Part of **Radius**
- **Scaphoid**
- **Lunate**
- **Triquetrum**

THANK YOU

EDITED BY



SATURN
MEDIC



ARECH

© ALL COPYRIGHT ARE RESERVED FOR
SATURN MEDIC AND ARECH

WWW.SATURNMEDIC.COM