

# ANATOMY OF UPPER LIMB

## PRACTICAL LECTURE - 5 - OSTEOLOGY / PART 5 HAND

EDITED BY



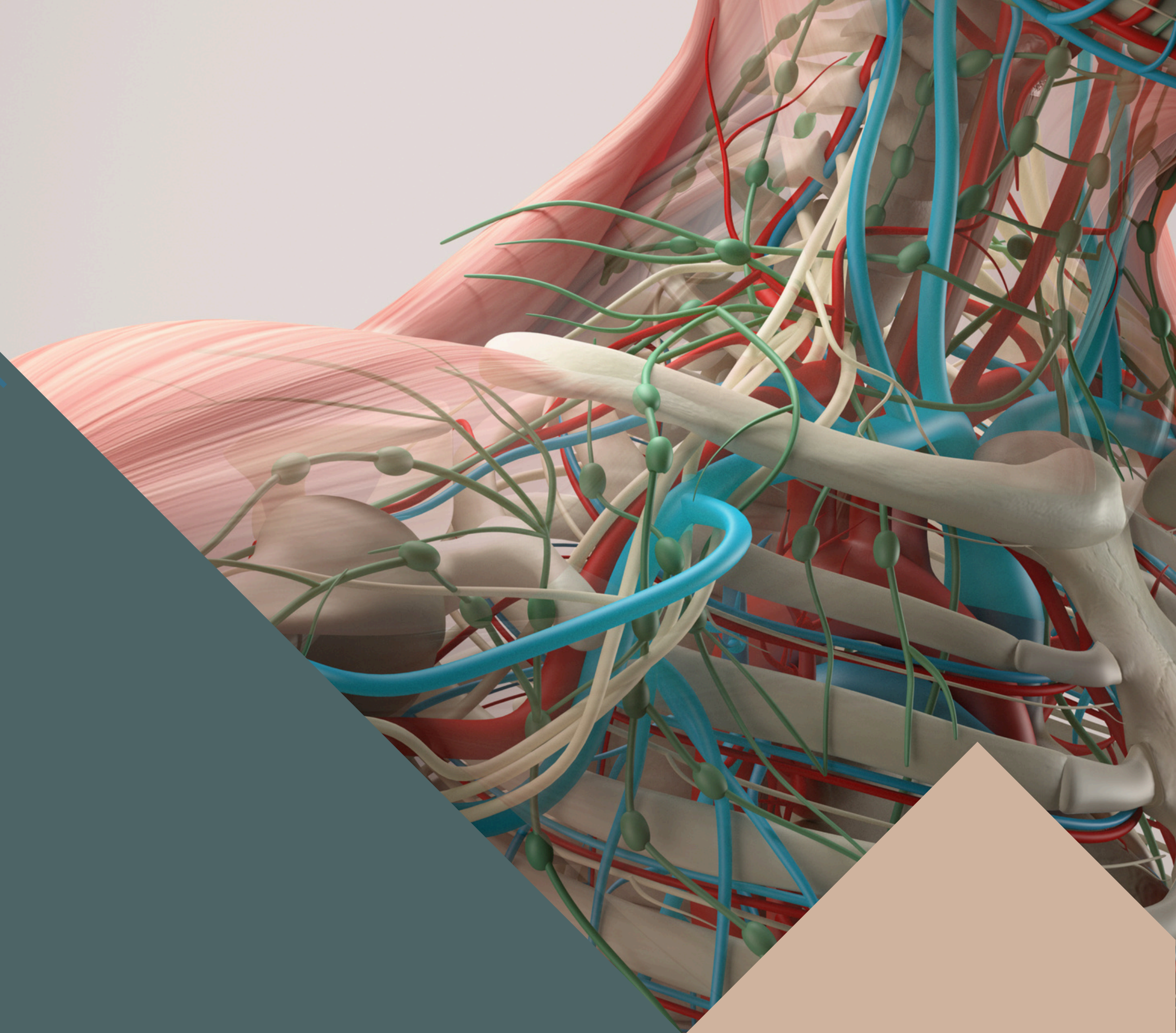
SATURN  
MEDIC



ARECH

© ALL COPYRIGHT ARE RESERVED FOR  
SATURN MEDIC AND ARECH

[WWW.SATURNMEDIC.COM](http://WWW.SATURNMEDIC.COM)

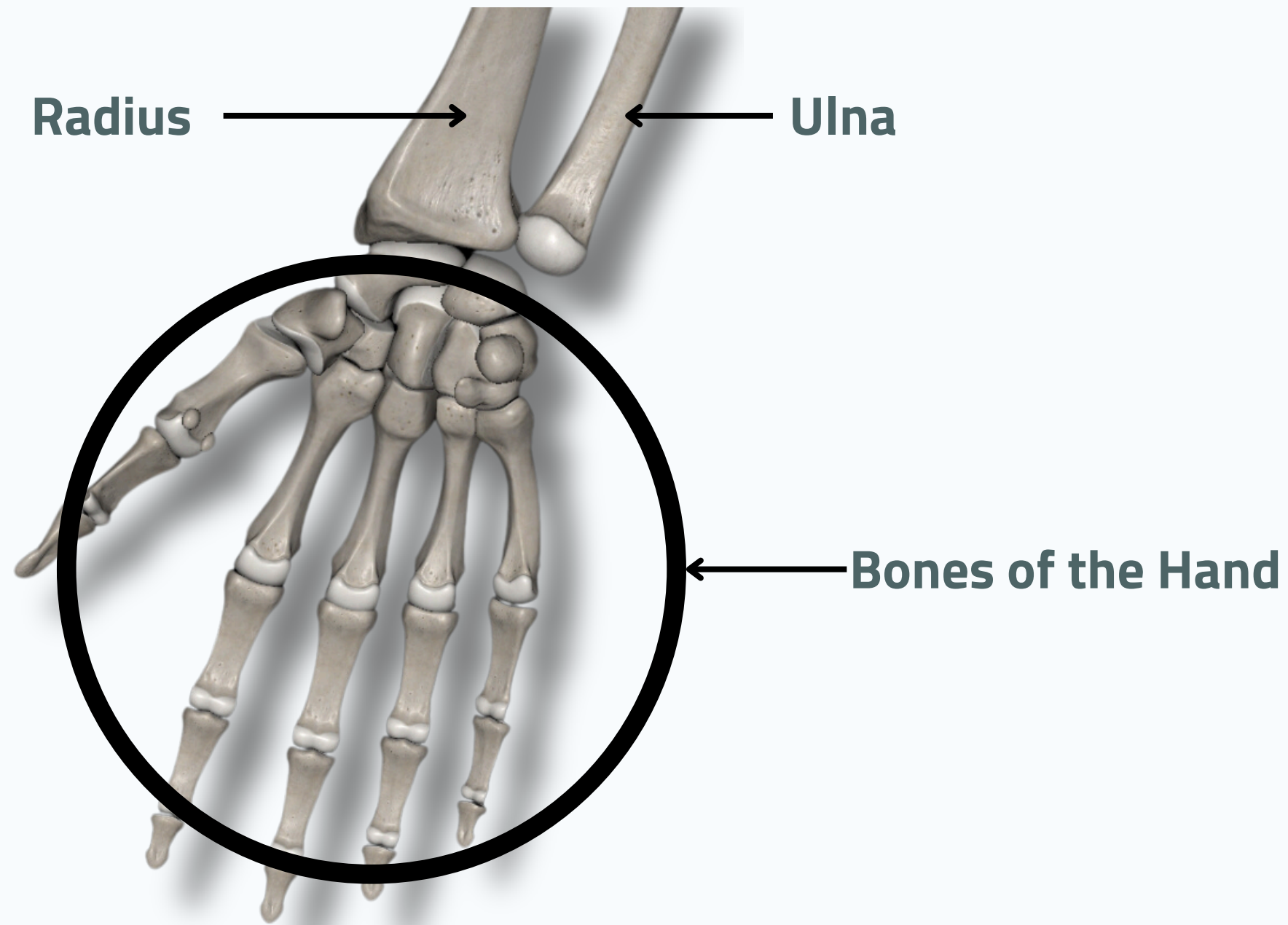




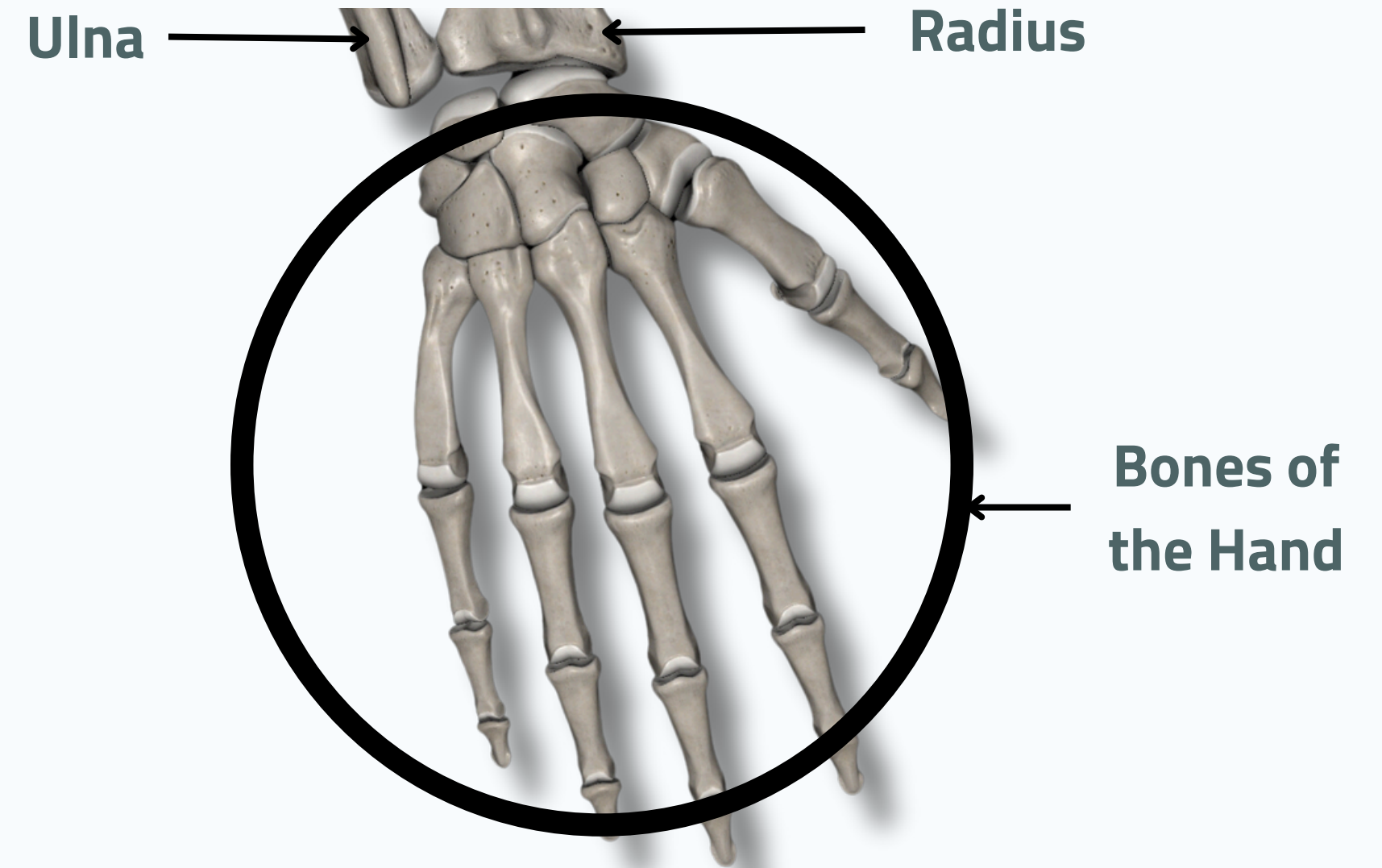
# OSTEOLOGY



## HAND



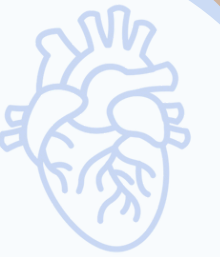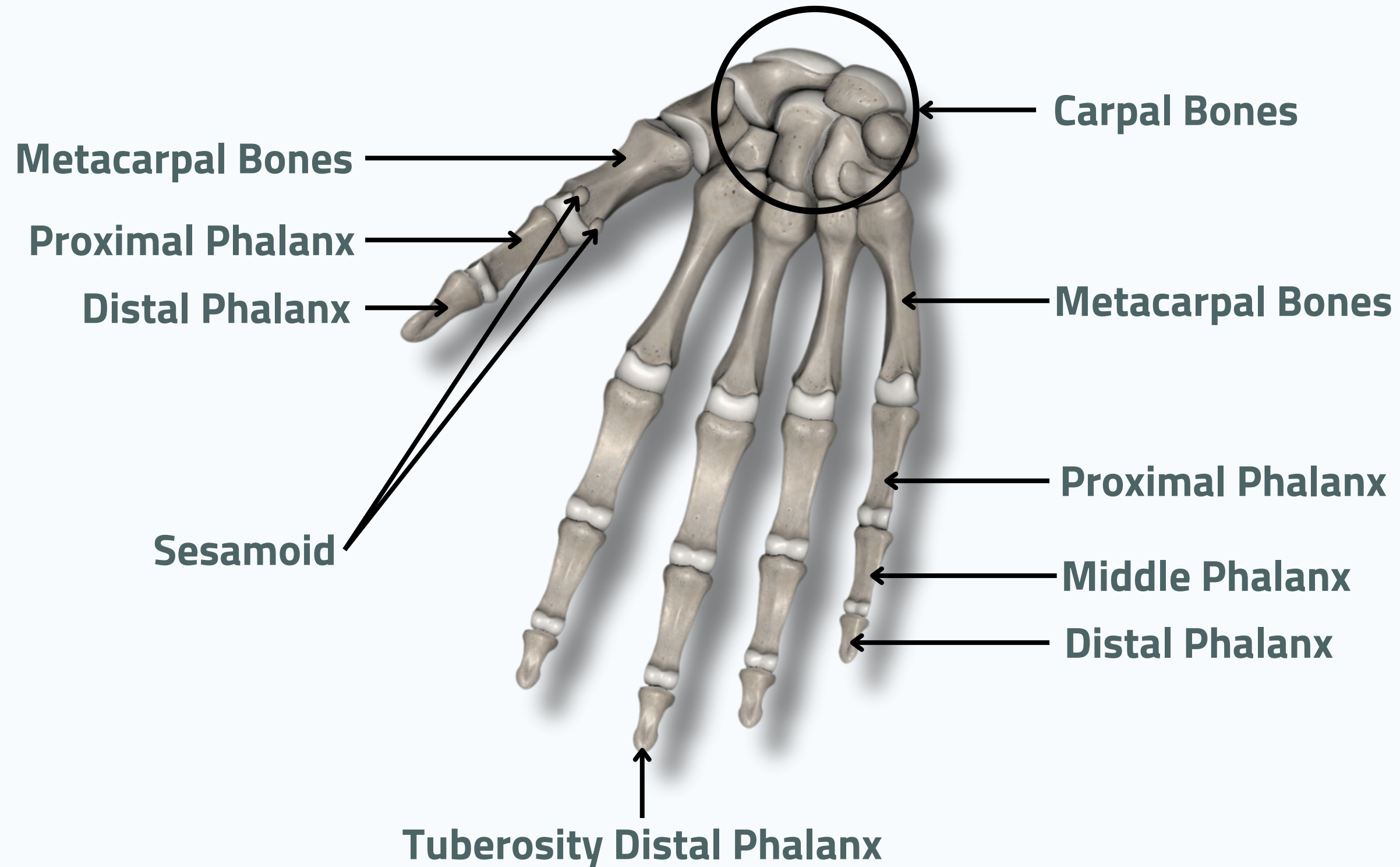
**Anterior View**



**Posterior View**

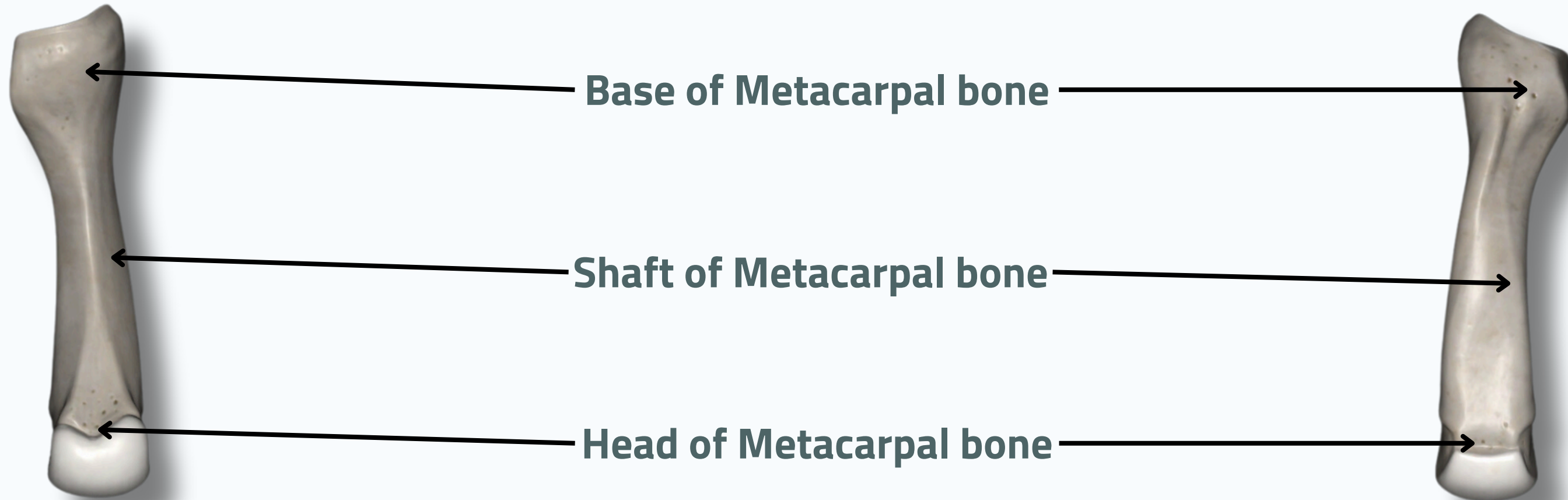
# OSTEOLOGY

## HAND





### Metacarpal bone



**Anterior View**

**Posterior View**

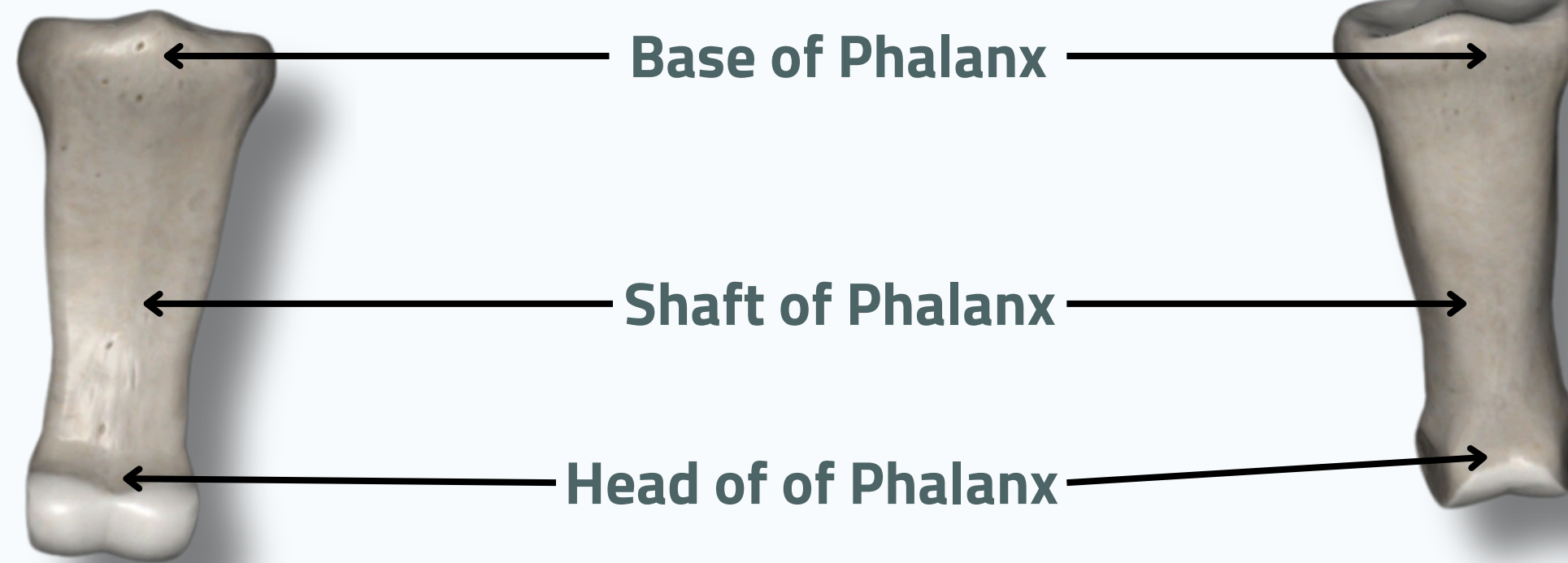


# OSTEOLOGY

## HAND



### Phalanx

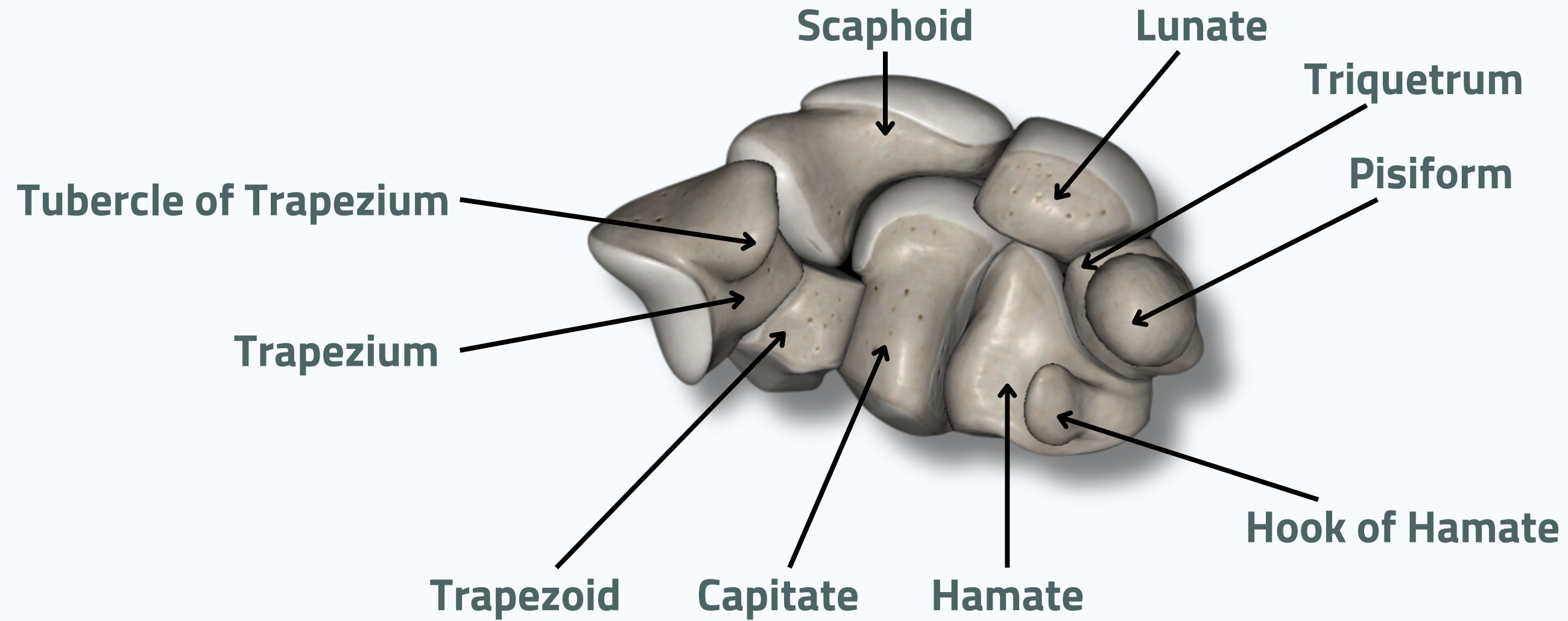


**Anterior View**

**Posterior View**

# OSTEOLOGY

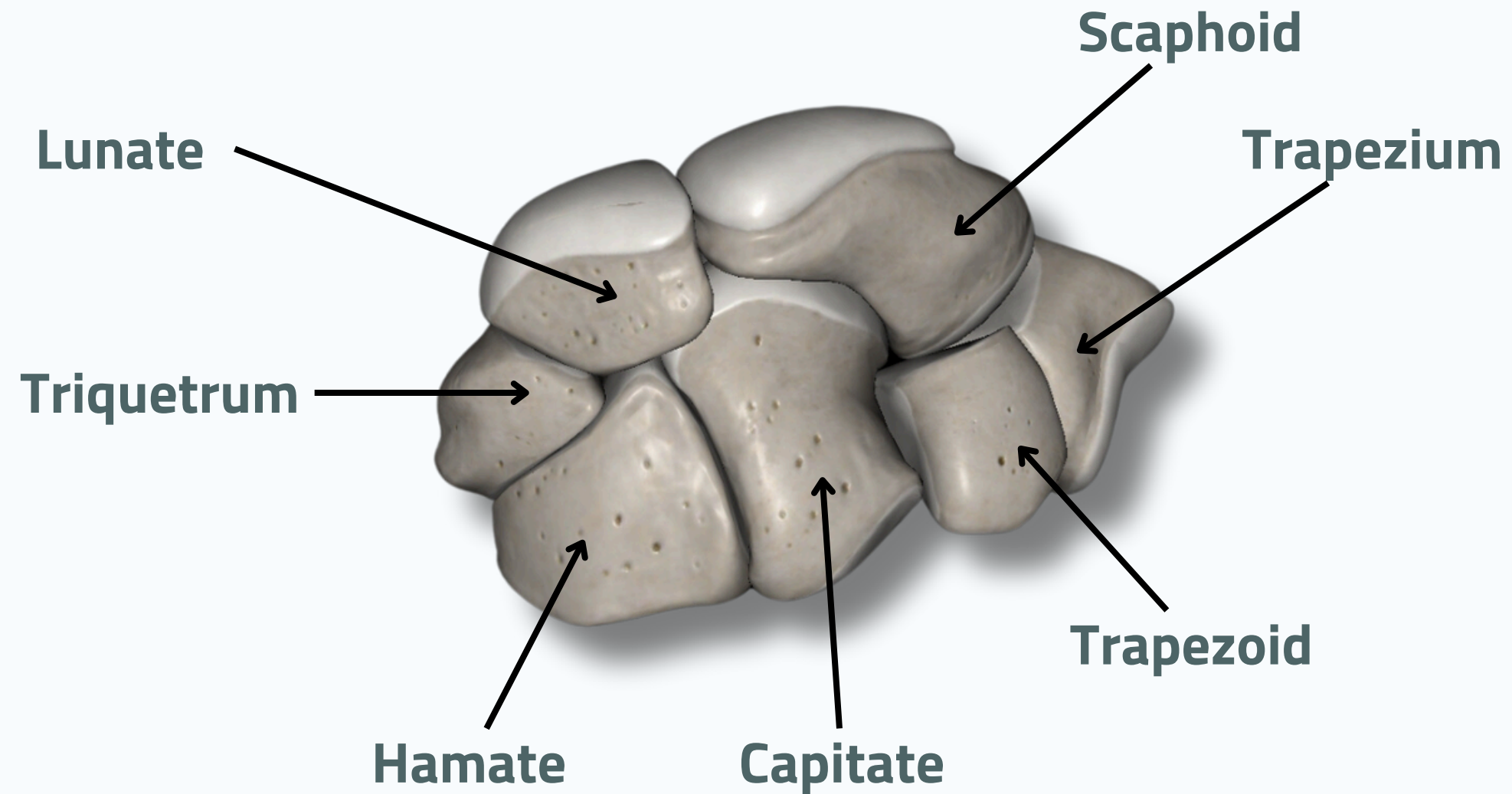
## HAND



**Anterior View**

# OSTEOLOGY

## HAND



**Posterior View**

# THANK YOU

EDITED BY



SATURN  
MEDIC



ARECH

© ALL COPYRIGHT ARE RESERVED FOR  
SATURN MEDIC AND ARECH

[WWW.SATURNMEDIC.COM](http://WWW.SATURNMEDIC.COM)