

ANATOMY OF UPPER LIMB

PRACTICAL LECTURE - 7 -

MUSCLES / PART 2

POSTERIR AXIO-APPENDICULAR MUSCLES

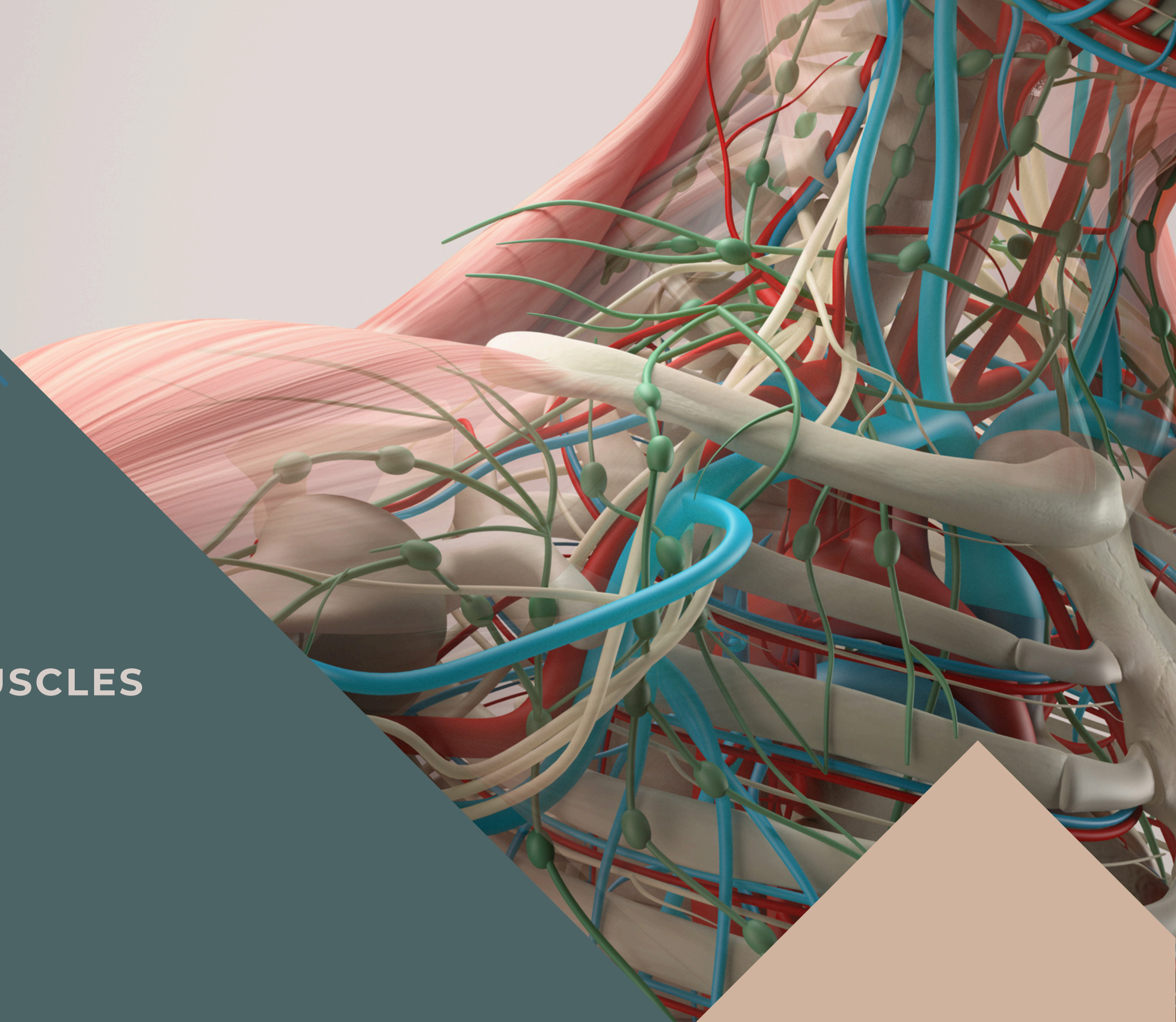
EDITED BY



SATURN
MEDIC



ARECH



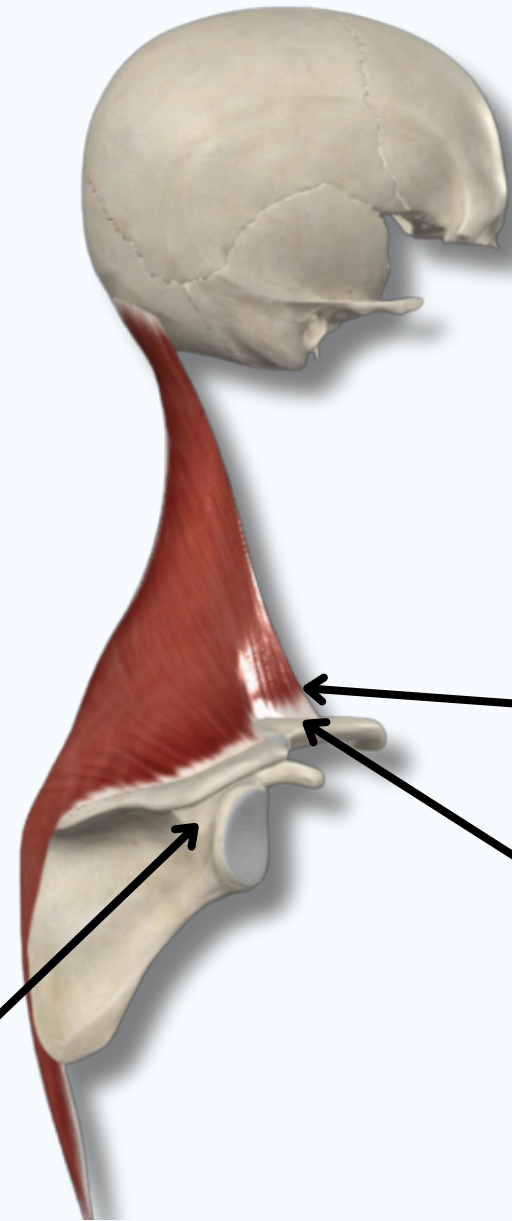
ALL COPYRIGHT ARE RESERVED FOR
SATURN MEDIC AND ARECH

WWW.SATURNMEDIC.COM

POSTERIOR AXIO-APPENDICULAR MUSCLES

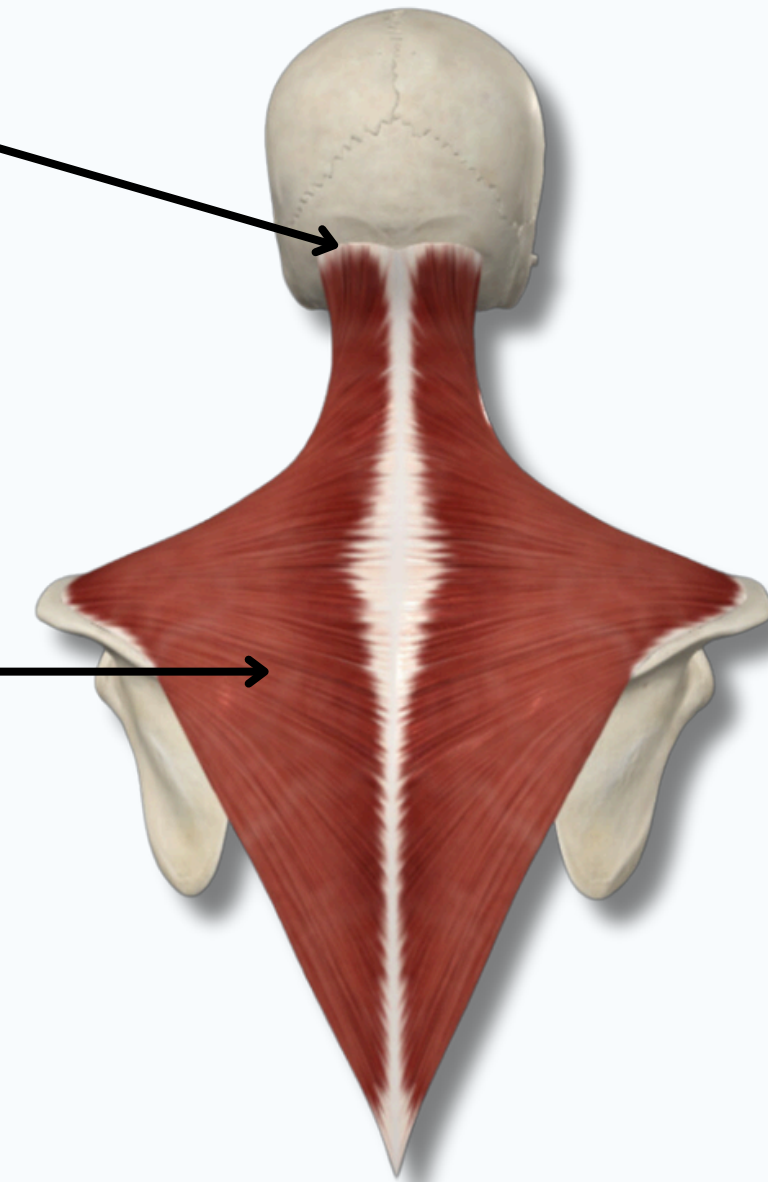
TRAPEZIUS MUSCLE

Origin : Medial 1/3 of Superior Nuchal Line



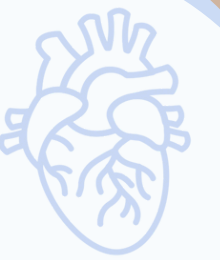Insertion : Spine of The Scapula

Lateral View



Insertion : Lateral 1/3 of The Clavicle

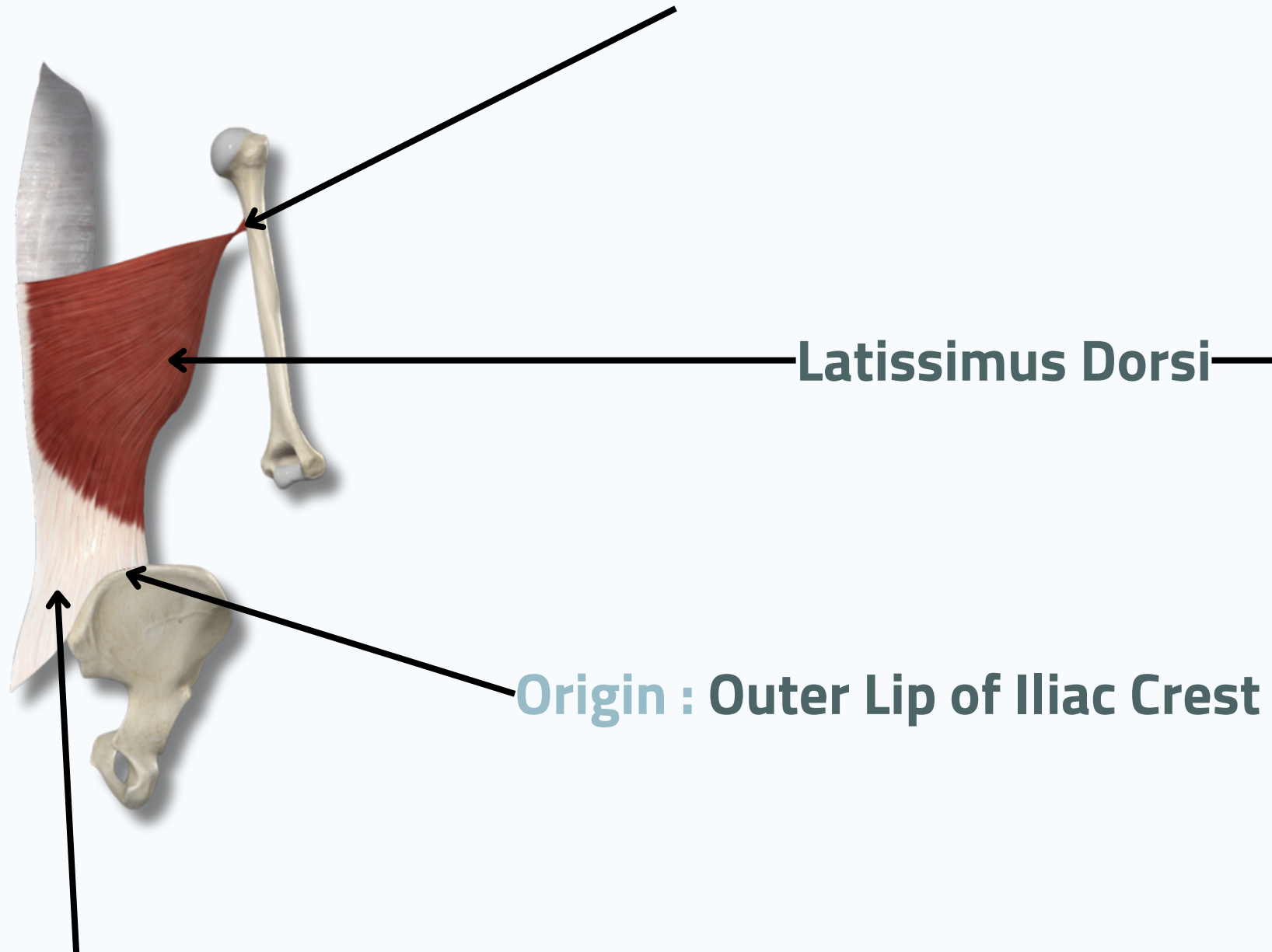
Posterior View



POSTERIOR AXIO-APPENDICULAR MUSCLES

LATISSIMUS DORSI

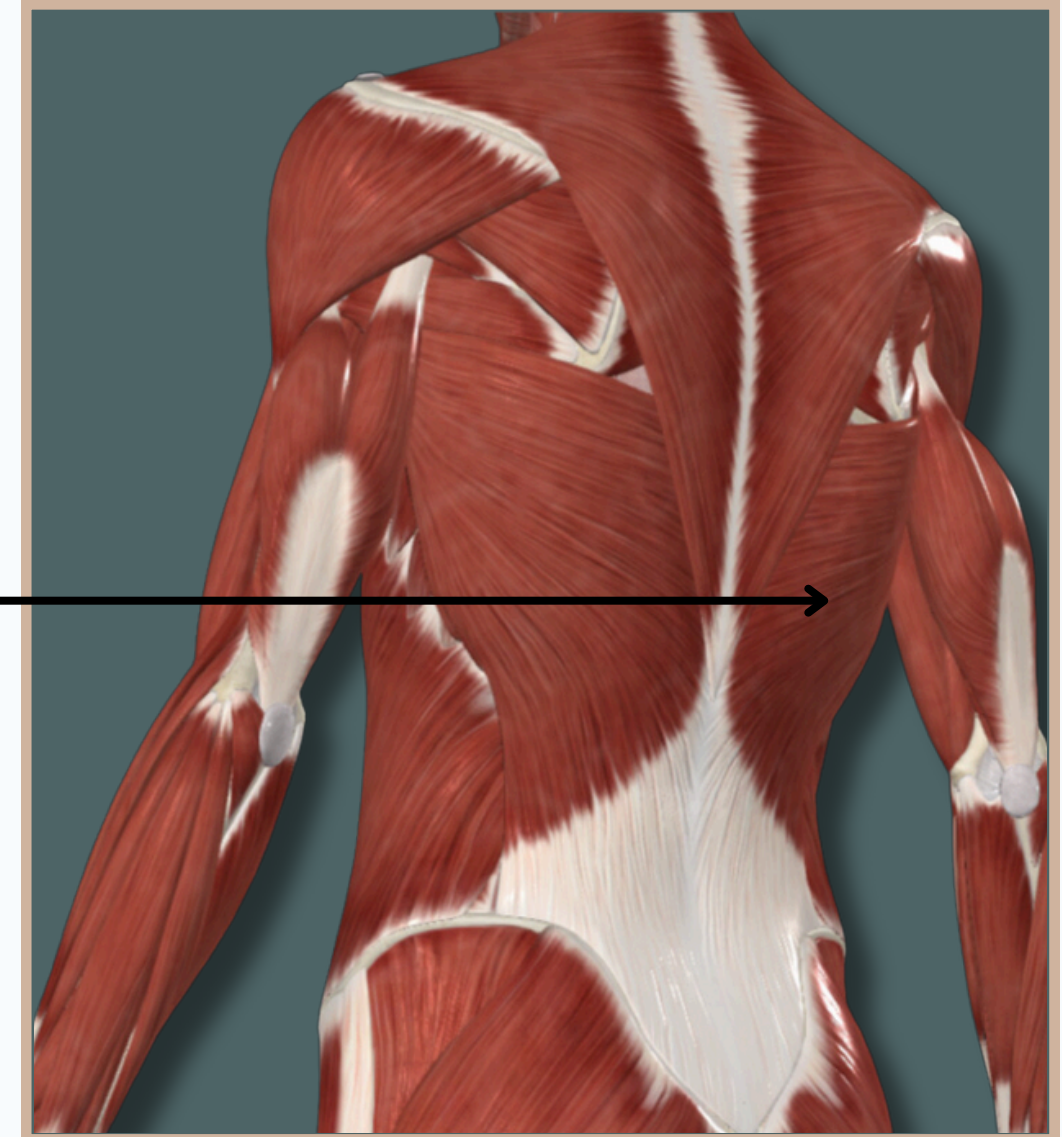
Insertion : Floor of Intertubercular Sulcus



Latissimus Dorsi

Origin : Outer Lip of Iliac Crest

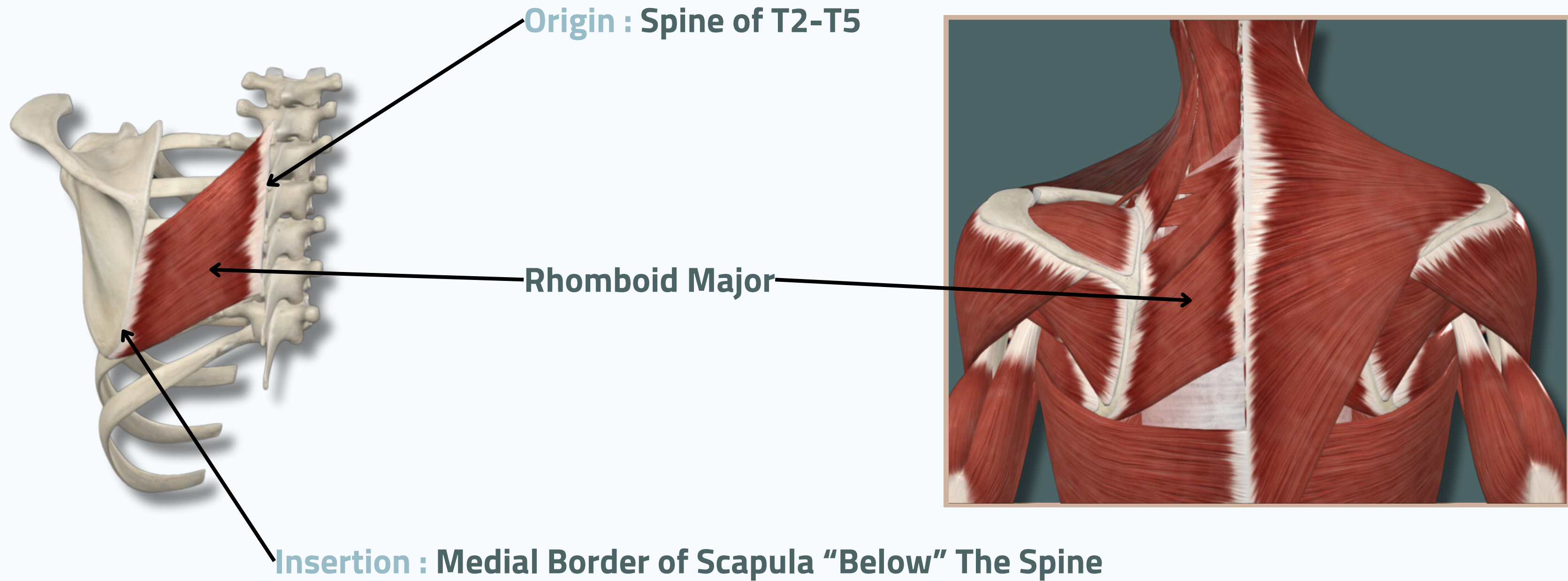
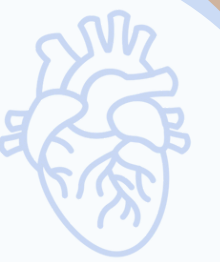Origin : Thoraco-Lumbar Fascia



Posterior View

POSTERIOR AXIO-APPENDICULAR MUSCLES

RHOMBOID MAJOR



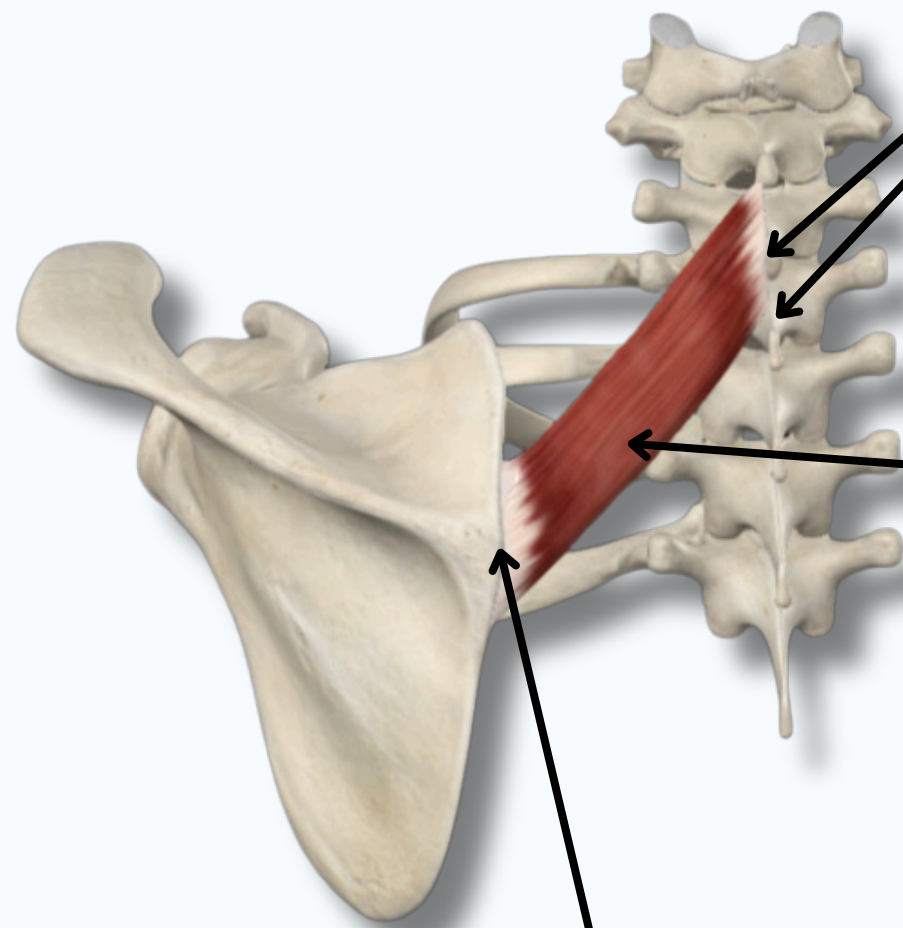
Posterior View

POSTERIR AXIO-APPENDICULAR MUSCLES

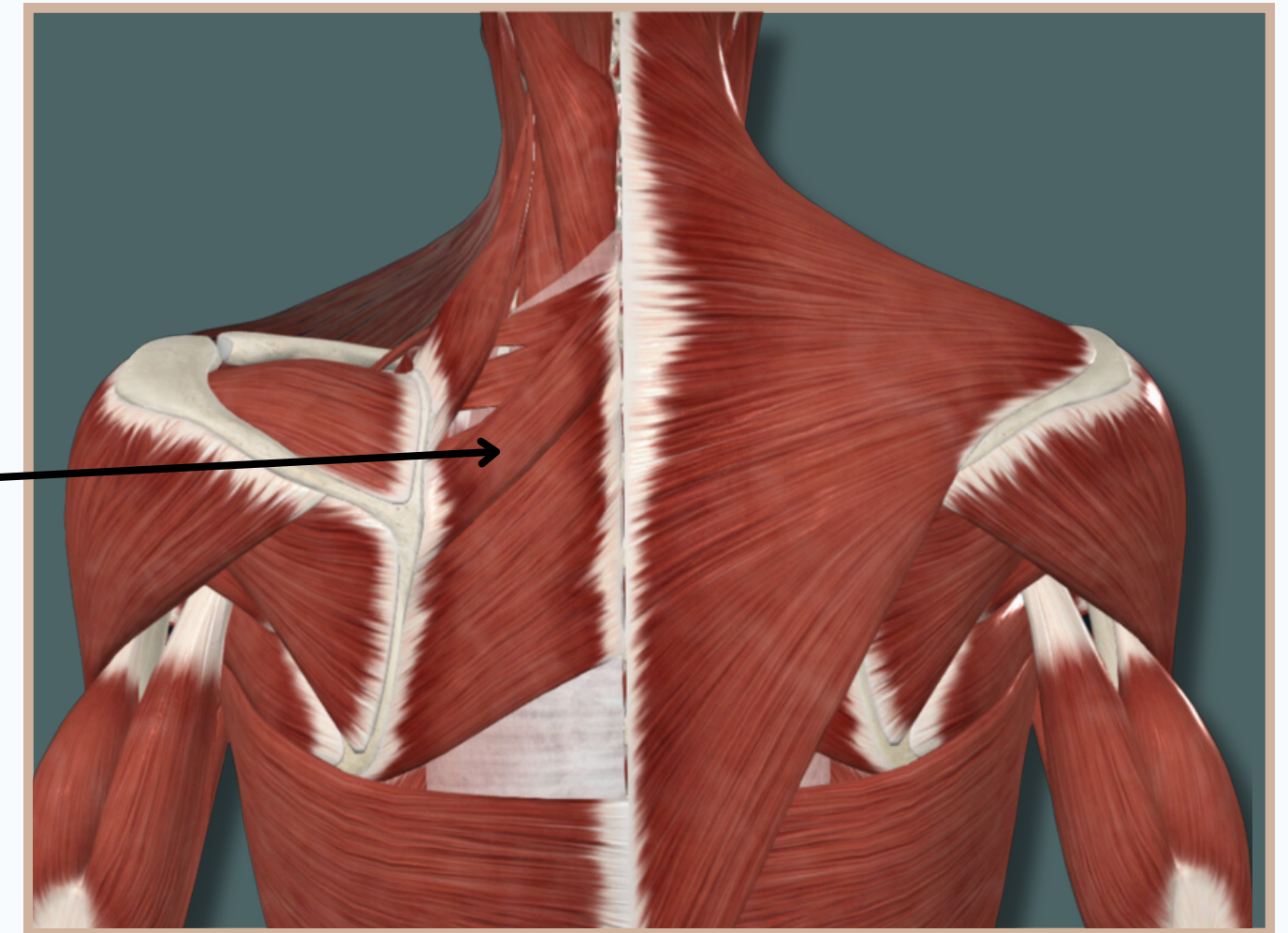
RHOMBOID MINOR



Origin : Spine of C7-T1



Rhomboid Minor



Insertion : Medial Border of Scapula "Opposite" The Spine

Posterior View

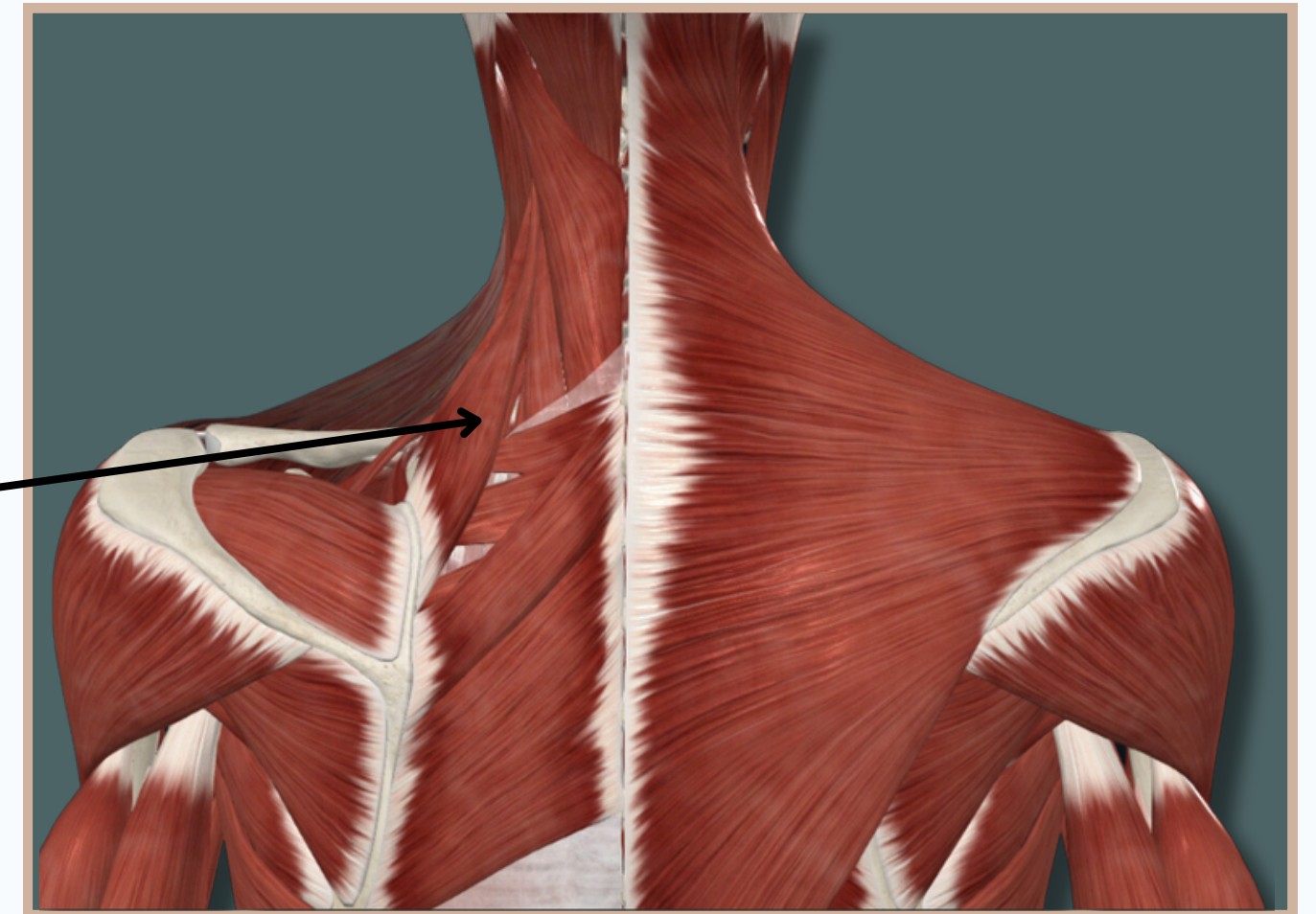
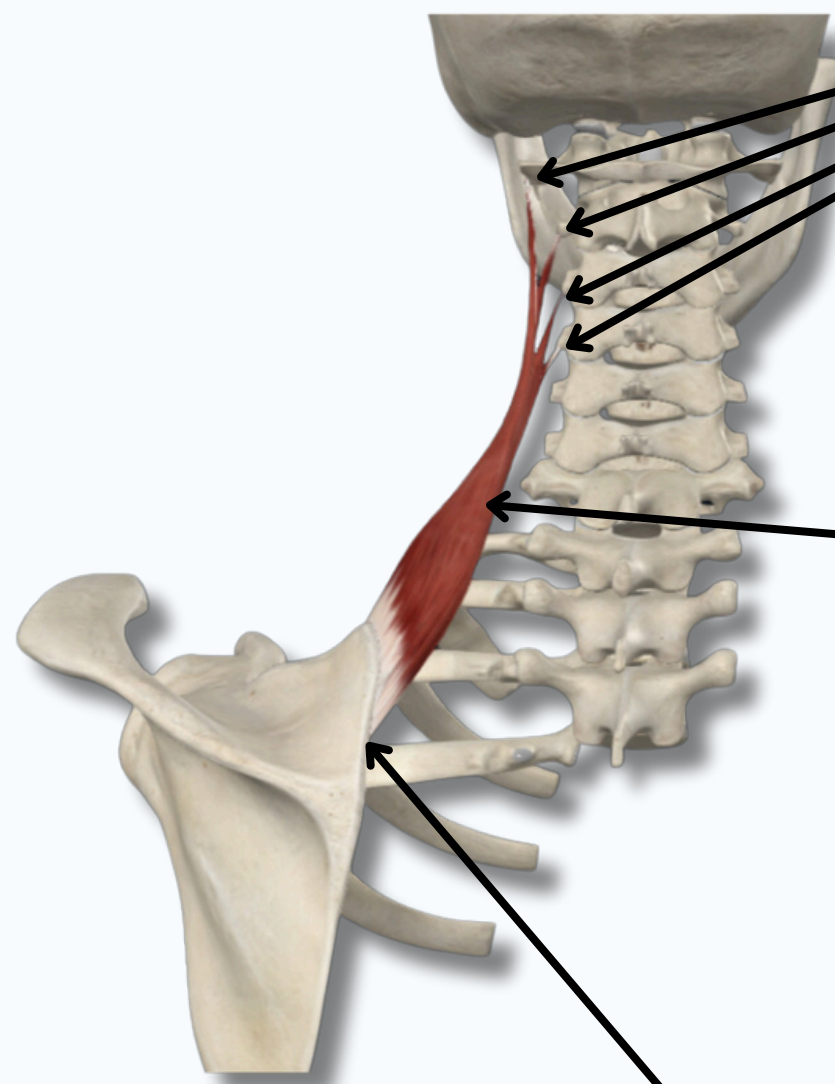
POSTERIR AXIO-APPENDICULAR MUSCLES

LEVATOR SCAPULAE

Origin : Spine of C1-T4

Levator Scapulae

Insertion : Medial Border of Scapula "Above" The Spine



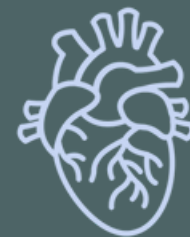Posterior View

THANK YOU

EDITED BY



SATURN
MEDIC



ARECH

© ALL COPYRIGHT ARE RESERVED FOR
SATURN MEDIC AND ARECH

WWW.SATURNMEDIC.COM