

ANATOMY OF LOWER LIMB

PRACTICAL LECTURE - 5 -

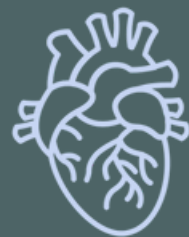MUSCLES / PART 1

ANTERIOR EXTENSOR MUSCLES OF THE THIGH

EDITED BY



SATURN
MEDIC

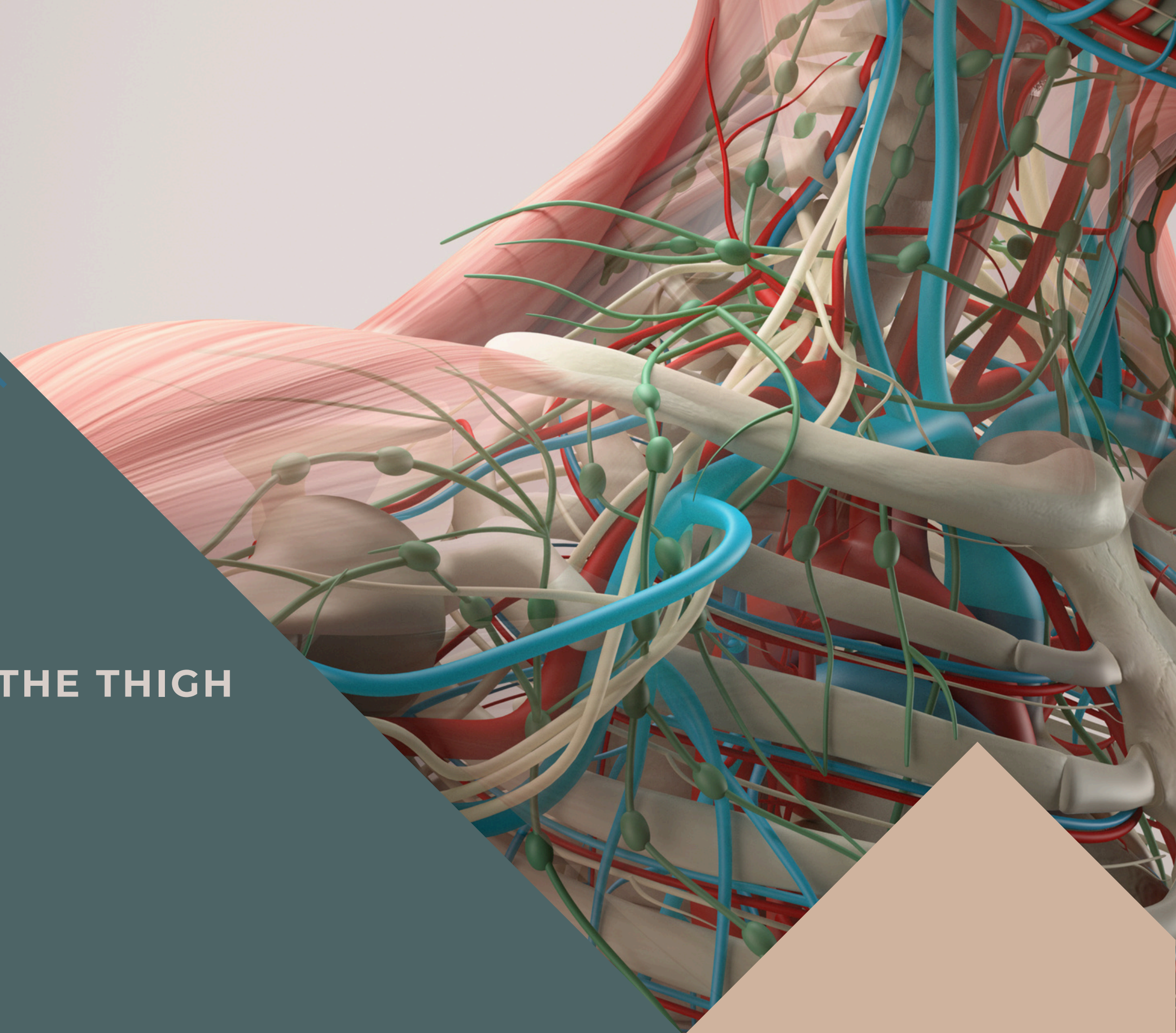


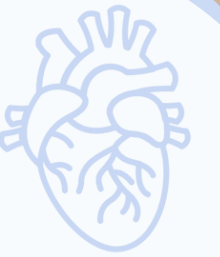ARECH



ALL COPYRIGHT ARE RESERVED FOR
SATURN MEDIC AND ARECH

WWW.SATURNMEDIC.COM

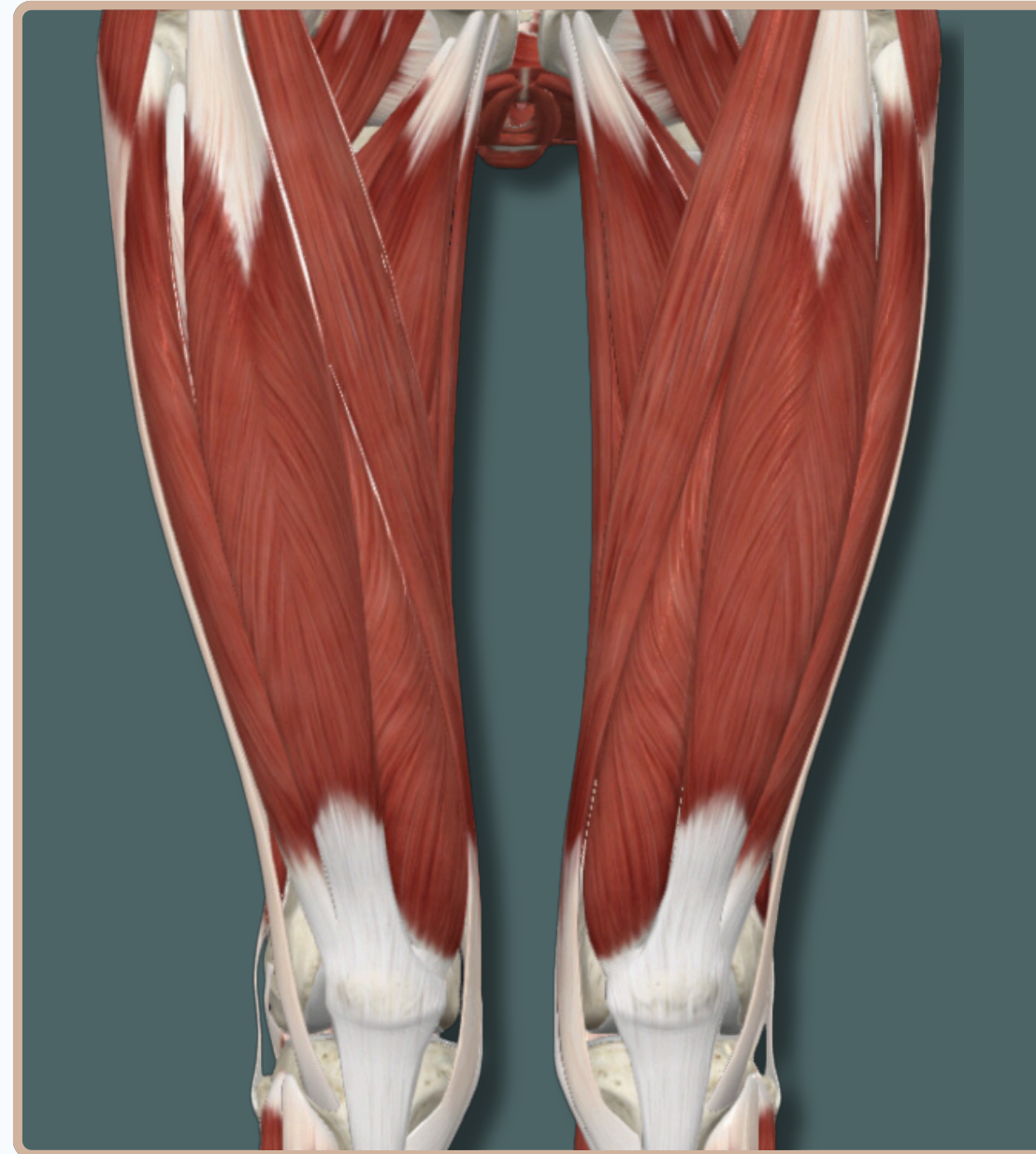



-All The Muscles of The **Anterior Compartment of The Thigh** Are Responsible For :

- **Knee** Extension
- **Hip** Flexion

-All The Muscles of The **Anterior Compartment of The Thigh** Are Supplied By **Femoral Nerve**



Anterior View

ANTERIOR EXTENSOR MUSCLES OF THE THIGH

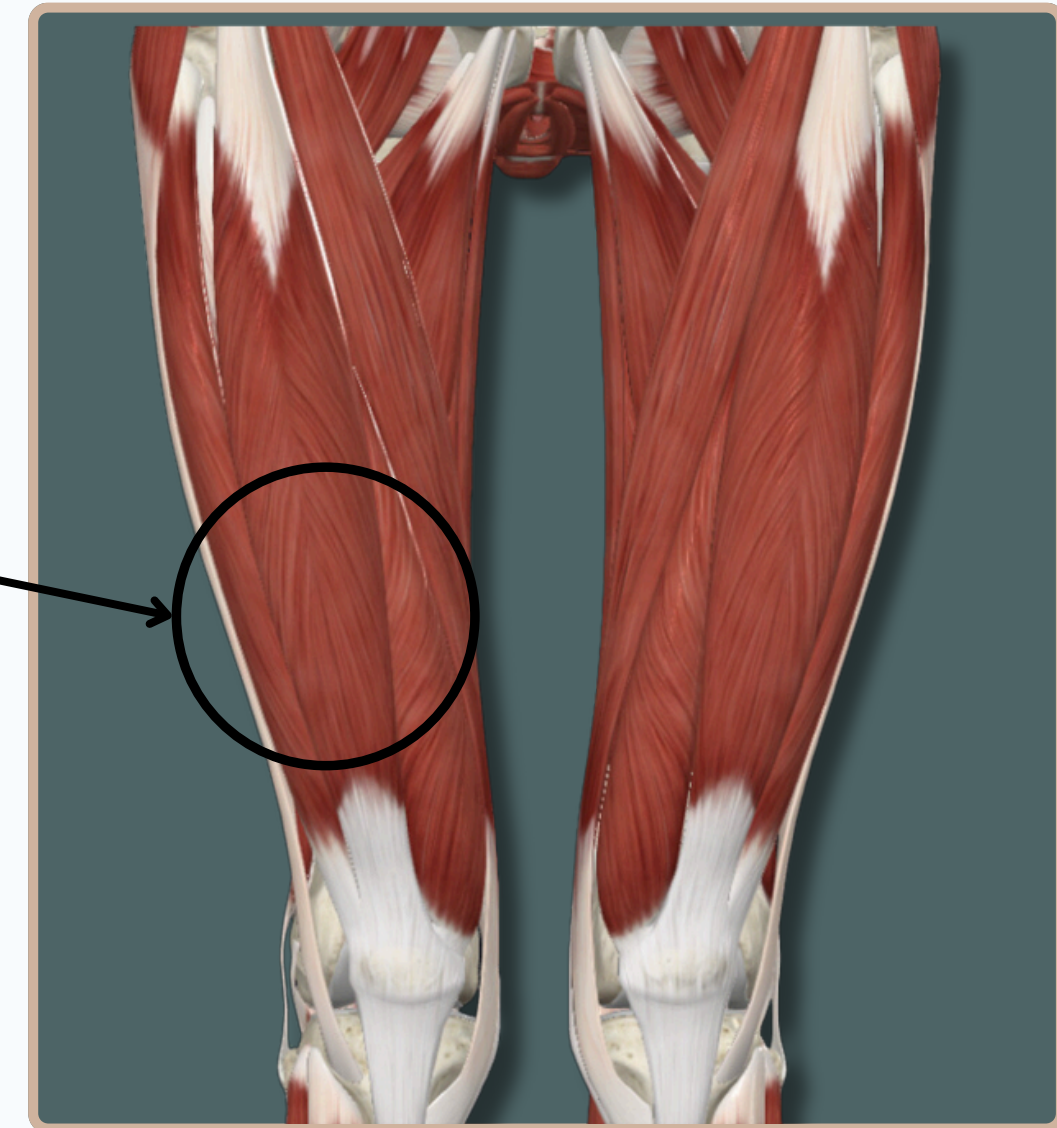
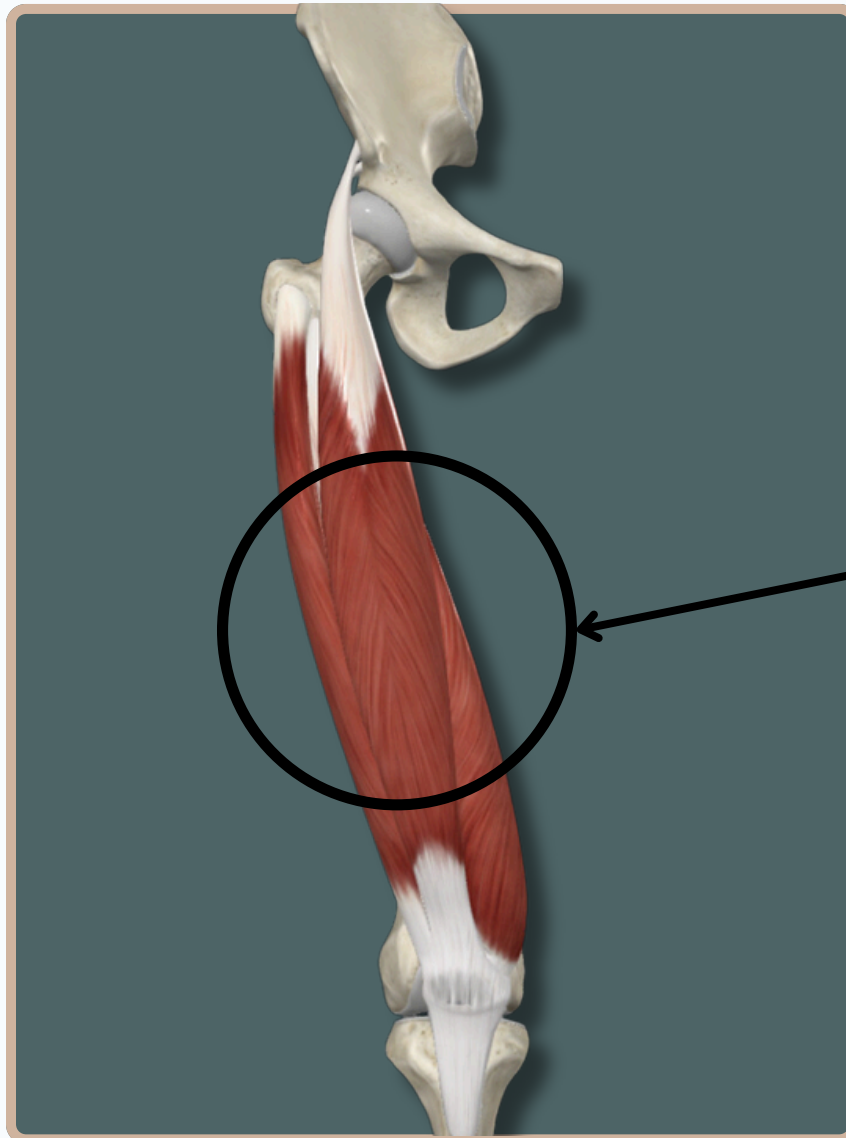
QUADRECIEPS FEMORIS

Quadriceps femoris

A Group of Muscles In The Anterior Compartment of The Thigh

Which Are :

- Rectus Femoris
- Vastus Medialis
- Vastus Lateralis
- Vastus Intermedius (Deep to Rectus Femoris)



Anterior View

ANTERIOR EXTENSOR MUSCLES OF THE THIGH

QUADRECIEPS FEMORIS

Origin : -Anterior inferior **iliac spine**
-Supraacetabular groove of **ilium**

Rectus Femoris

Insertion : **Tibial tuberosity**, via tendon of quadriceps femoris muscle and patellar ligament

Action :

- Extends** leg at **knee** joint
- Flexes** thigh at **hip** joint

Anterior View

Nerve Supply :
Femoral Nerve

ANTERIOR EXTENSOR MUSCLES OF THE THIGH

QUADRECIEPS FEMORIS

Origin : Medial part of the intertrochanteric line and medial to the spiral line and linea aspera of the **femur**, extending inferiorly to the medial supracondylar line

Vastus Medialis

Insertion : **Tibial tuberosity**, via tendon of quadriceps femoris muscle and patellar ligament

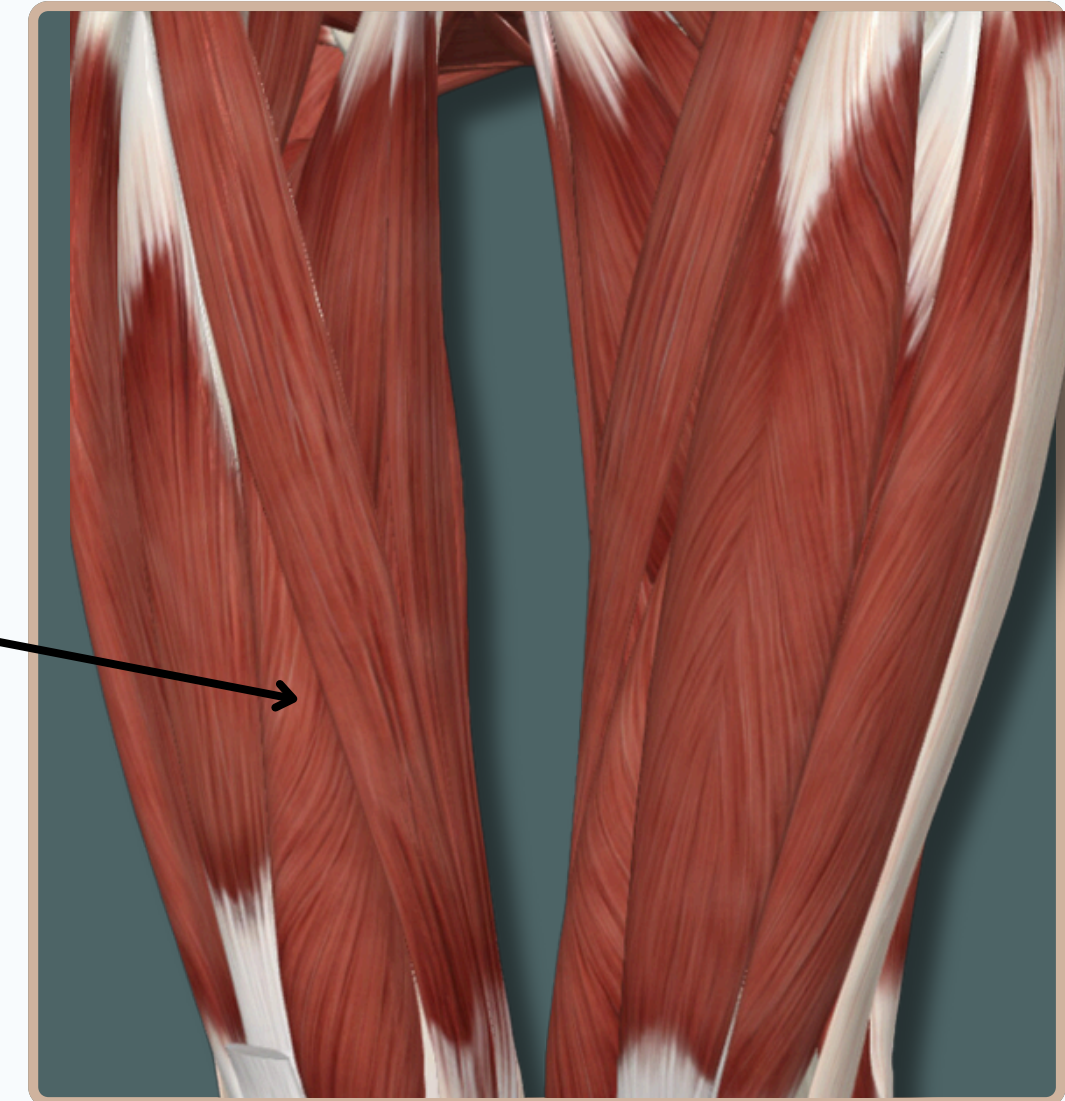
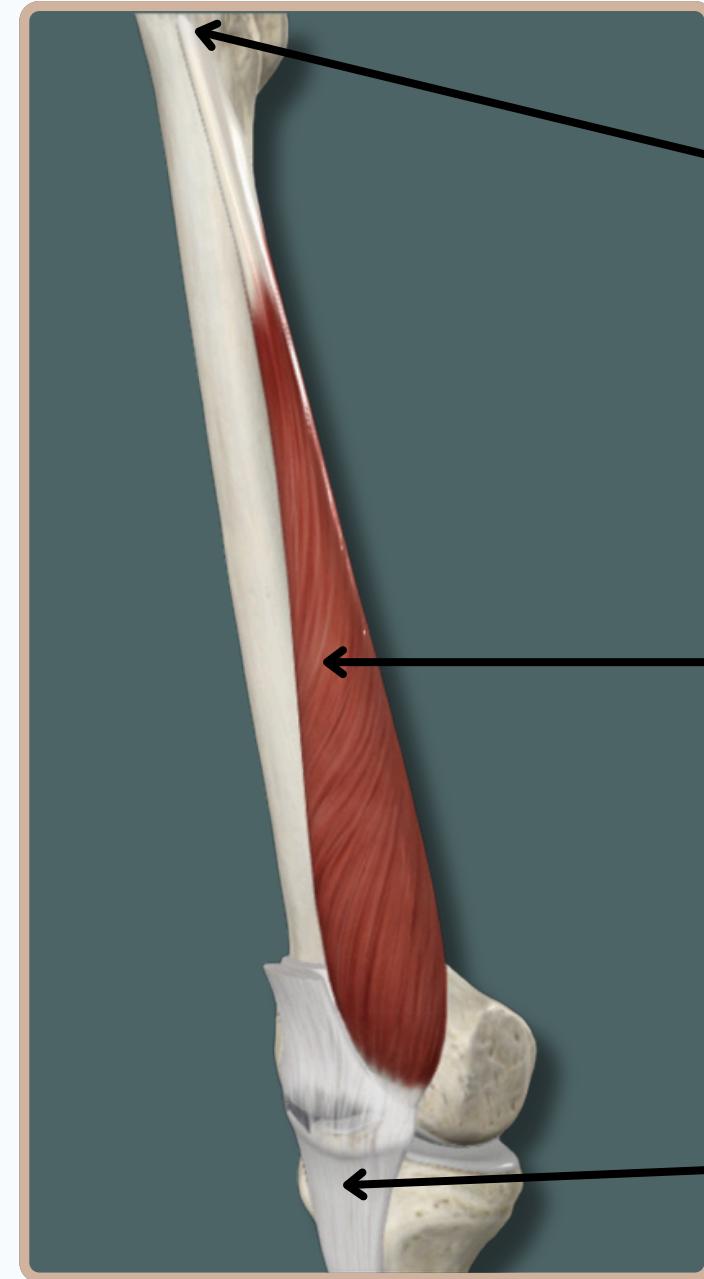
Action :

-**Extends** leg at **knee** joint

Nerve Supply :

Femoral Nerve

Medial View



ANTERIOR EXTENSOR MUSCLES OF THE THIGH

QUADRECIEPS FEMORIS

Origin : Intertrochanteric line, greater trochanter, gluteal tuberosity, and lateral lip of linea aspera of **femur**

Vastus Lateralis

Insertion : **Tibial tuberosity**, via tendon of quadriceps femoris muscle and patellar ligament

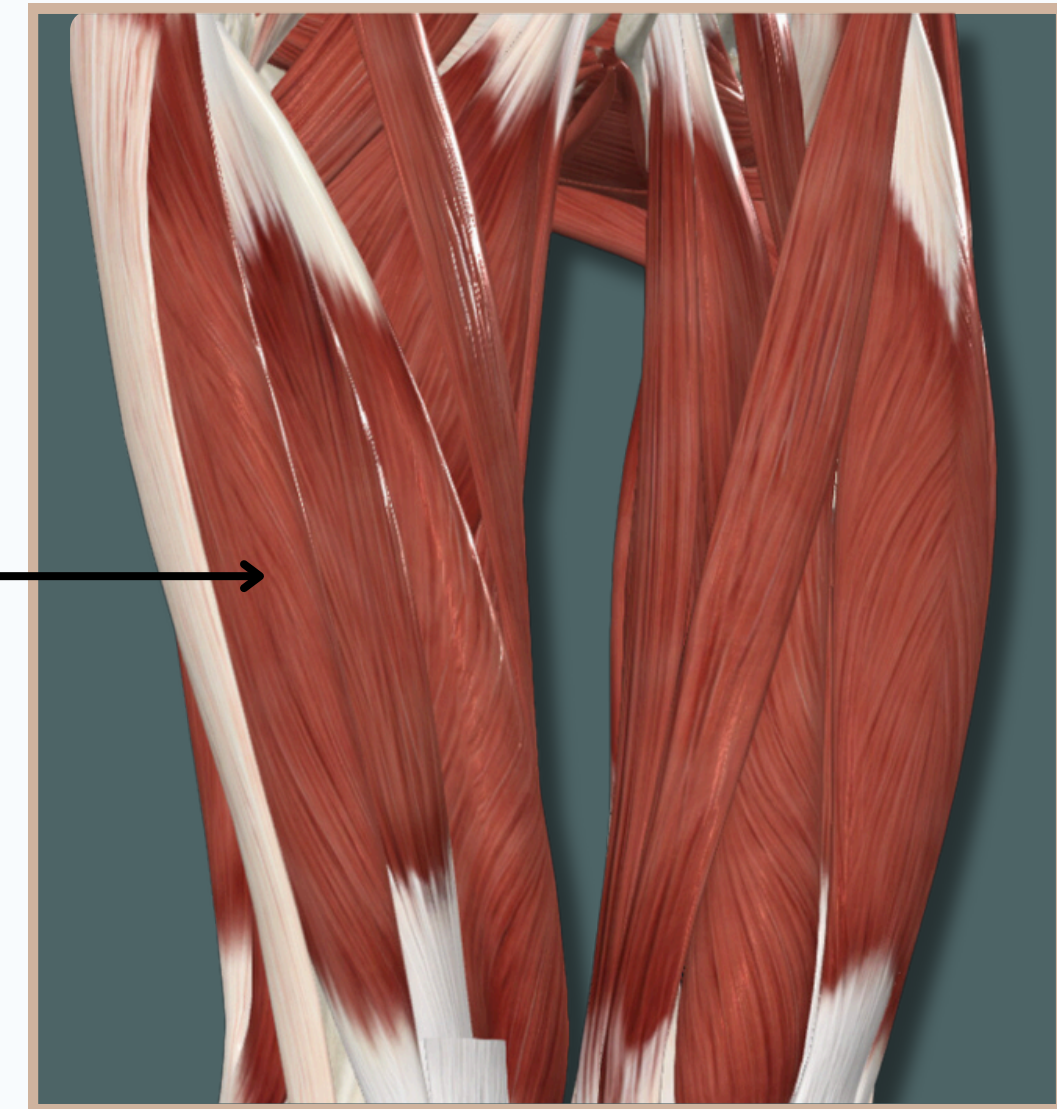
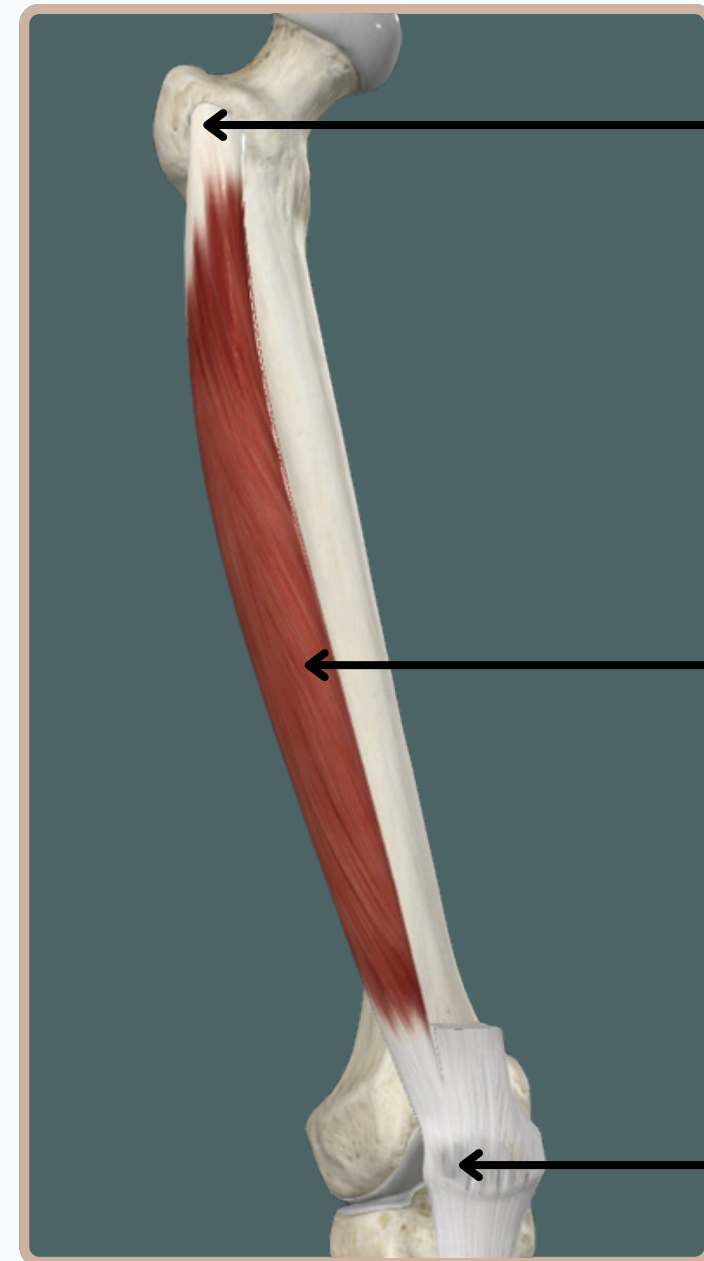
Action :

-**Extends** leg at **knee** joint

Nerve Supply :

Femoral Nerve

Lateral View



ANTERIOR EXTENSOR MUSCLES OF THE THIGH

QUADRECIEPS FEMORIS

Origin : Anterior and lateral surfaces of body of **femur**

Vastus Intermedius

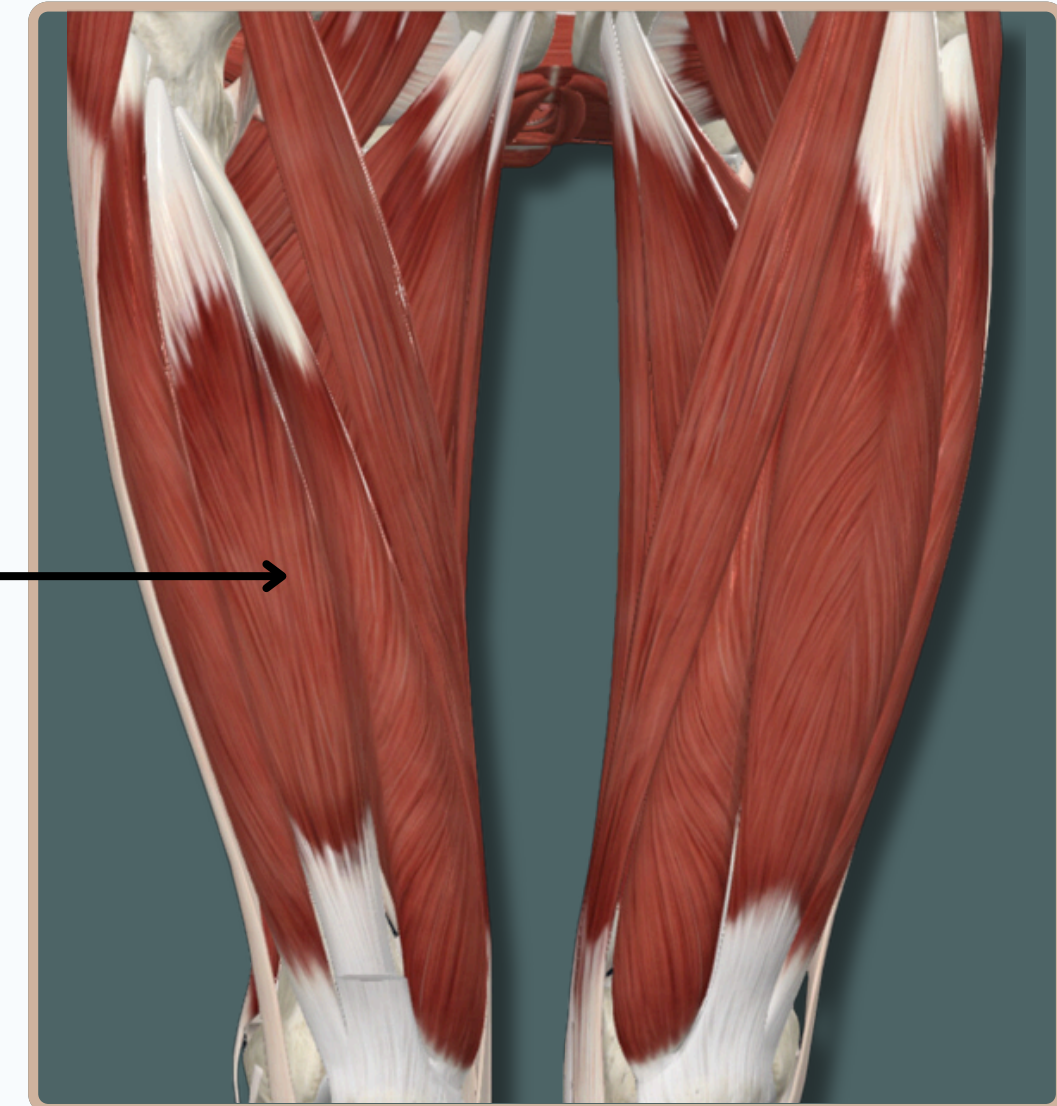
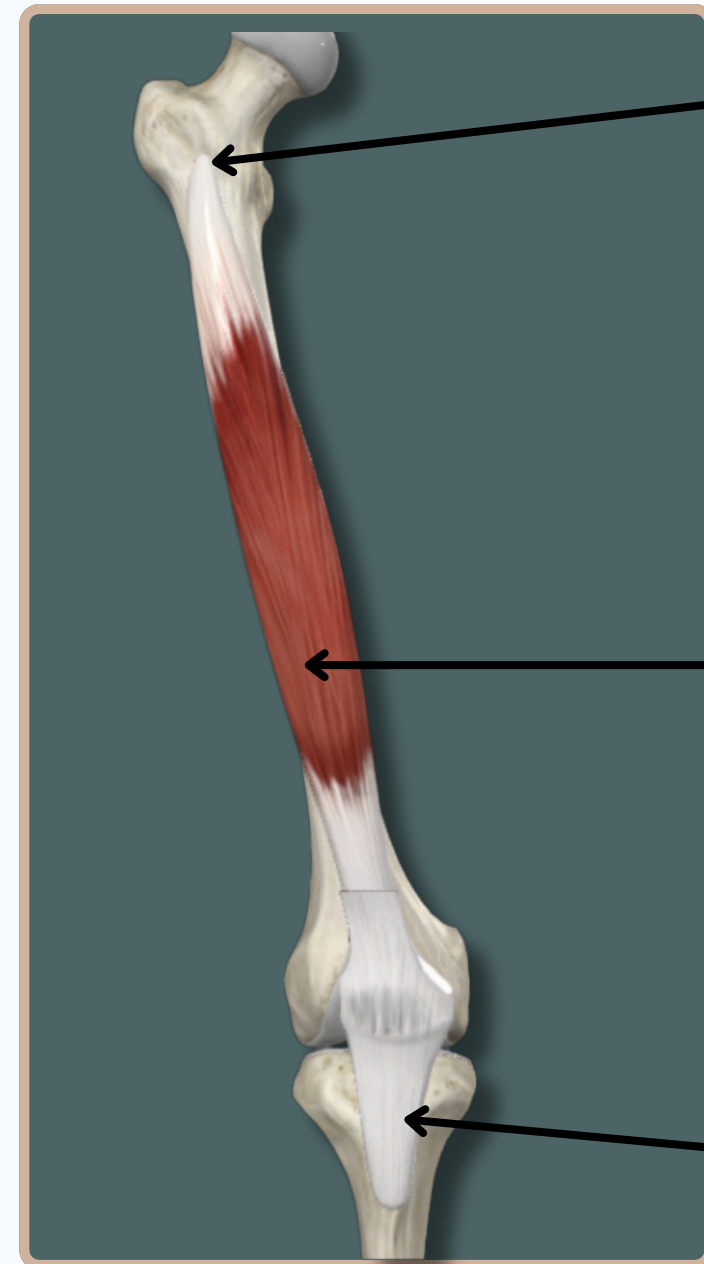Insertion : **Tibial tuberosity**, via tendon of quadriceps femoris muscle and patellar ligament

Action :

-**Extends** leg at **knee** joint

Nerve Supply :
Femoral Nerve

Anterior View



ANTERIOR EXTENSOR MUSCLES OF THE THIGH

SARTORIUS

Origin : - anterior superior **iliac spine**
- superior portion of the notch that is located inferior to the anterior superior **iliac spine**

Sartorius

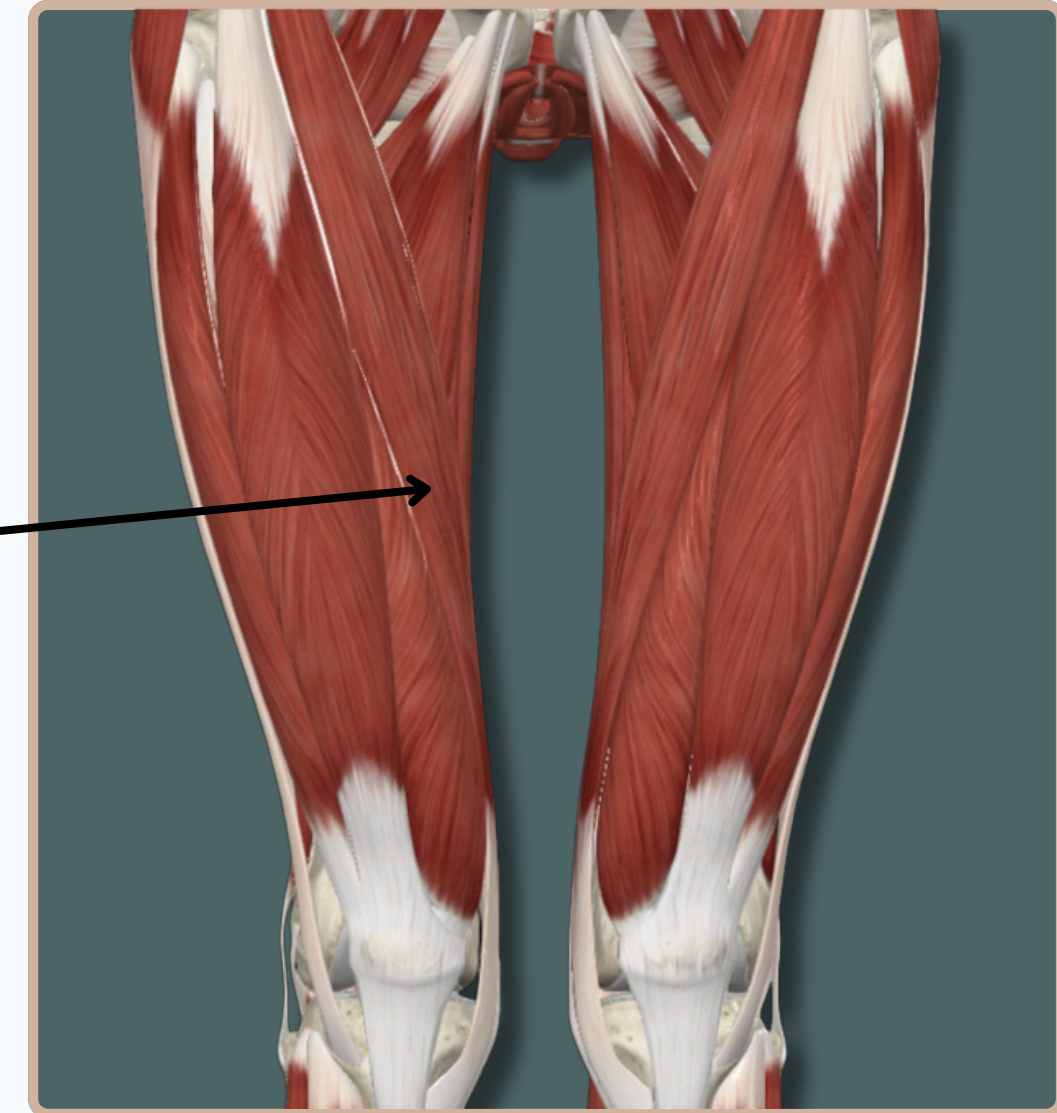
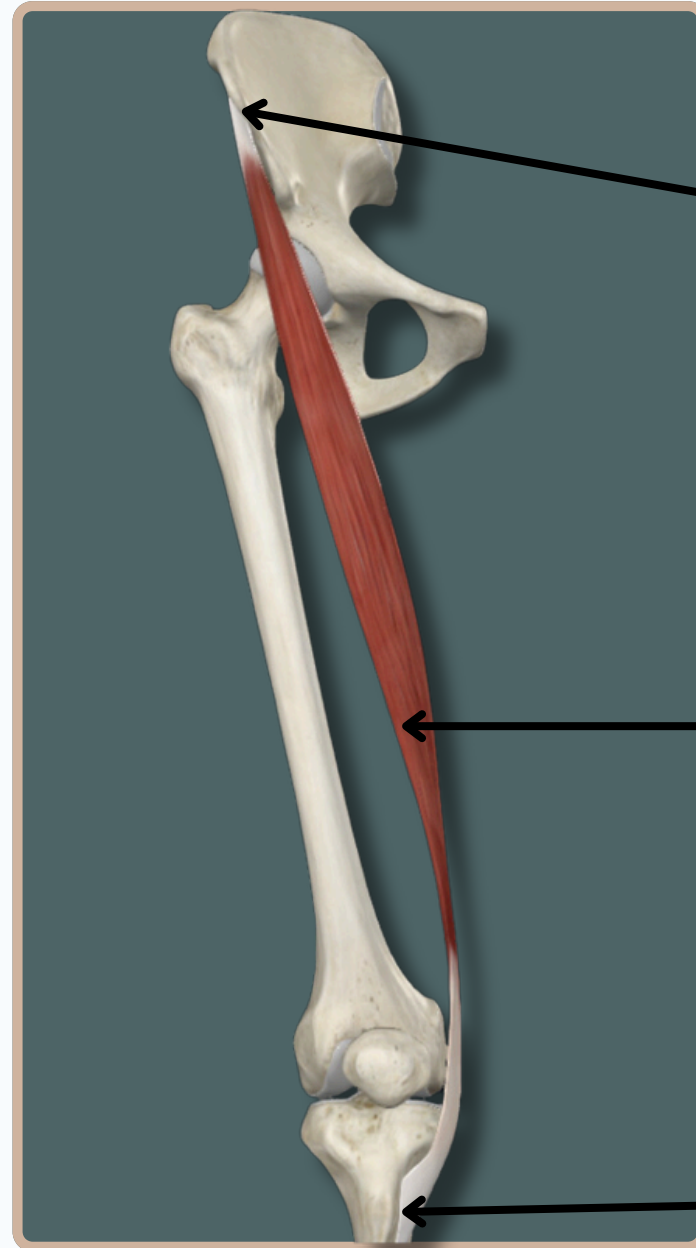
Insertion : the medial aspect of the proximal part of **tibia**

Action :

- Flexes** and **medially** rotates leg at **knee** joint
- Assists in **Flexion**, **Abduction** and **Lateral** rotation of thigh at **Hip** joint

Anterior View

Nerve Supply :
Femoral Nerve

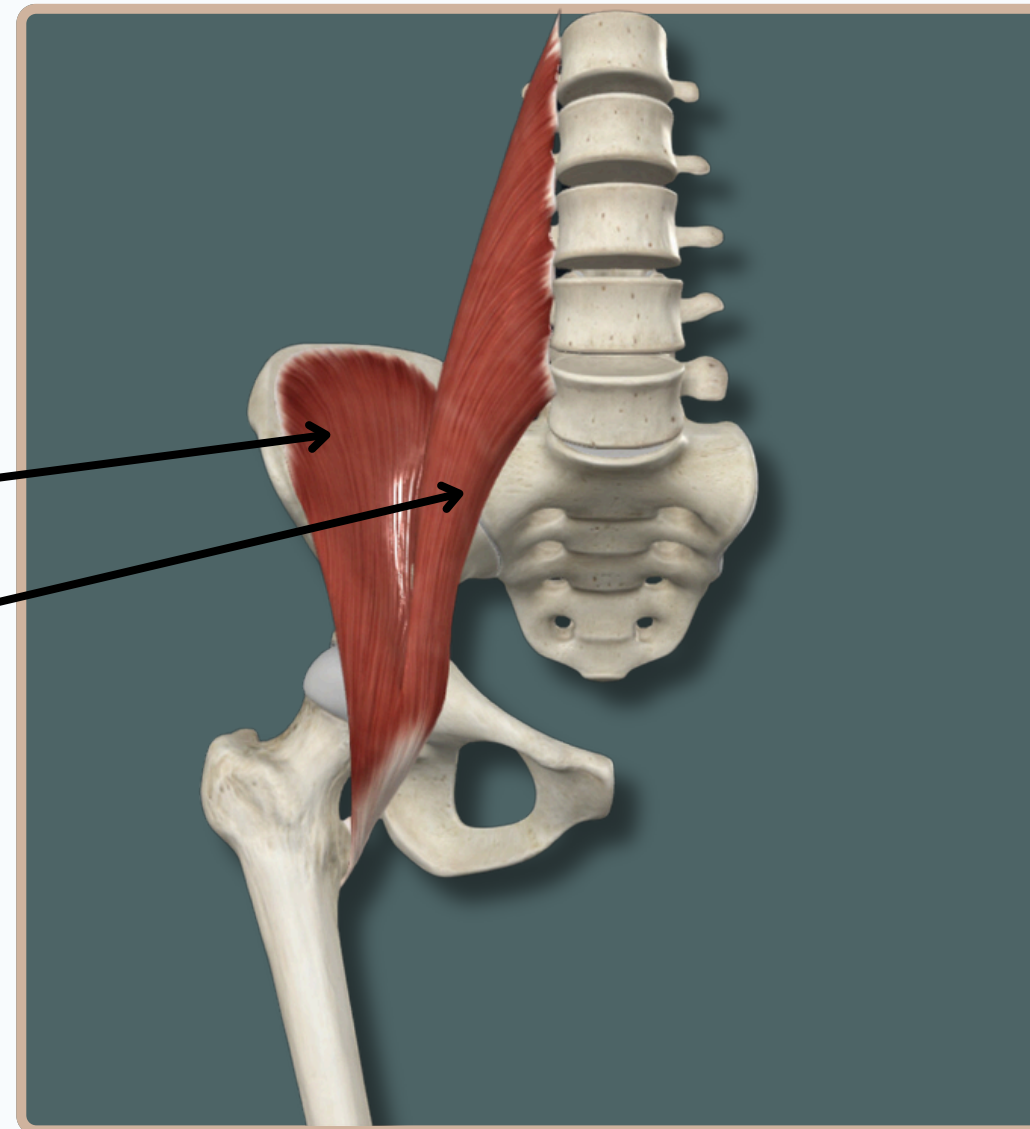


Iliopsoas

Two Muscles In The Anterior
Compartment of The Thigh, Having
The Same Insertion

Which Are :

- Iliacus
- Psoas Major



Anterior View

ANTERIOR EXTENSOR MUSCLES OF THE THIGH

PSOAS MAJOR

Origin : Transverse processes of **L1-L5** vertebrae, vertebral bodies of **T12-L5** vertebrae, and adjacent **intervertebral discs**

Psoas Major

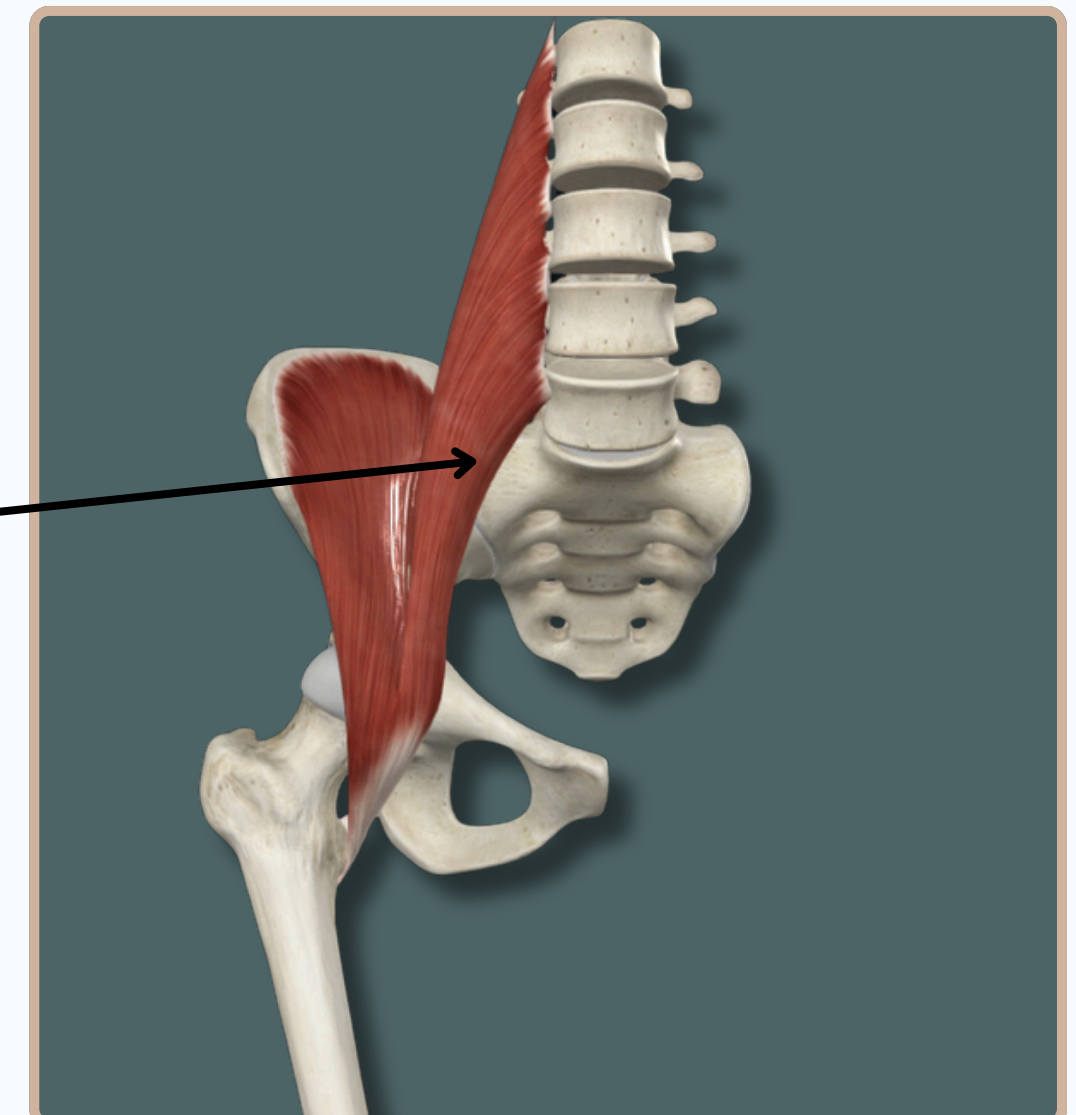
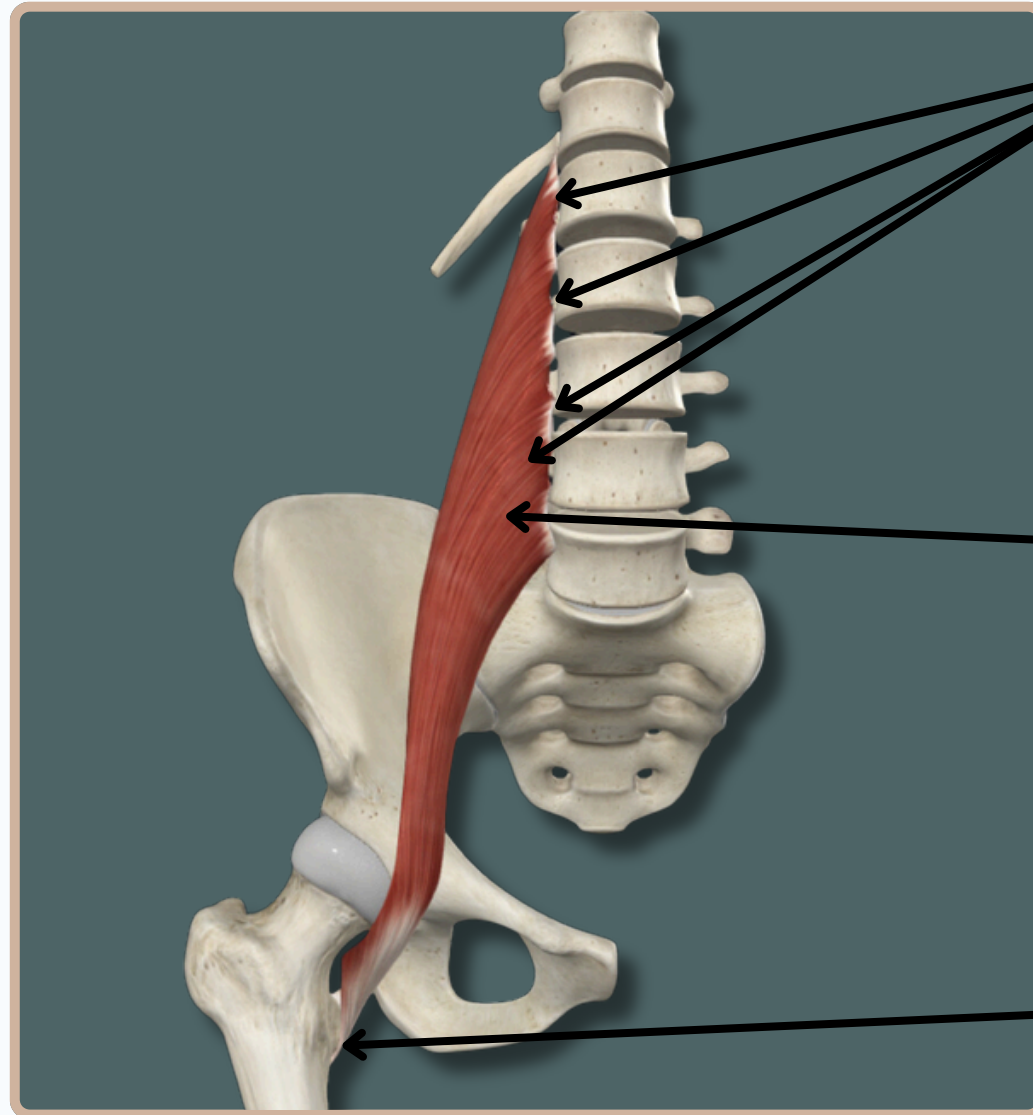
Insertion : Lesser trochanter of **femur**

Action :

- Flexes** thigh at **Hip** joint
- Flexes** trunk

Nerve Supply :
Femoral Nerve

Anterior View



ANTERIOR EXTENSOR MUSCLES OF THE THIGH

ILIACUS

Origin : Iliac crest; superior two thirds of iliac fossa; ala of sacrum; anterior sacroiliac ligaments

Iliacus

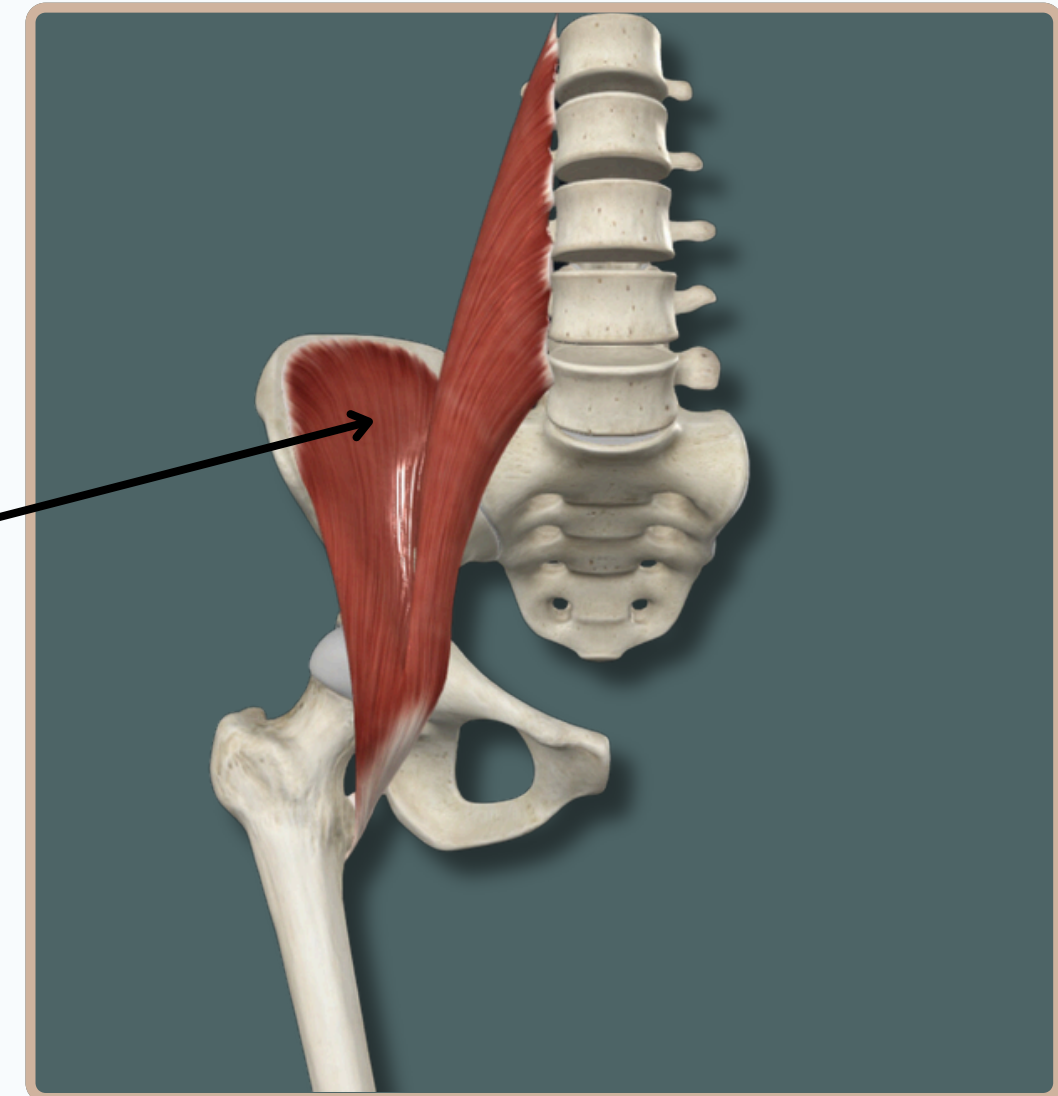
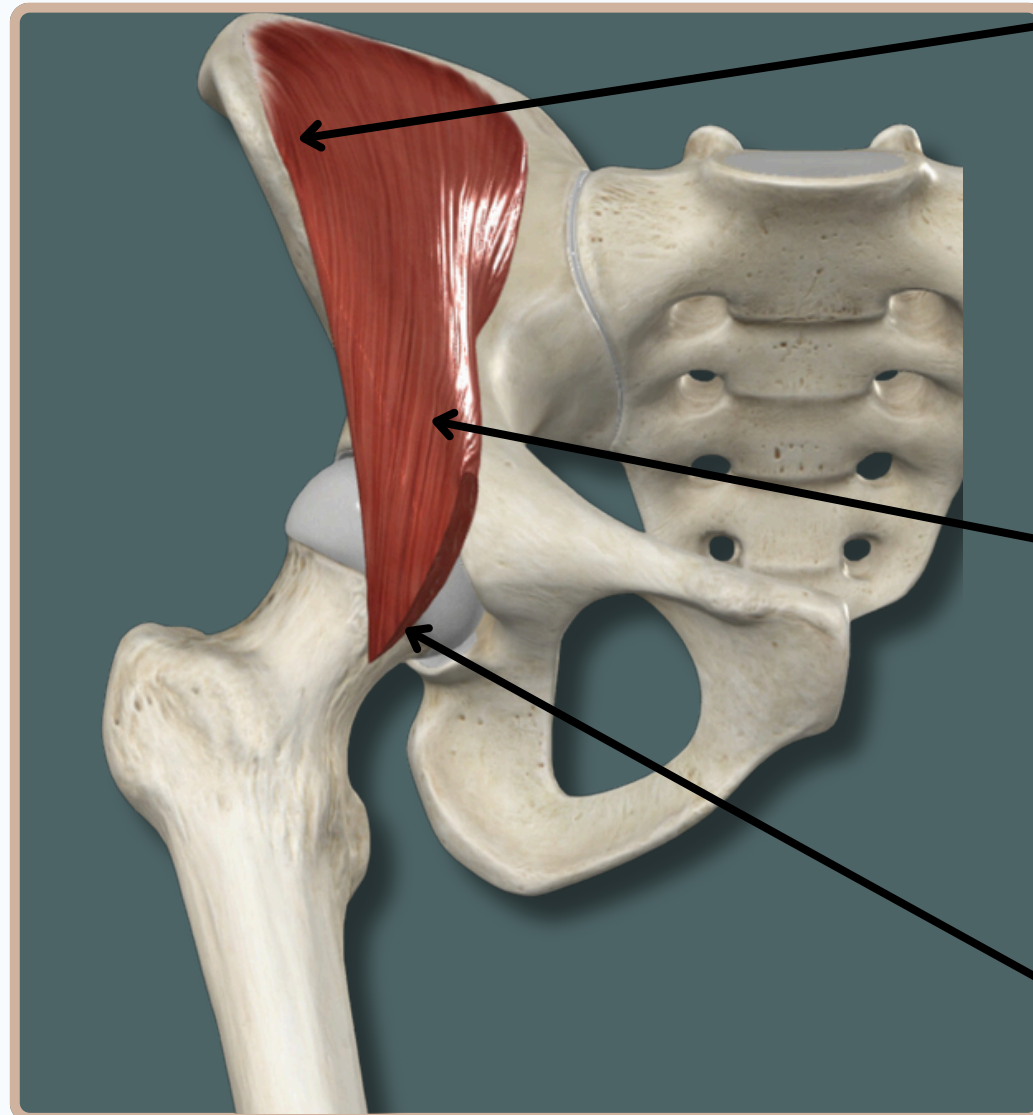
Insertion : Lesser trochanter of femur, via tendon of **psoas major**

Action :

- Flexes thigh at **Hip** joint
- Flexes trunk

Nerve Supply :
Femoral Nerve

Anterior View



THANK YOU

EDITED BY



SATURN
MEDIC



ARECH

© ALL COPYRIGHT ARE RESERVED FOR
SATURN MEDIC AND ARECH

WWW.SATURNMEDIC.COM