

# ANATOMY OF UPPER LIMB

## PRACTICAL LECTURE - 14 - BLOOD VESSELS

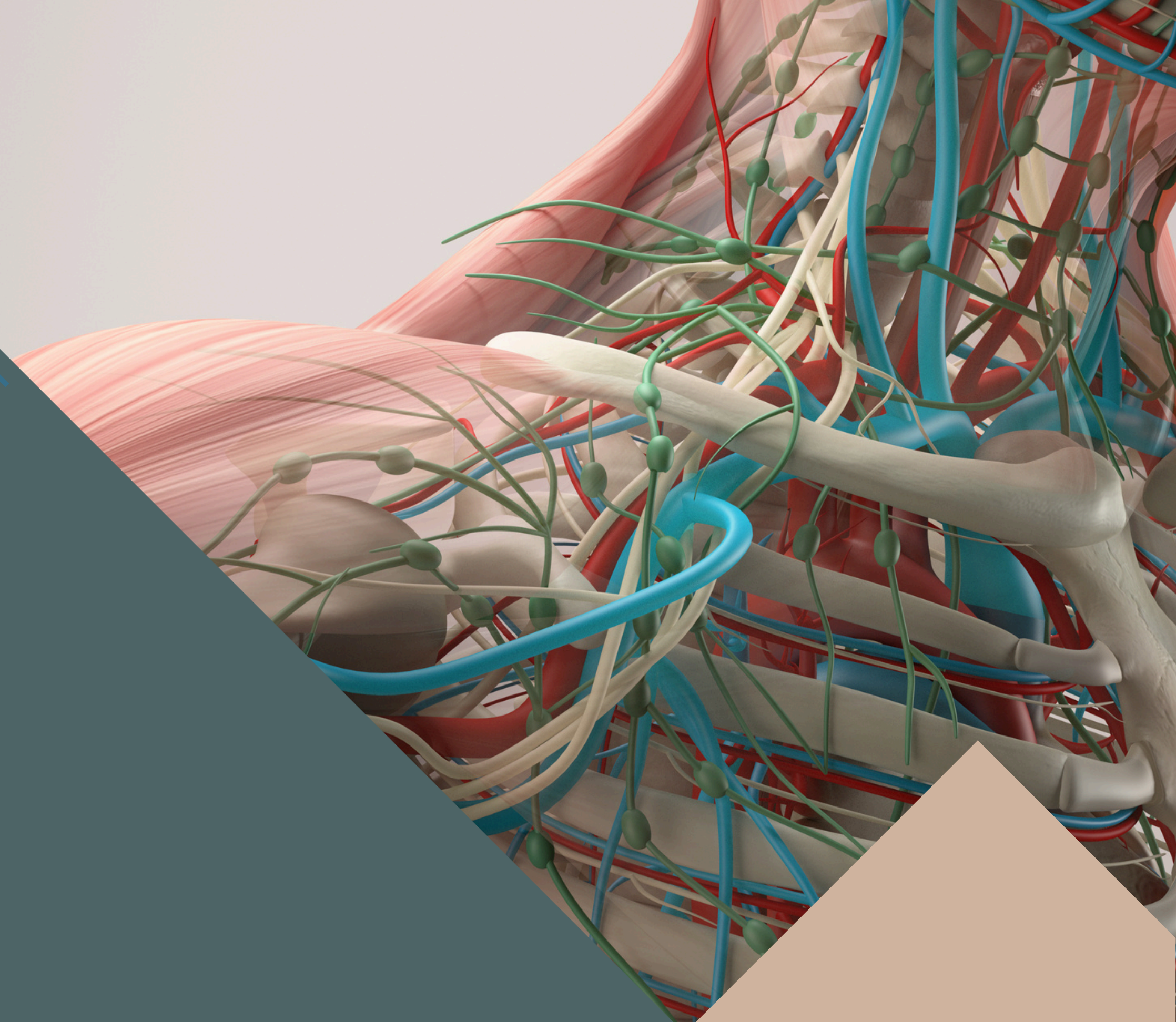
EDITED BY



SATURN  
MEDIC



ARECH

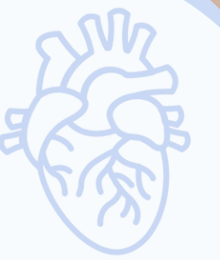

© ALL COPYRIGHT ARE RESERVED FOR  
SATURN MEDIC AND ARECH

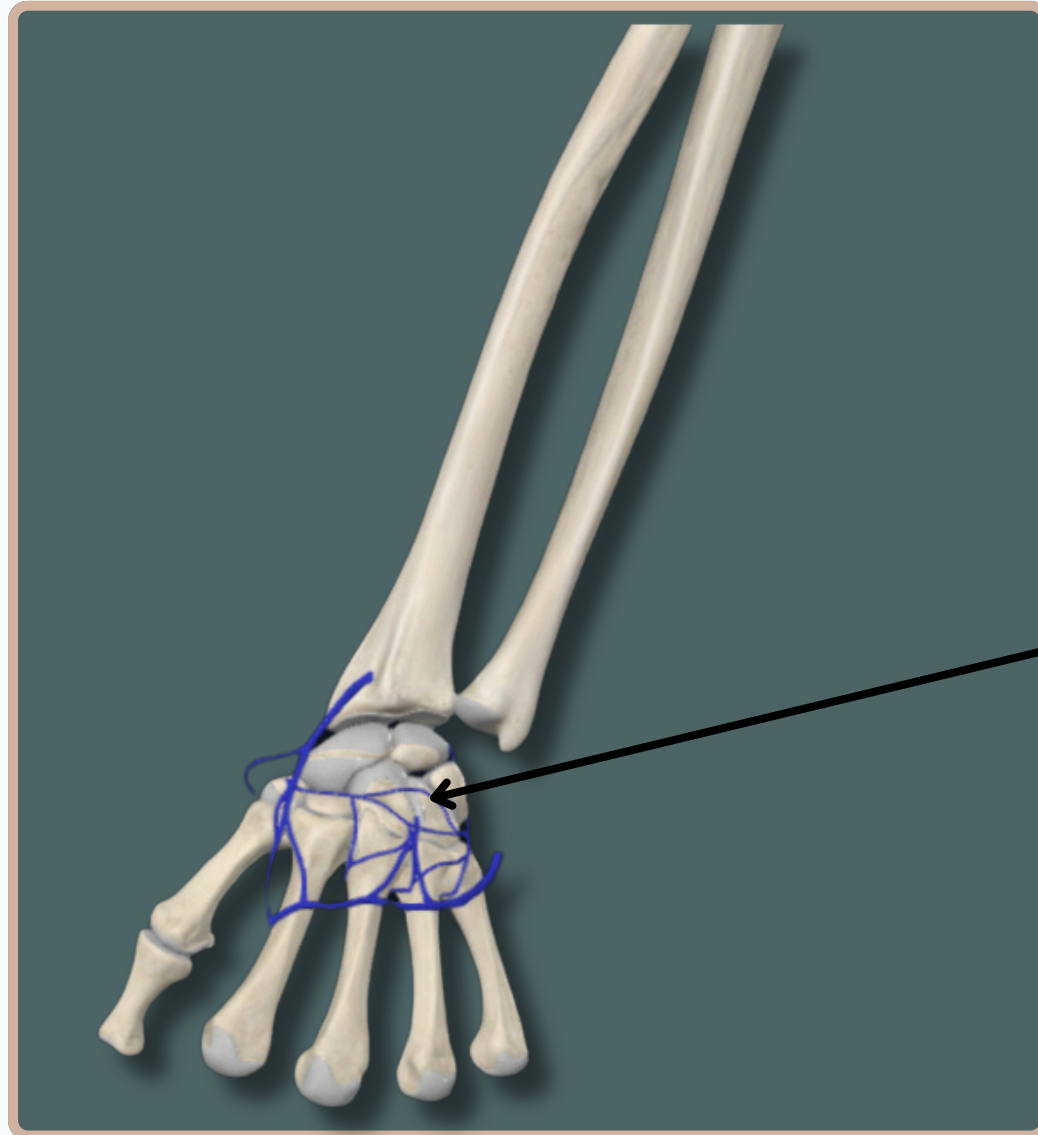
[WWW.SATURNMEDIC.COM](http://WWW.SATURNMEDIC.COM)



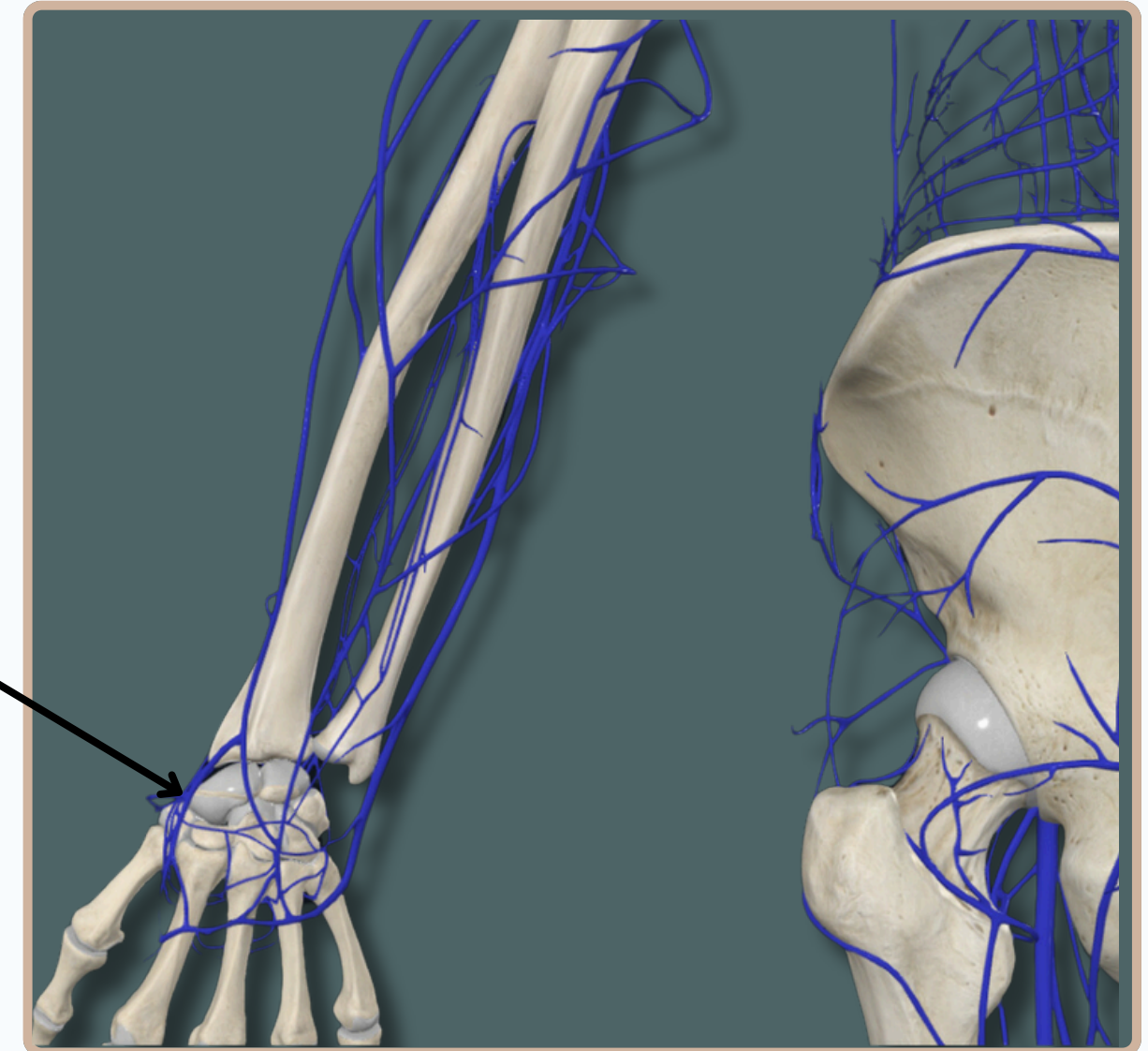
# BLOOD VESSELS



## VENOUS SYSTEM



**Dorsal Venous  
Network**

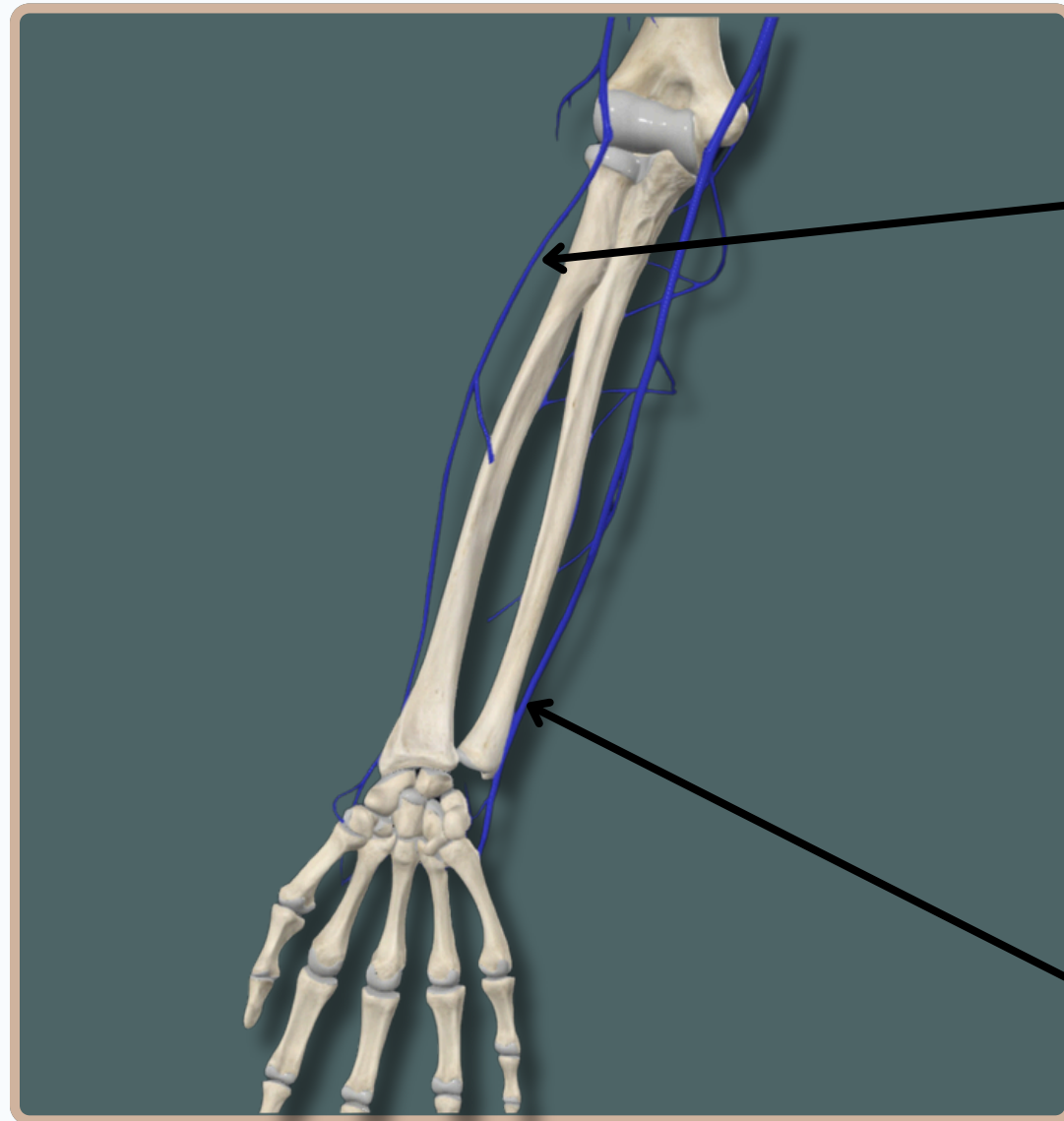
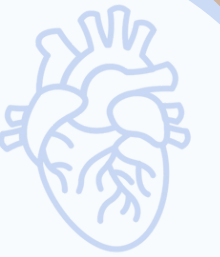

**Anterior View**



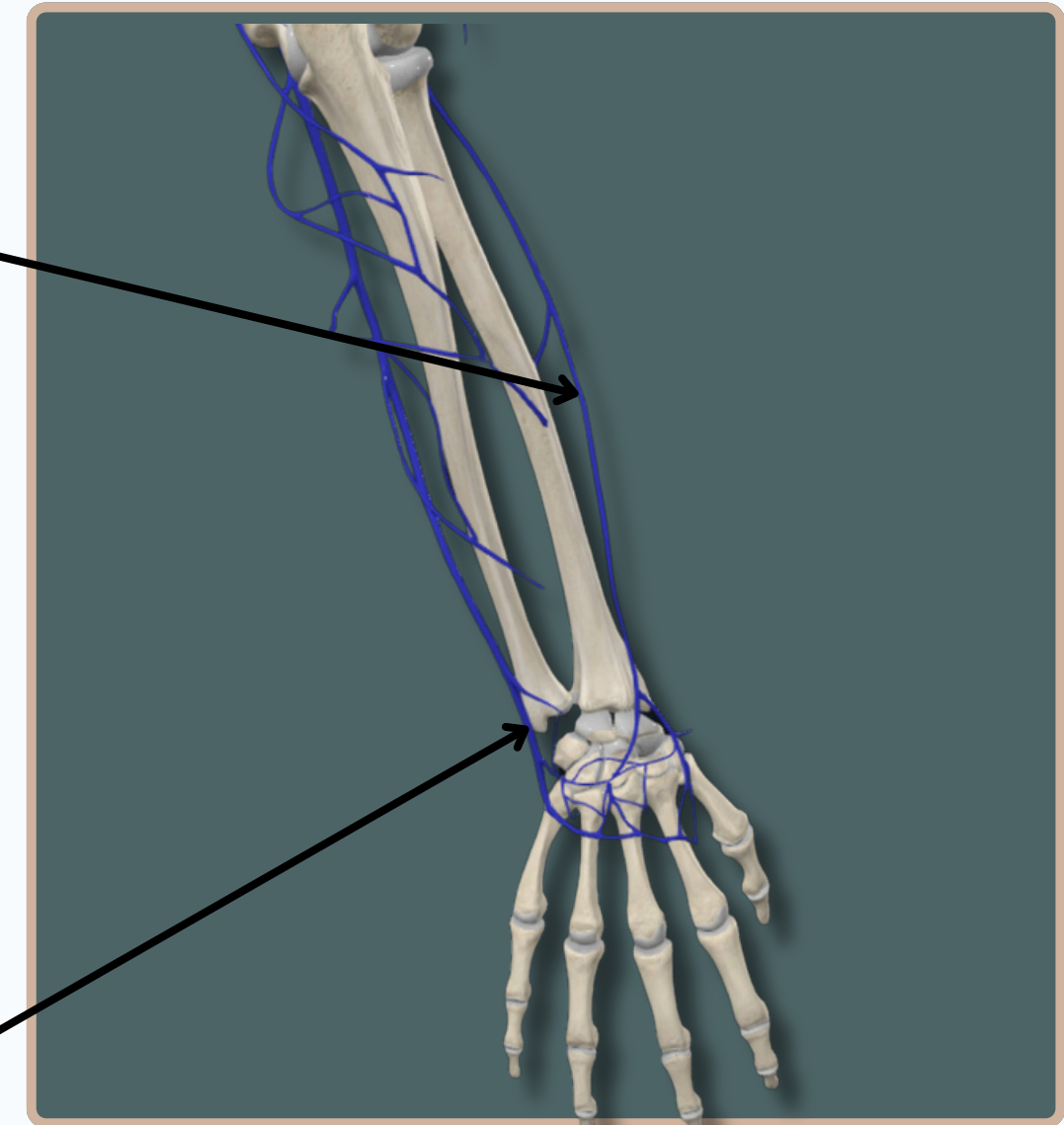
# BLOOD VESSELS

## VENOUS SYSTEM



**Anterior View**

**Cephalic Vein**  
(Laterally)



**Posterior View**

**Basilic Vein**  
(Medially)



# BLOOD VESSELS

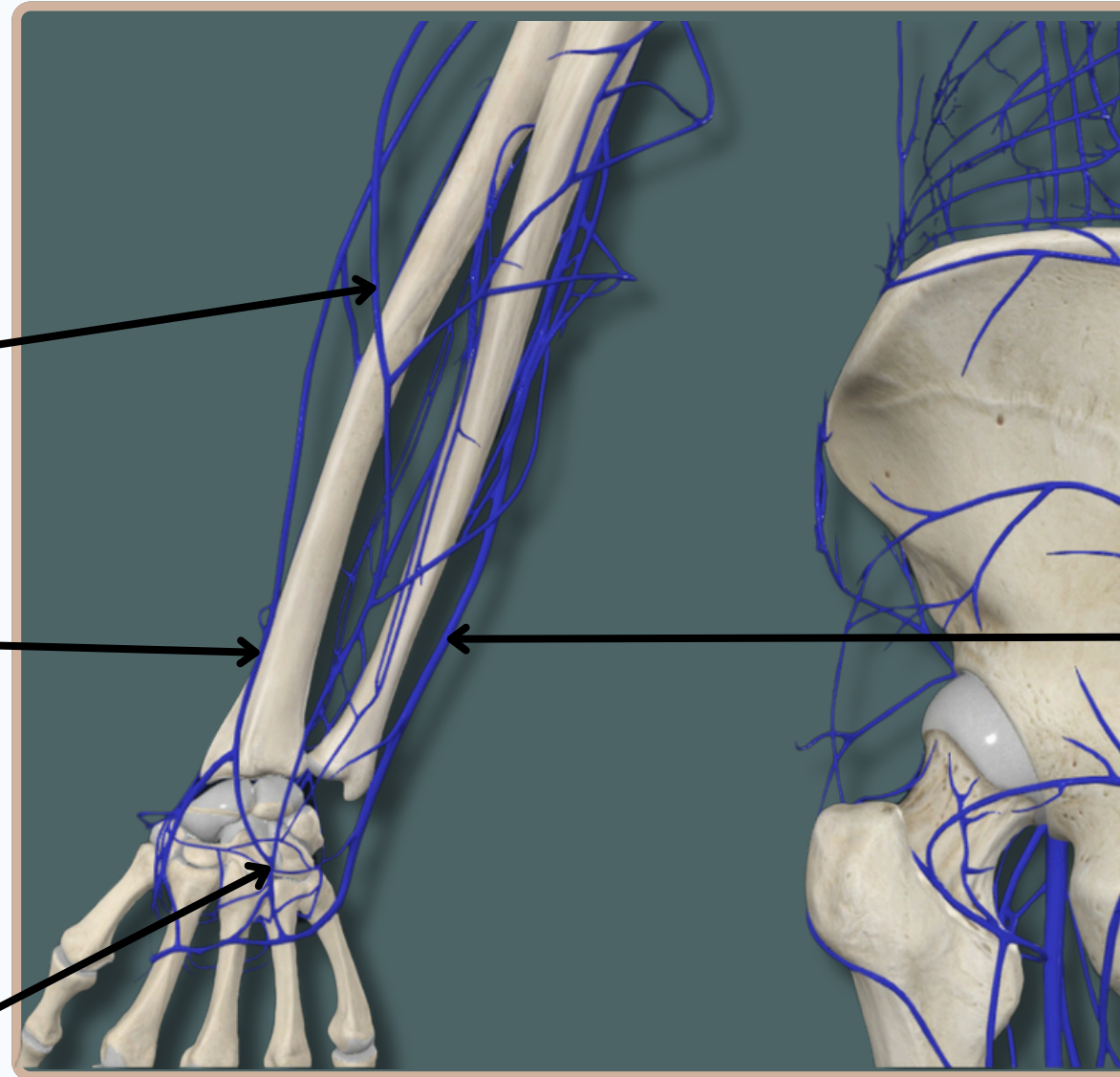
## VENOUS SYSTEM



**Accessory Cephalic Vein**

**Cephalic Vein  
(Laterally)**

**Dorsal Venous  
Network**



**Basilic Vein  
(Medially)**

**Anterior View**



# BLOOD VESSELS



## VENOUS SYSTEM

**Cephalic Vein**

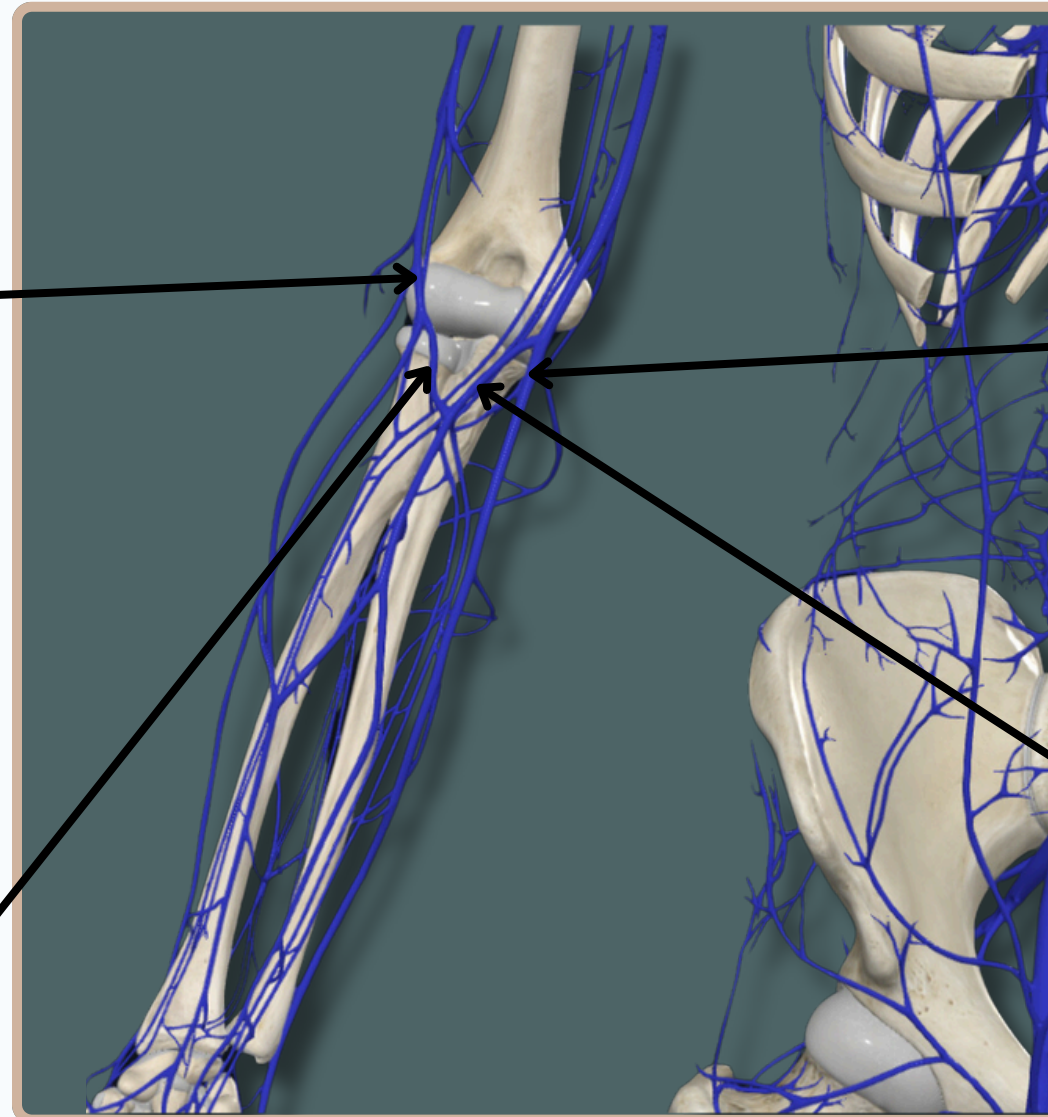
**Basilic Vein**

**Median Antebrachial Vein**

Drains The Superficial Structures of The Forearm And Wrist Between The Basilic And Cephalic Veins

**Median Cubital Vein**

Connects The Cephalic And Basilic Veins



**Anterior View**



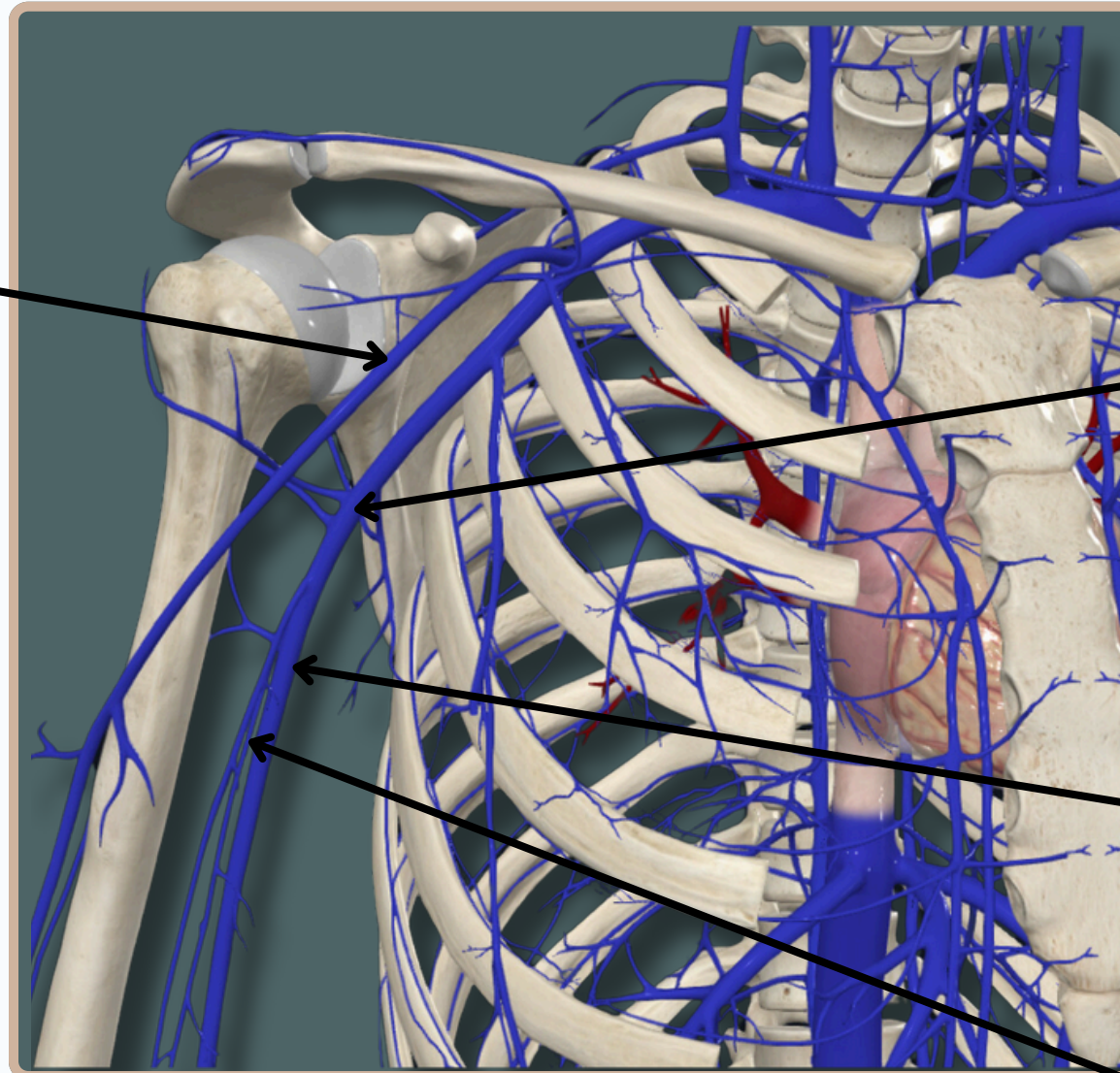
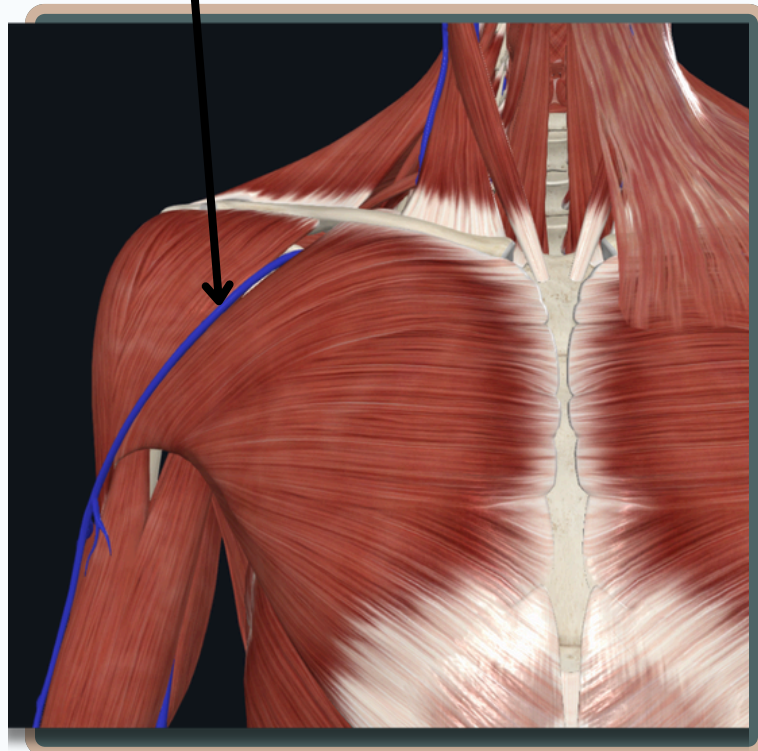
# BLOOD VESSELS



## VENOUS SYSTEM

### Cephalic Vein

Passes Through The Deltopectoral Groove



### Axillary Vein

Continuation of Basilic Vein

### Basilic Vein

Terminates By Uniting With The Paired Brachial Veins To Form The Axillary Vein At The Inferior Border of The Teres Major Muscle

### Brachial Vein

## Anterior View



# BLOOD VESSELS



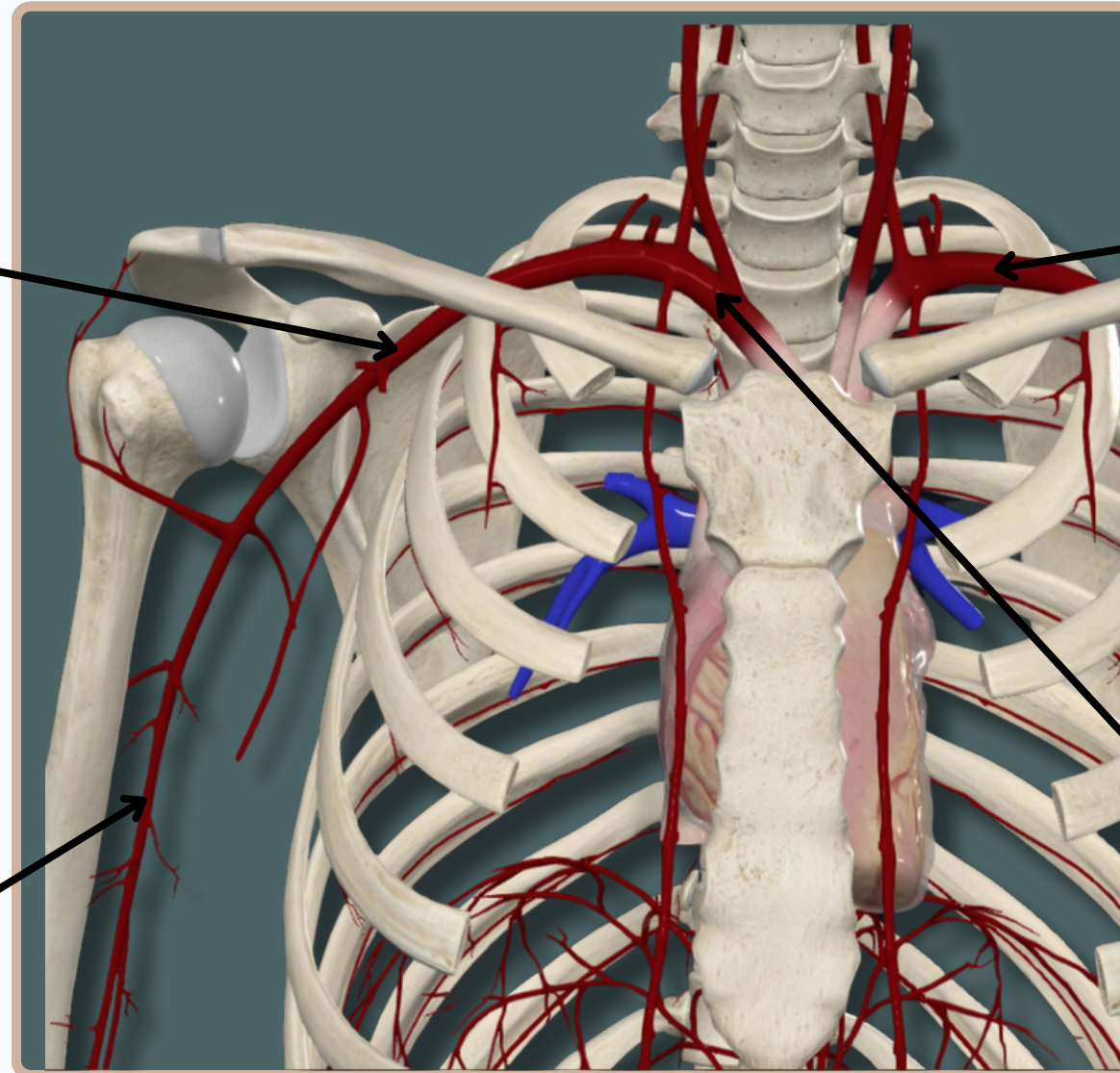
## ARTERIAL SYSTEM

### Axillary Artery

Begins As A continuation From The Subclavian Artery **At The Outer Border of The First Rib**

### Brachial Artery

Begins As A continuation From The Axillary Artery **At The Lower Margin of The Teres Major Muscle**



### Subclavian Artery (Left)

Directly From The **Arch of Aorta**

### Subclavian Artery (Right)

From The **Brachiocephalic Trunk**

Anterior View



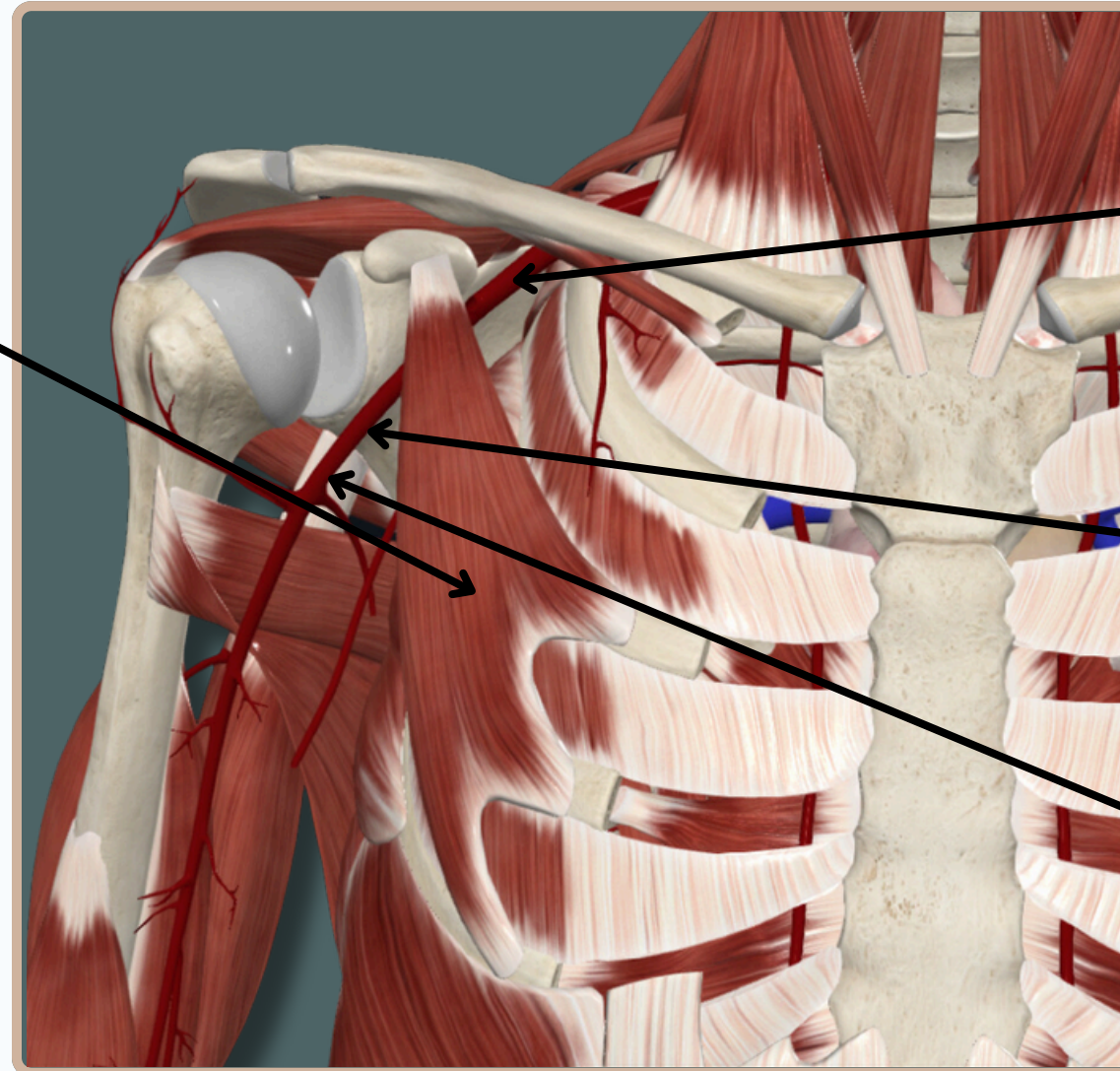
# BLOOD VESSELS



## ARTERIAL SYSTEM

The course of **Axillary Artery** Is Determined By **Pectoralis Minor** It Divides The Artery Into **Three Parts** :

- **First Or Proximal** Part : Gives Only **One** Branch
- **Second Or Middle** Part : Gives **Two** Branches
- **Third Or Distal** Part : Gives **Three** Branches



**First Or Proximal Part**

**Second Or Middle Part**

**Third Or Distal Part**

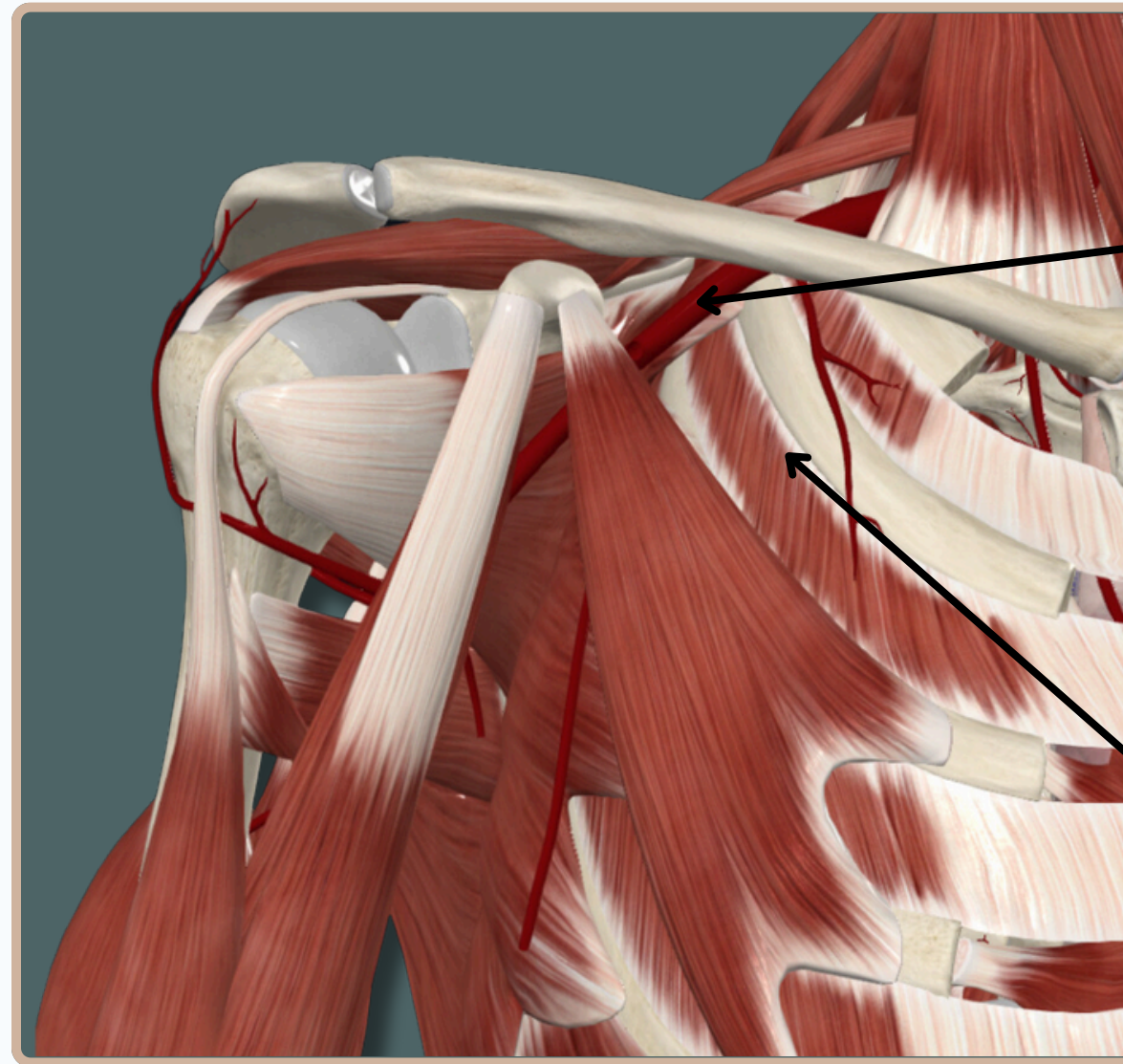
**Anterior View**





# BLOOD VESSELS

## ARTERIAL SYSTEM



**First Or Proximal Part  
of Axillary Artery**

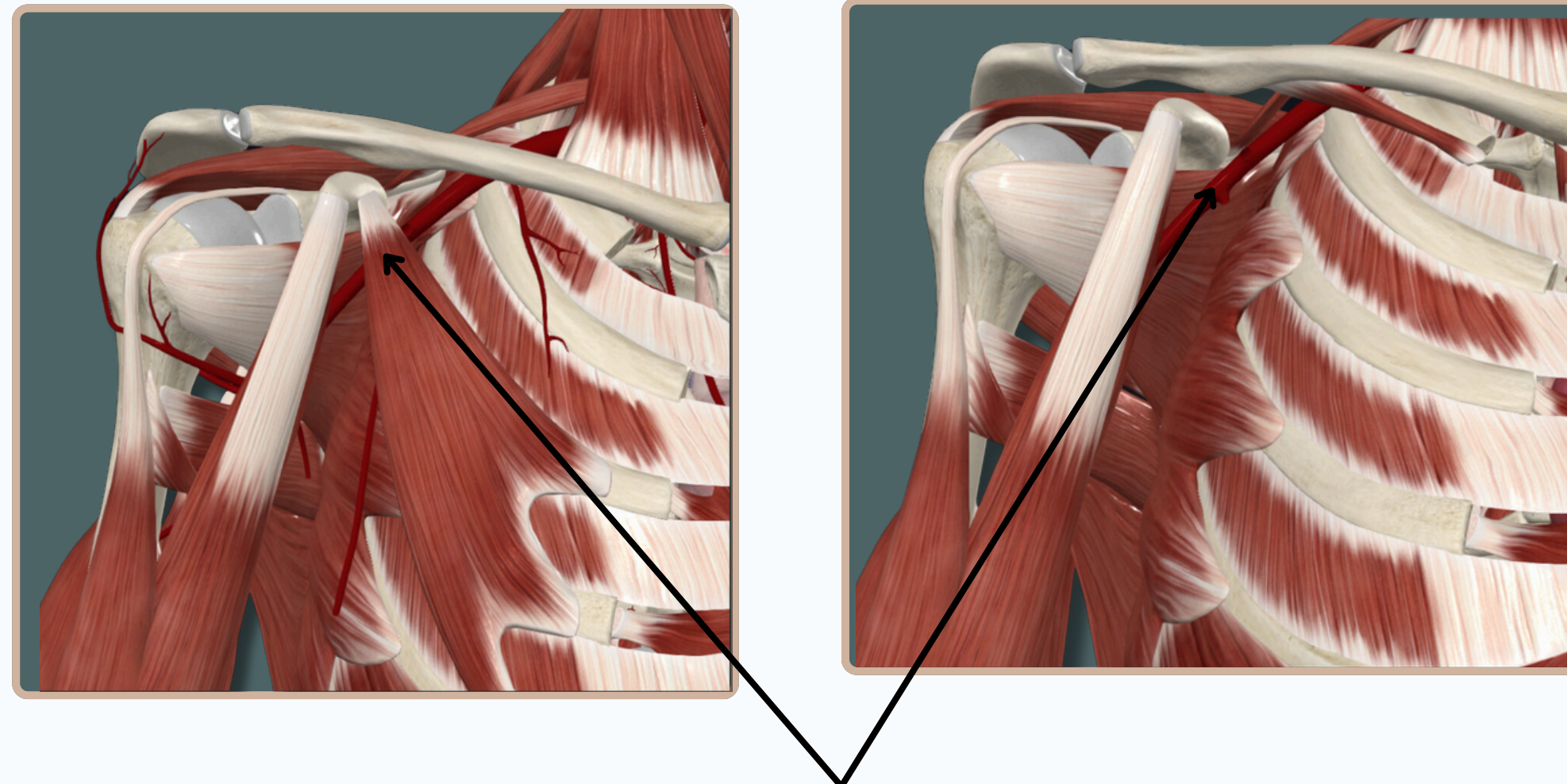
**Superior Thoracic Artery**

**Anterior View**



# BLOOD VESSELS

## ARTERIAL SYSTEM



**Second Or Middle Part of Axillary Artery  
Is Hidden By Pectoralis Minor Muscle**

**Anterior View**

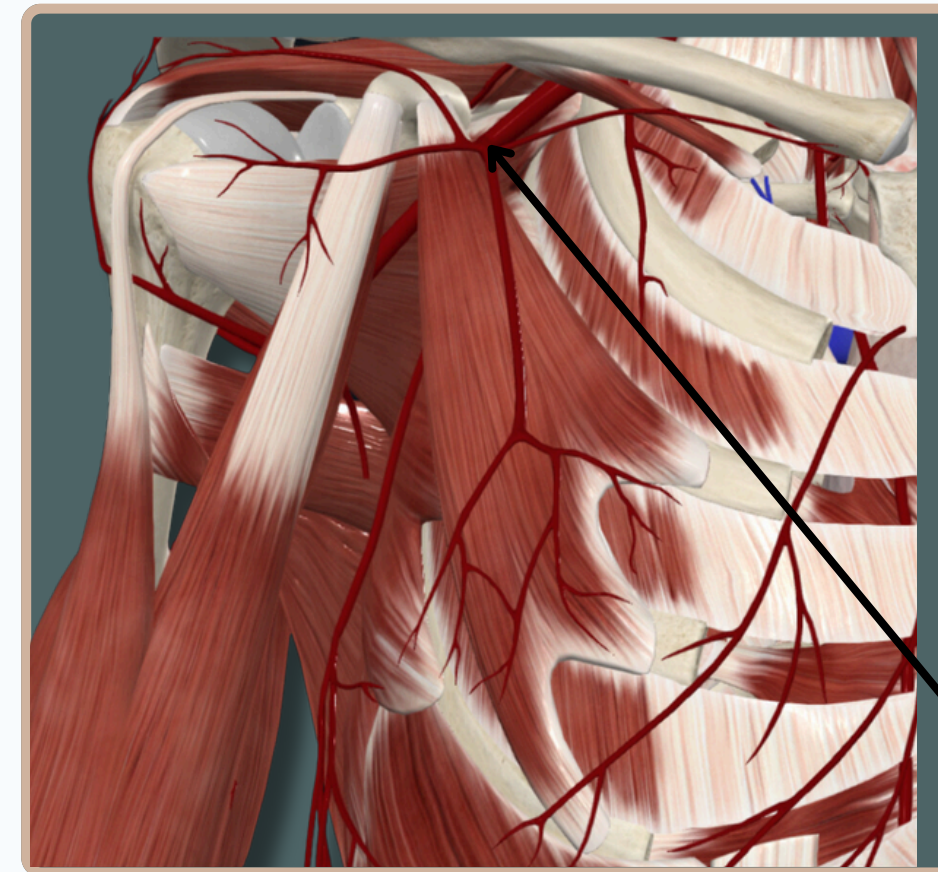
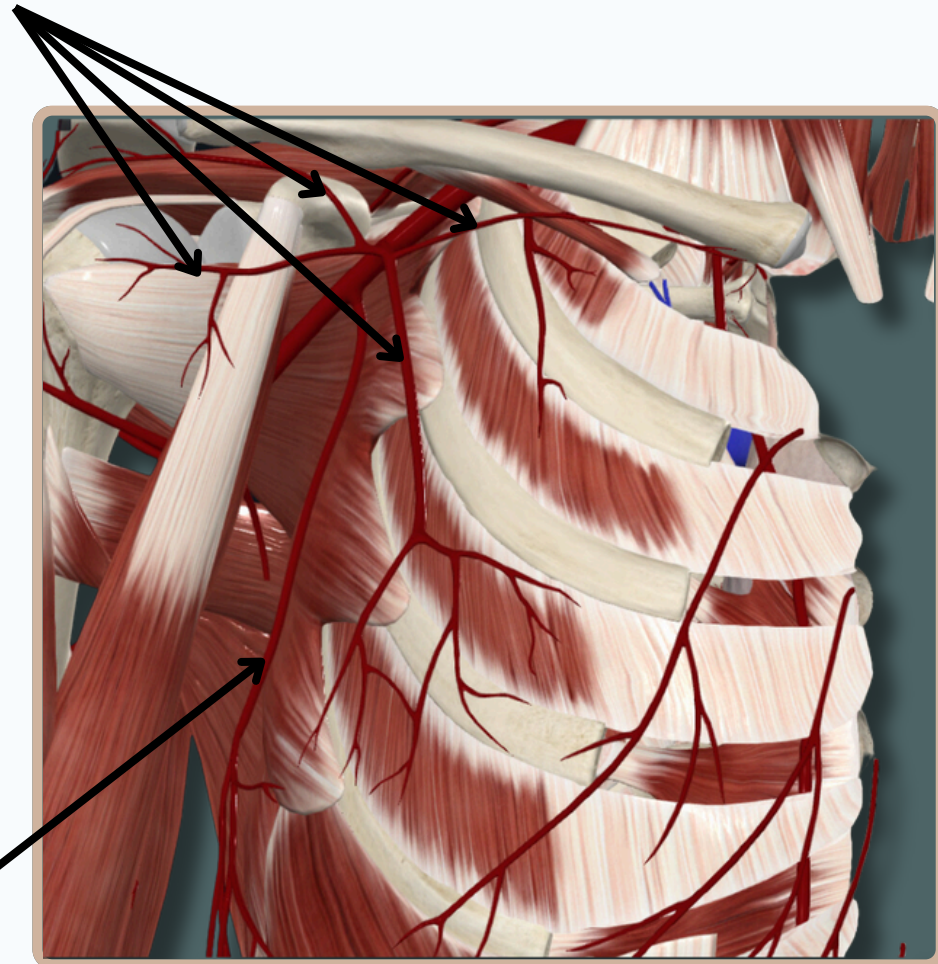


# BLOOD VESSELS



## ARTERIAL SYSTEM

### Branches of Thoracoacromial Artery



### Lateral Thoracic Artery

Provide Blood Supply For The **Female Breast**

### Thoracoacromial Artery

## Anterior View



# BLOOD VESSELS



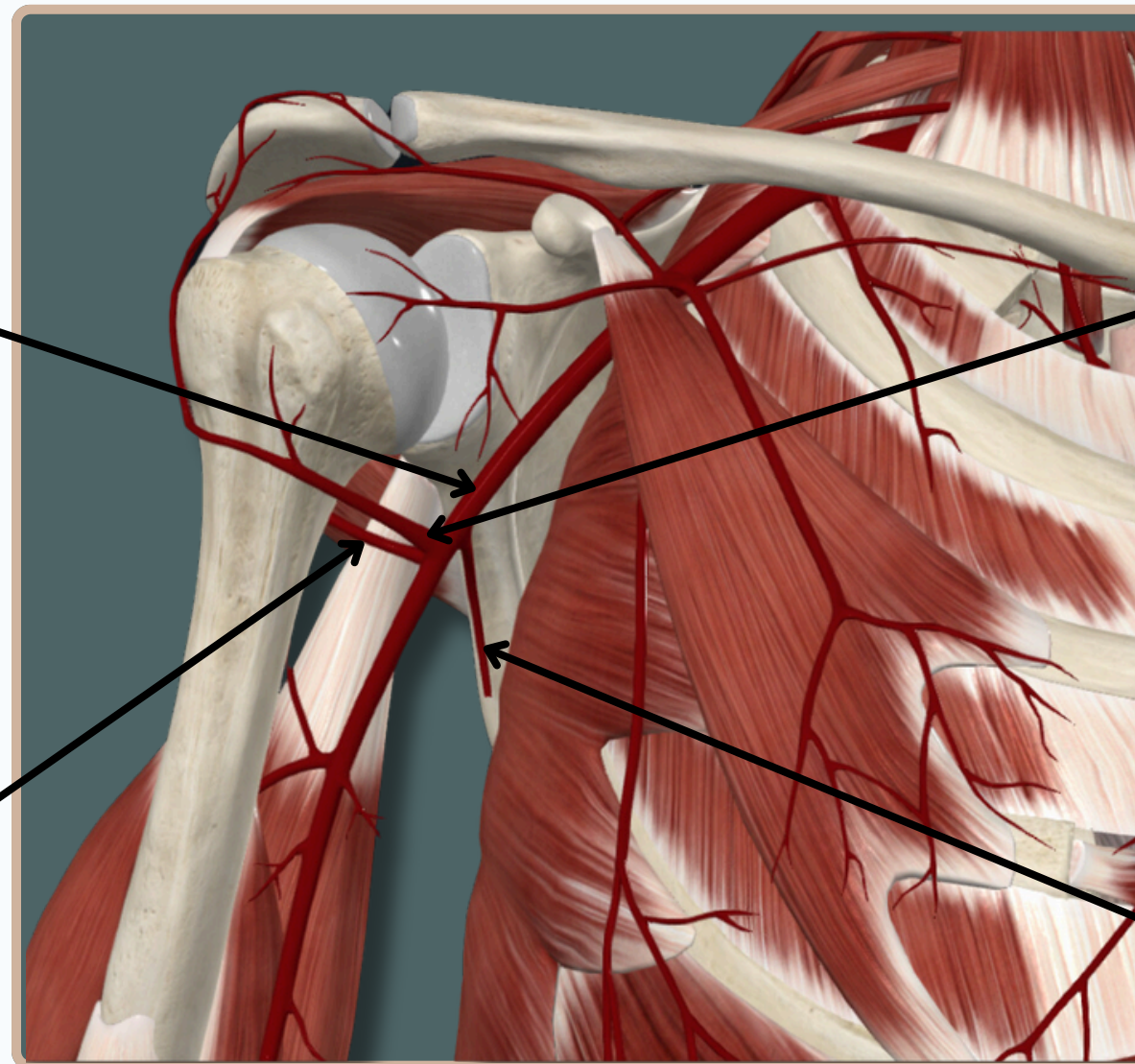
## ARTERIAL SYSTEM

**Third Or Distal Part of Axillary Artery**

**Anterior Circumflex Humeral Artery**

**Posterior Circumflex Humeral Artery**

**Subscapular Artery**



**Anterior View**



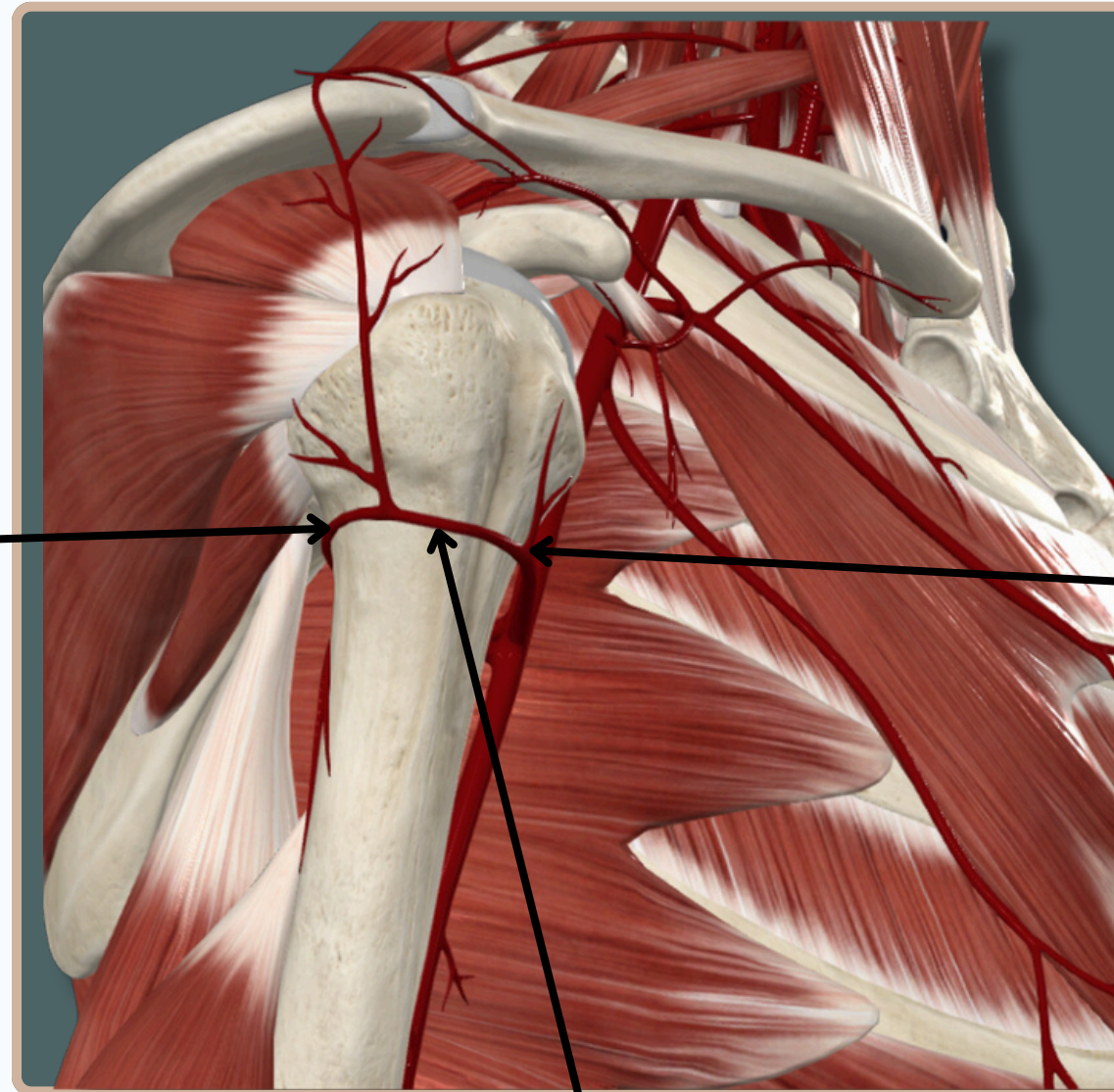
# BLOOD VESSELS

## ARTERIAL SYSTEM



**Posterior Circumflex  
Humeral Artery**

**Anterior Circumflex  
Humeral Artery**

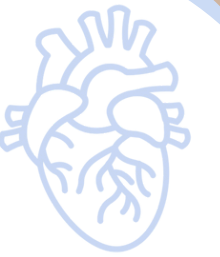

**Anastomosis Between Anterior &  
Posterior Circumflex Humeral Artery**

**Lateral View**



# BLOOD VESSELS



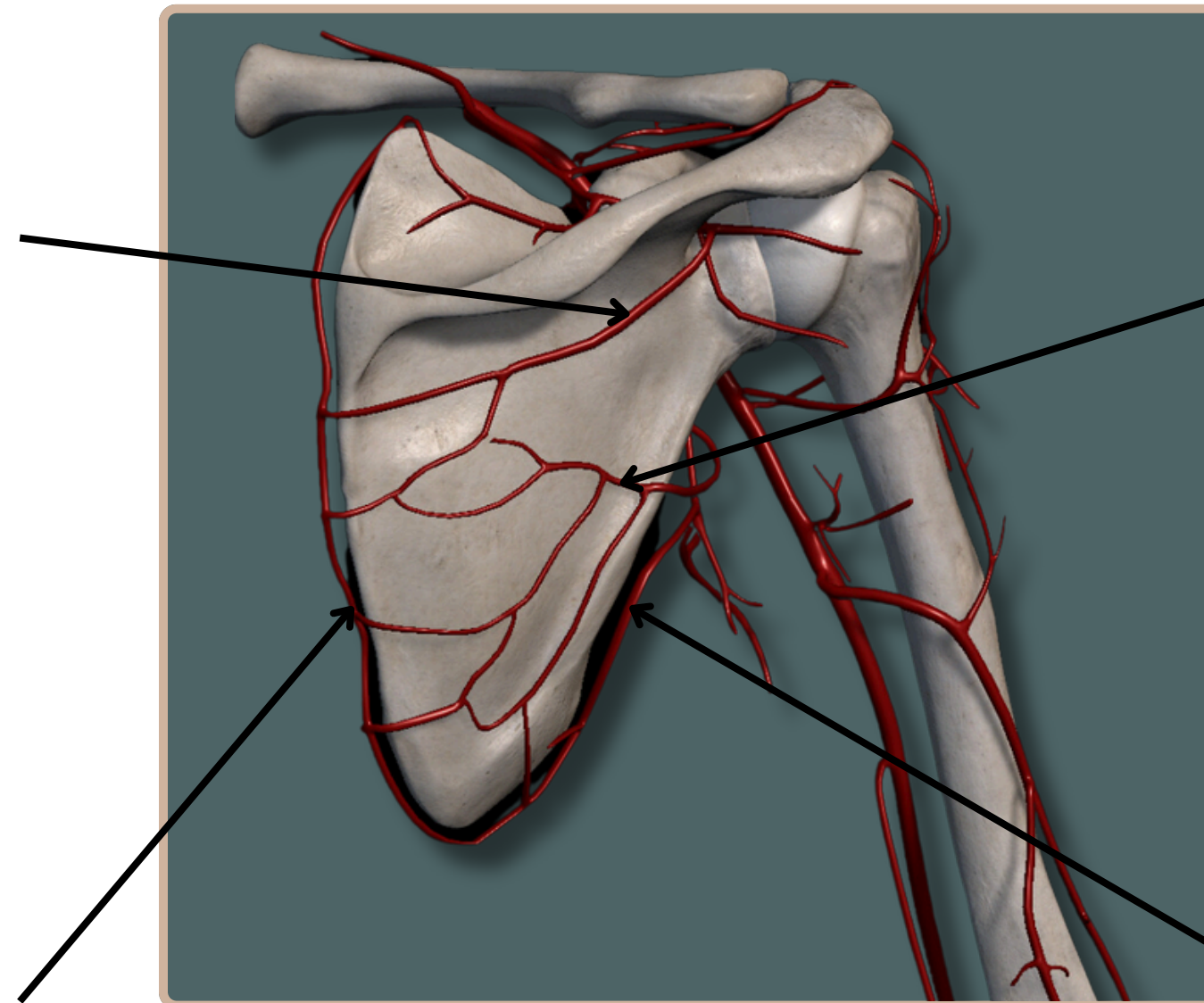
## ARTERIAL SYSTEM

### Suprascapular Artery

A Branch From The First Part of Subclavian Artery (Thyrocervical Trunk)

### Dorsal Scapular Artery

A Branch From The Subclavian Artery



### Circumflex Scapular Artery

A Branch From Subscapular Artery Which Is A Branch From The Third Part of Axillary Artery

### Thoracodorsal Artery

A Branch From Subscapular Artery Which Is A Branch From The Third Part of Axillary Artery

## Anastomosis Around The Scapula

## Posterior View



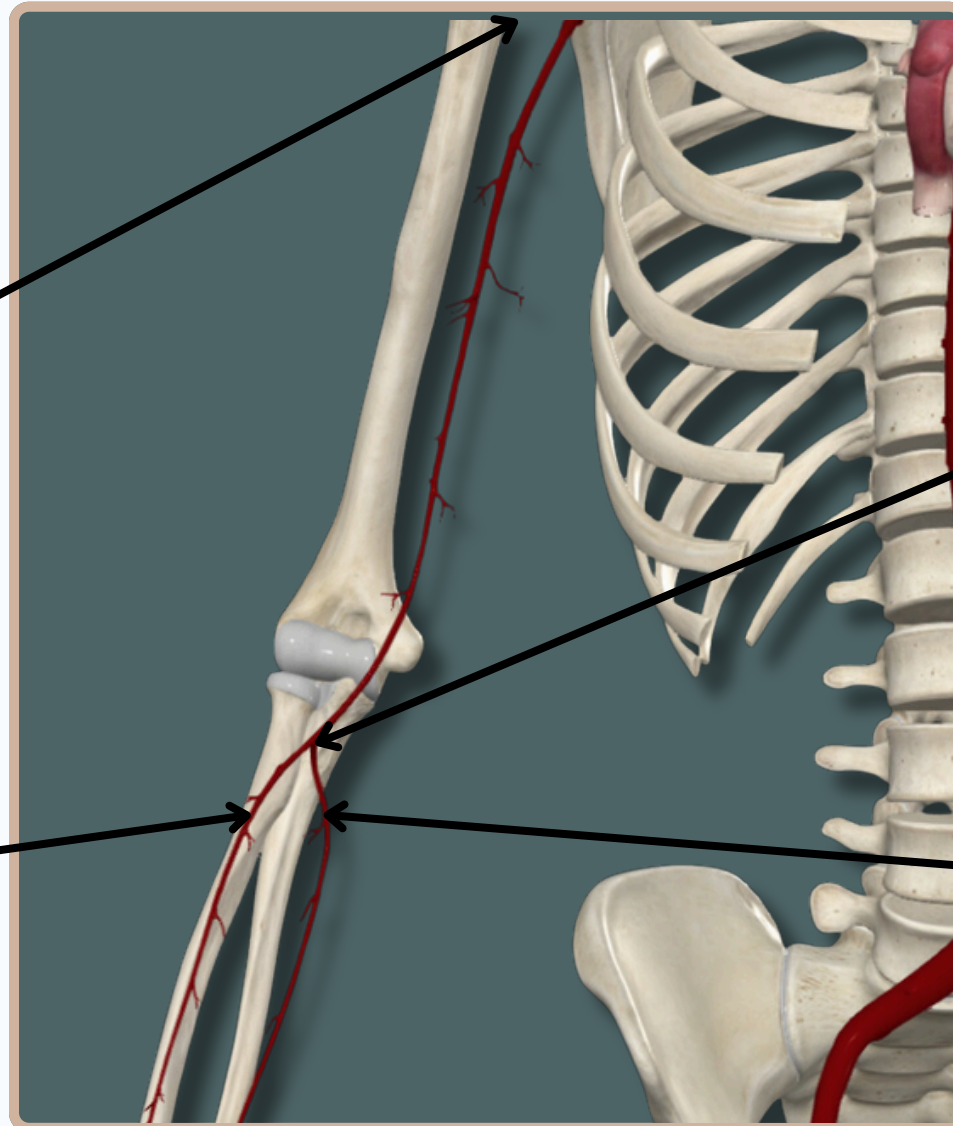
# BLOOD VESSELS



## ARTERIAL SYSTEM

### Brachial Artery

Begins As A continuation From The Axillary Artery **At The Lower Margin of The Teres Major Muscle**



### Brachial Artery

Ends **At The Level of The Neck of Radius** by Dividing Into Radial And Ulnar Arteries

### Radial Artery

### Ulnar Artery

### Anterior View



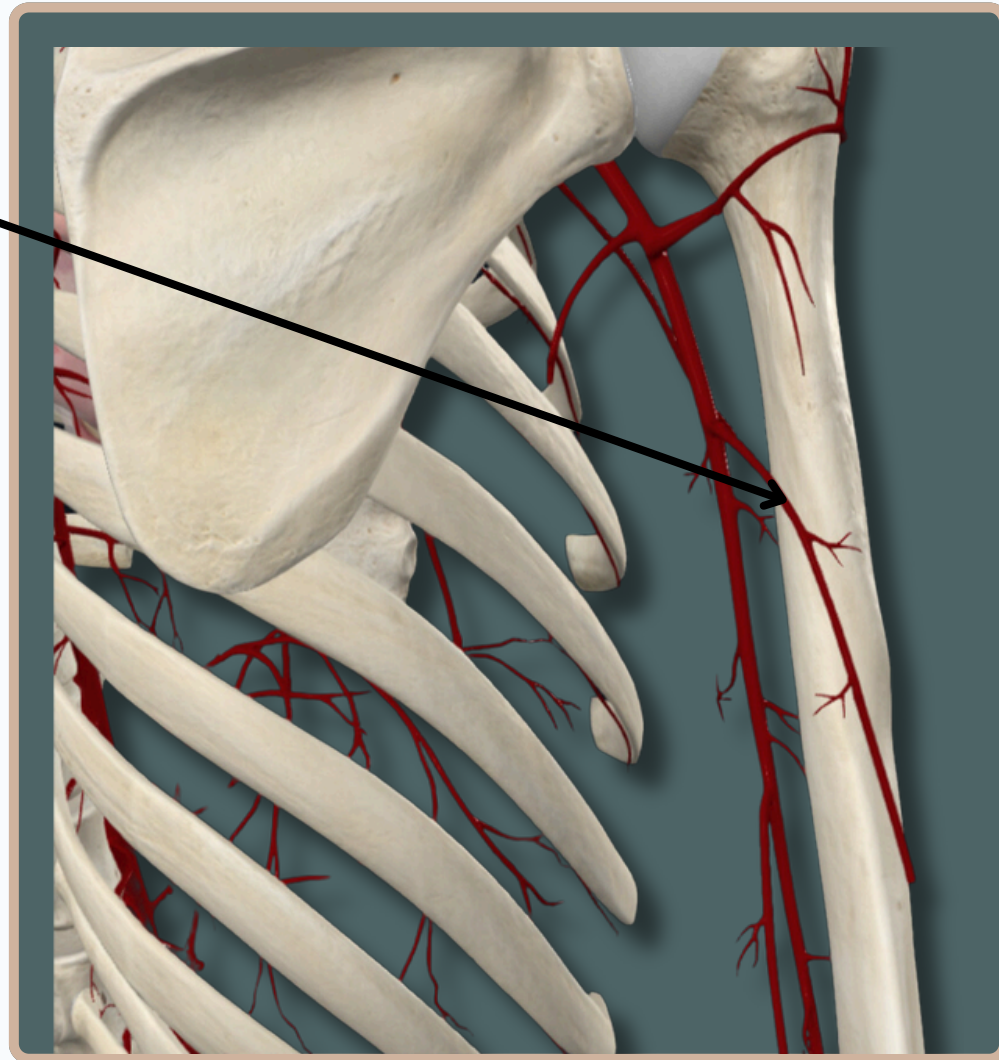
# BLOOD VESSELS



## ARTERIAL SYSTEM

### Deep Brachial Artery

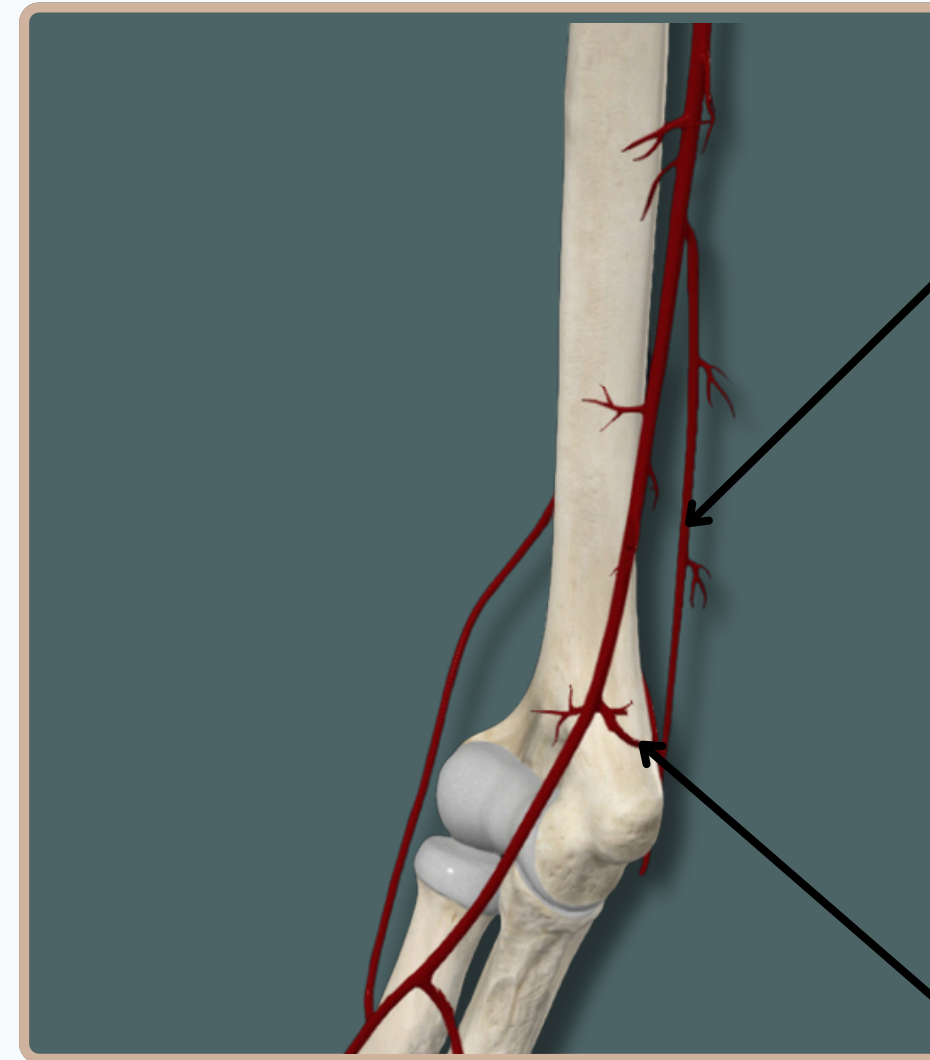
A Branch of Brachial Artery



Posterior View

### Superior Ulnar Collateral Artery

A Branch of Brachial Artery



### Inferior Ulnar Collateral Artery

A Branch of Brachial Artery

Anterior View





# BLOOD VESSELS

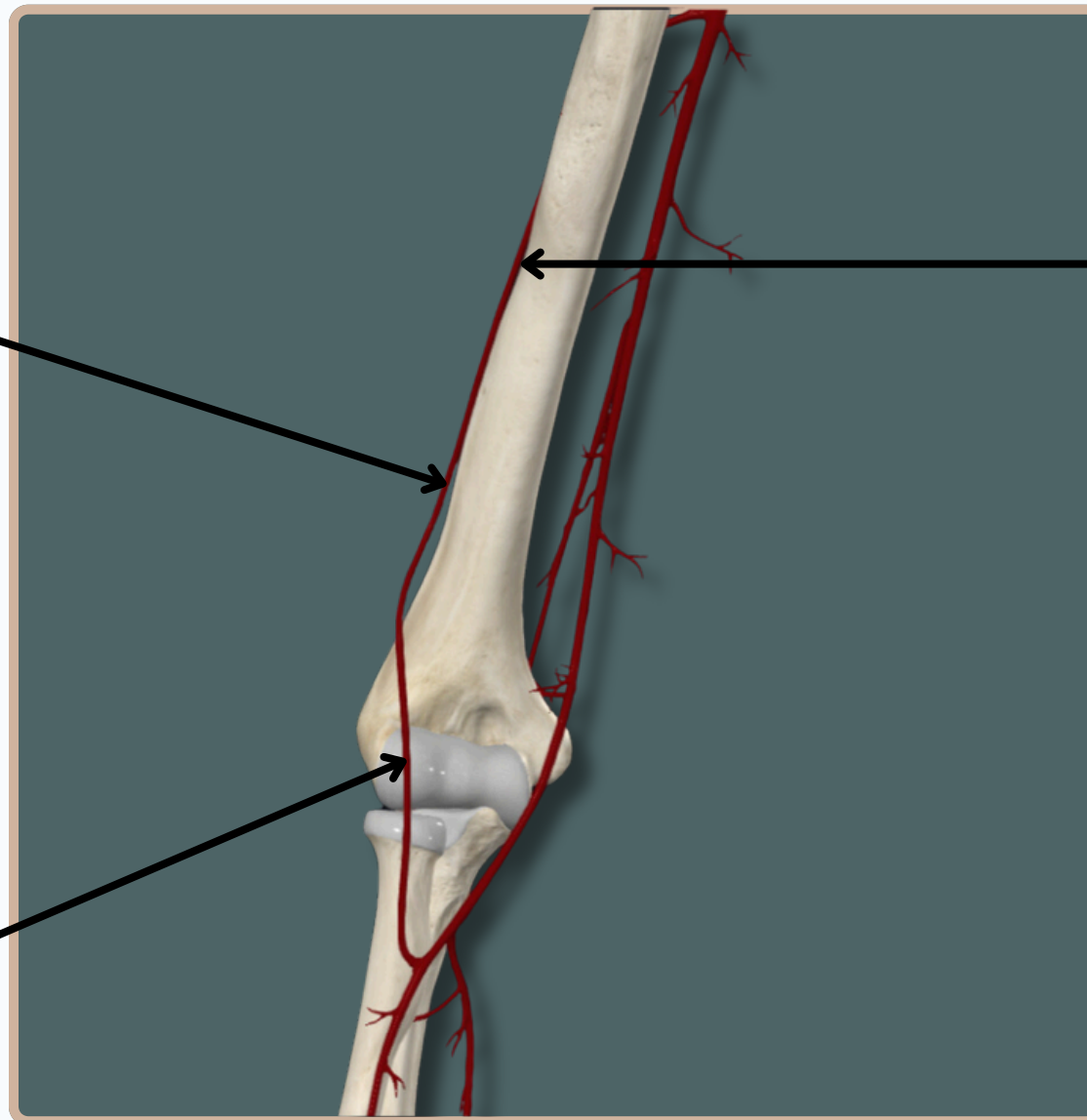


## ARTERIAL SYSTEM

**Radial Collateral Artery**  
A Branch of Deep Brachial Artery

**Deep Brachial Artery**  
A Branch of Brachial Artery

**Radial Recurrent Artery**  
A Branch of Radial Artery



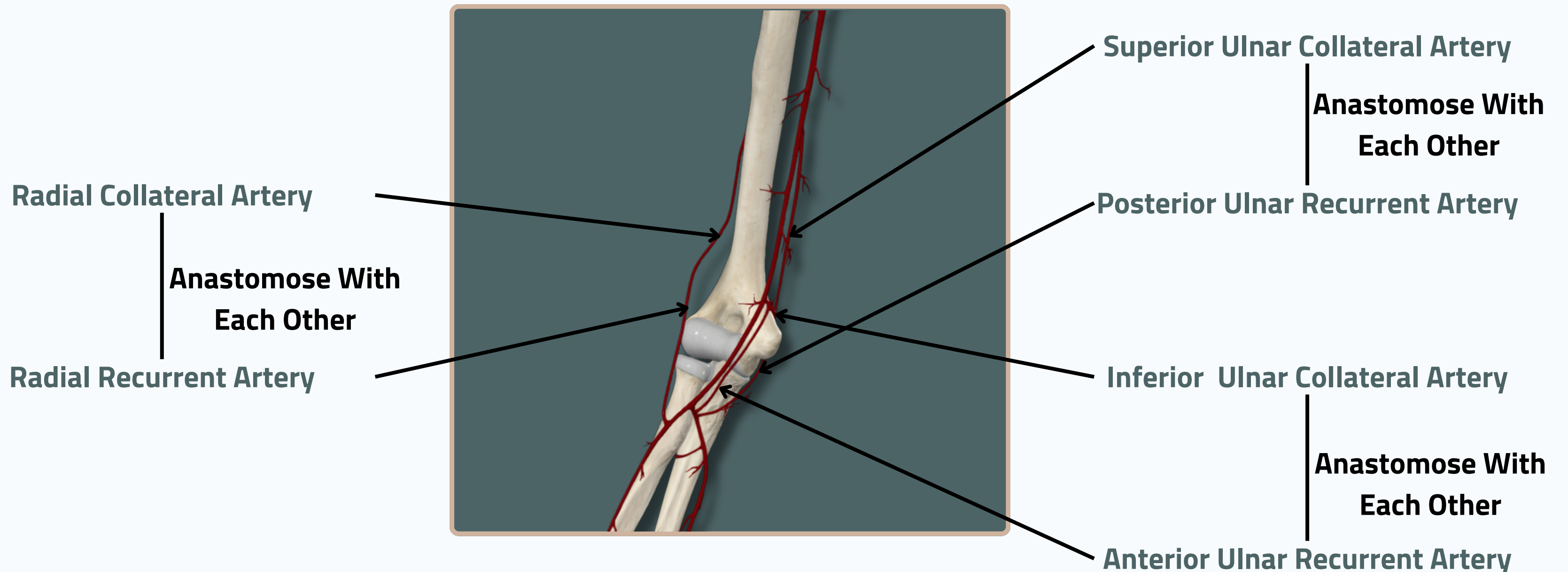
**Anterior View**



# BLOOD VESSELS



## ARTERIAL SYSTEM



**Anastomosis Around The Elbow Joint**

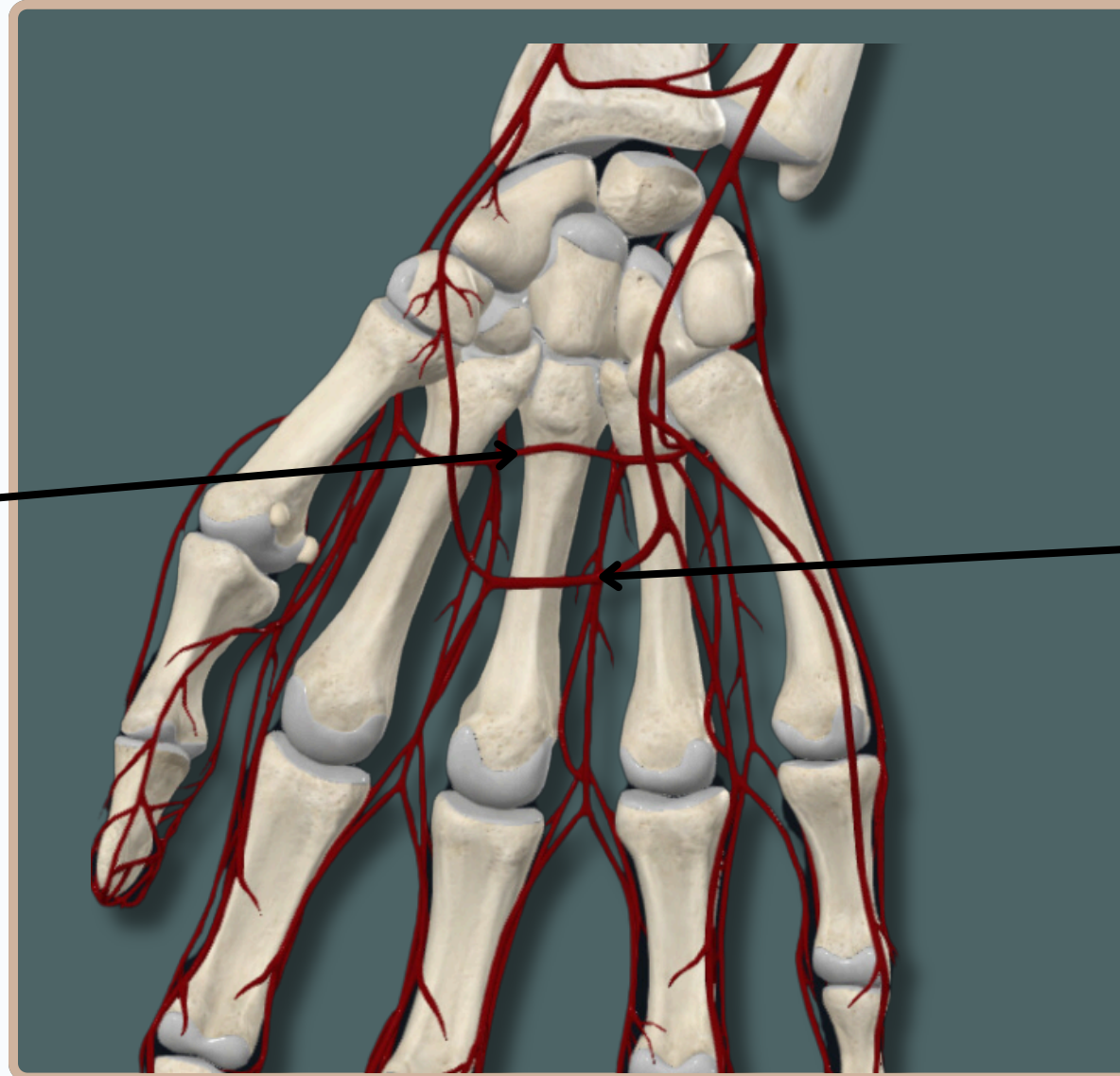
**Anterior View**

# BLOOD VESSELS

## ARTERIAL SYSTEM



**Deep Palmar Arch**



**Superficial Palmar Arch**

**Anterior View**

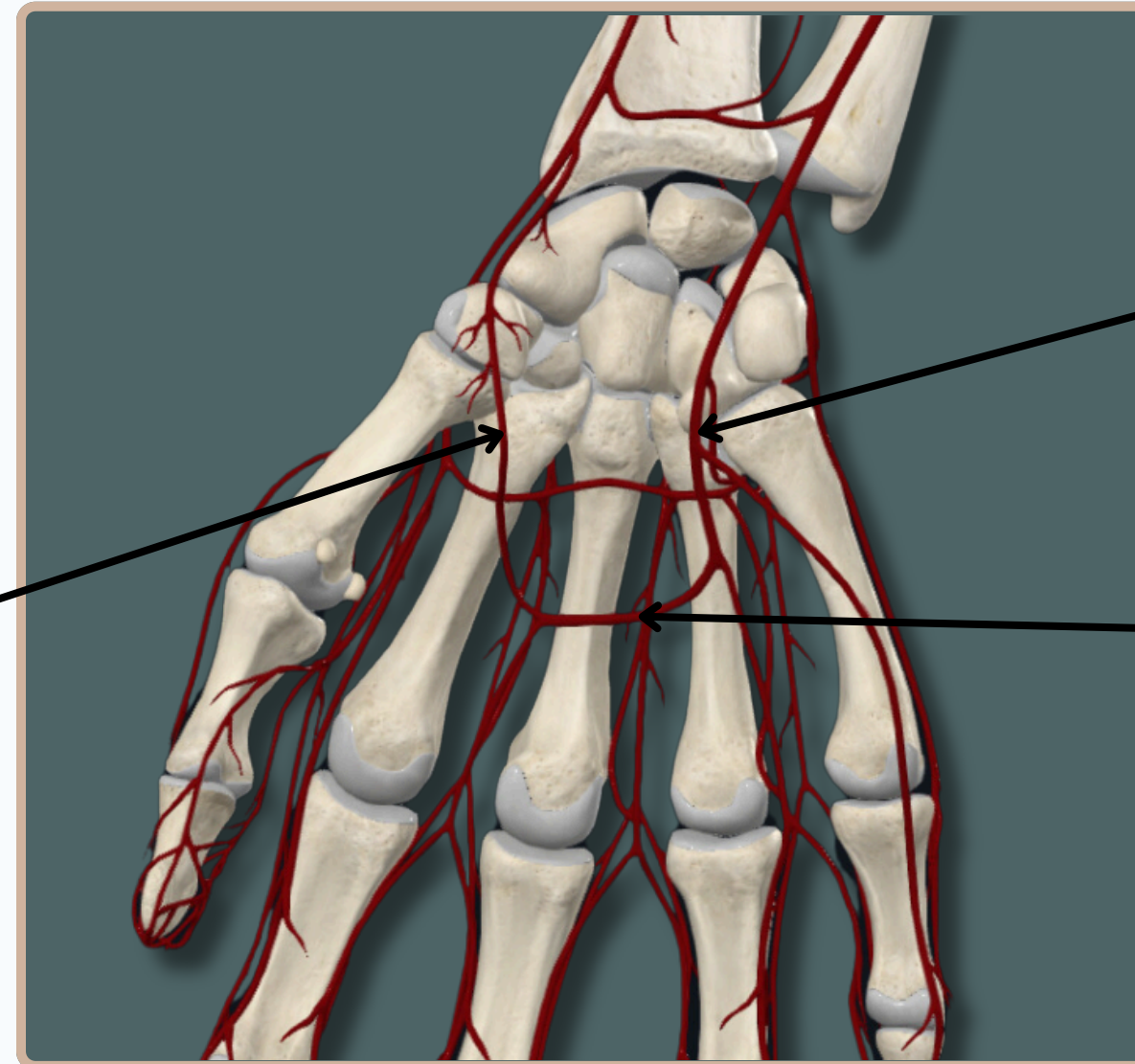


# BLOOD VESSELS



## ARTERIAL SYSTEM

**Superficial Palmar  
Branch of Radial Artery**



**Ulnar Artery**

**Superficial Palmar Arch**

**Anterior View**

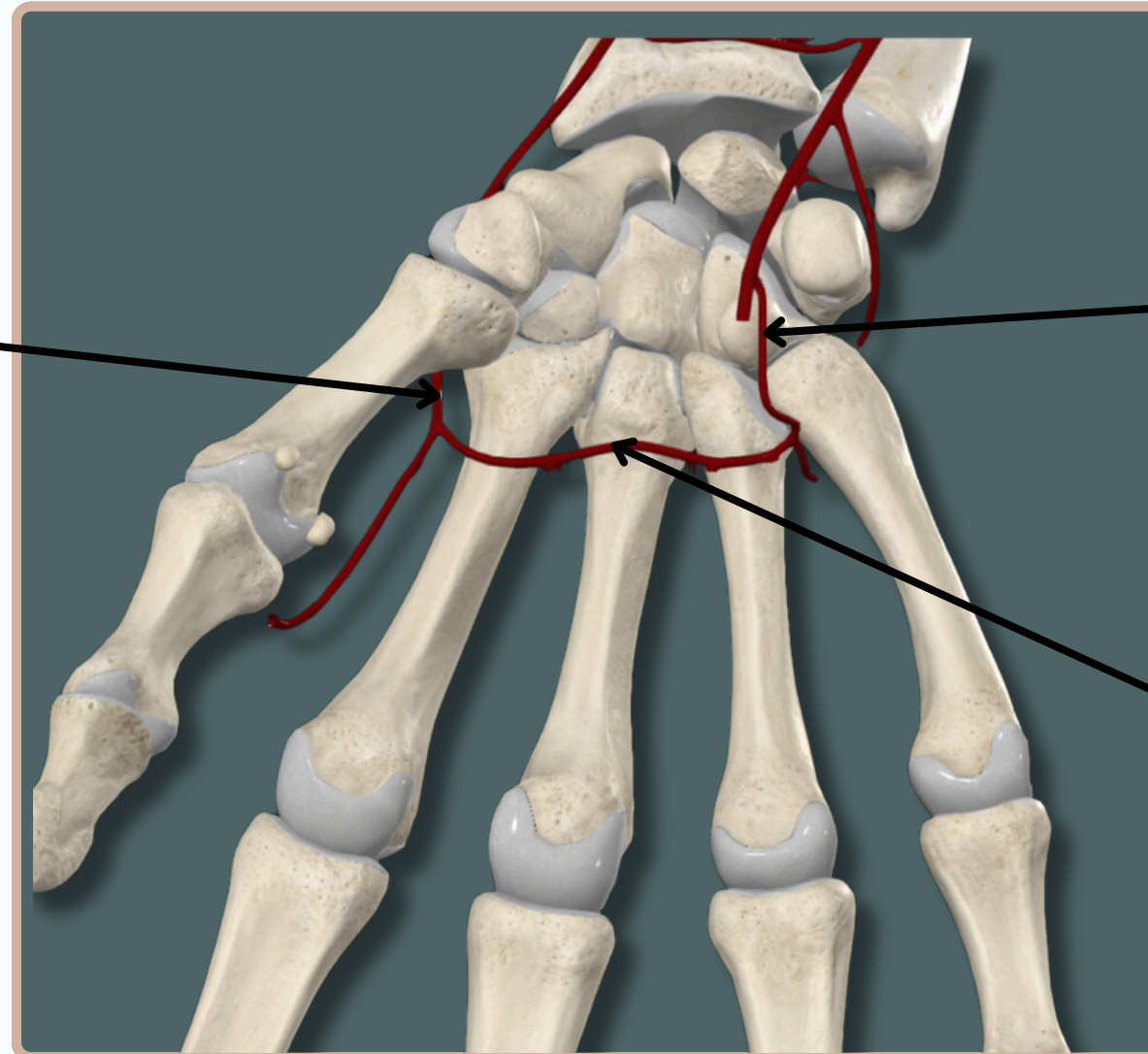


# BLOOD VESSELS



## ARTERIAL SYSTEM

**Radial Artery**



**Deep Palmar Branch of Ulnar Artery**

**Deep Palmar Arch**

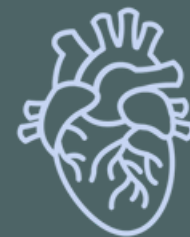**Anterior View**

# THANK YOU

EDITED BY



SATURN  
MEDIC



ARECH

© ALL COPYRIGHT ARE RESERVED FOR  
SATURN MEDIC AND ARECH

[WWW.SATURNMEDIC.COM](http://WWW.SATURNMEDIC.COM)