

ANATOMY OF LOWER LIMB

PRACTICAL LECTURE - 16 - LYMPHATIC SYSTEM

EDITED BY



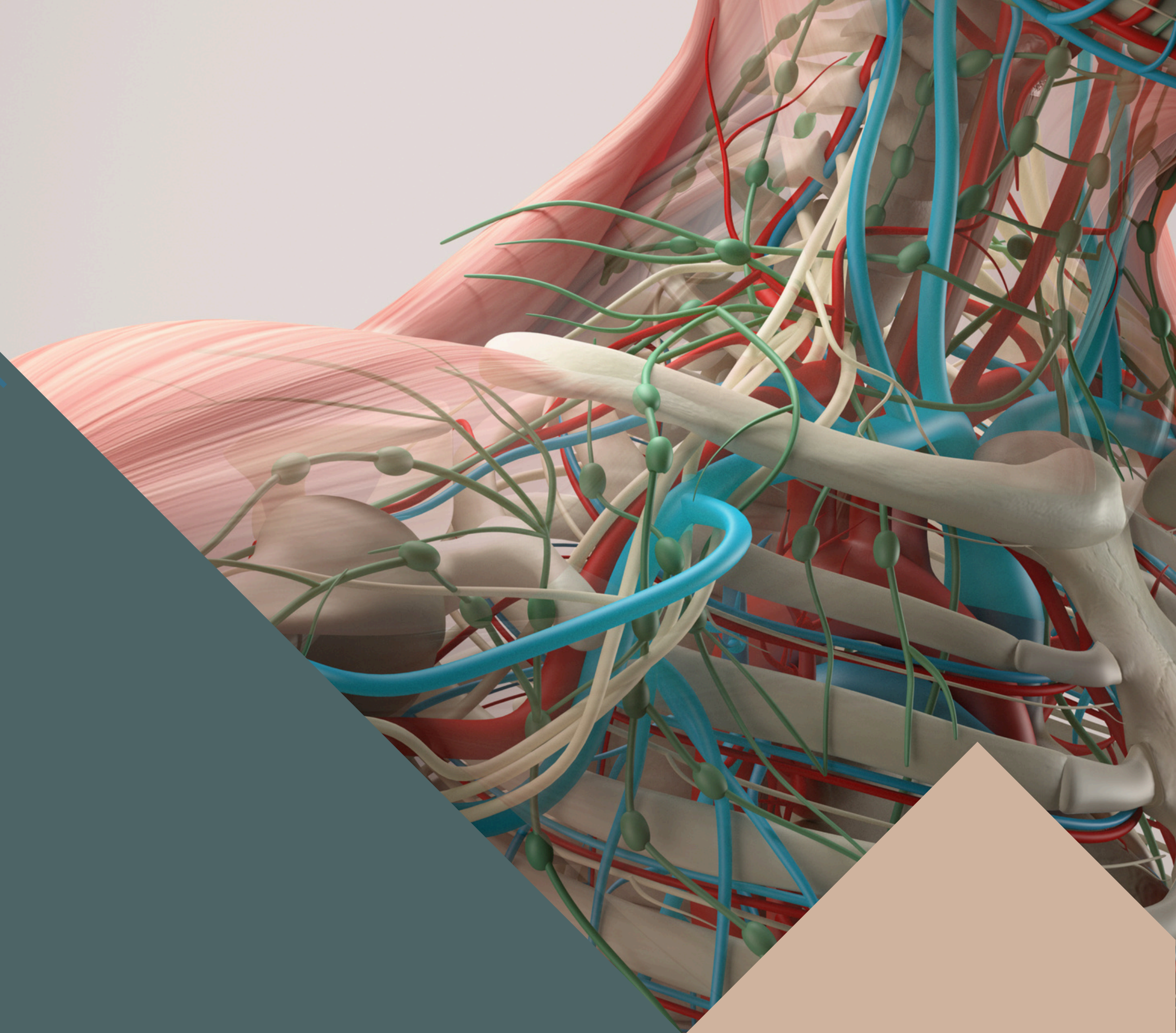
SATURN
MEDIC



ARECH

© ALL COPYRIGHT ARE RESERVED FOR
SATURN MEDIC AND ARECH

WWW.SATURNMEDIC.COM



LYMPHATIC SYSTEM

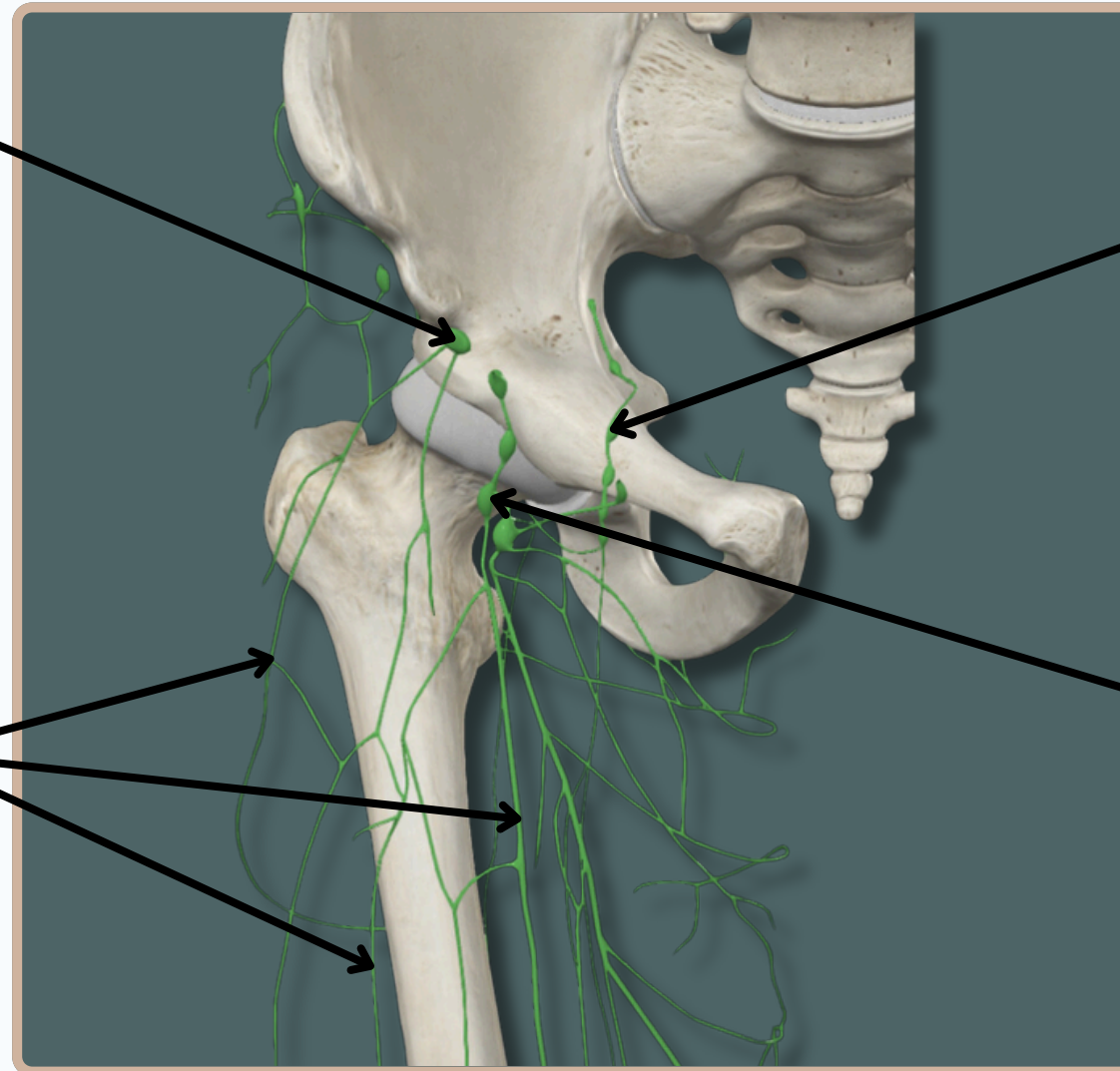


**Superolateral Superficial
Inguinal Nodes**

Deep Inguinal Nodes

**Anteromedial Superficial
Lymph Vessels**

**Inferior Superficial
Inguinal Nodes**

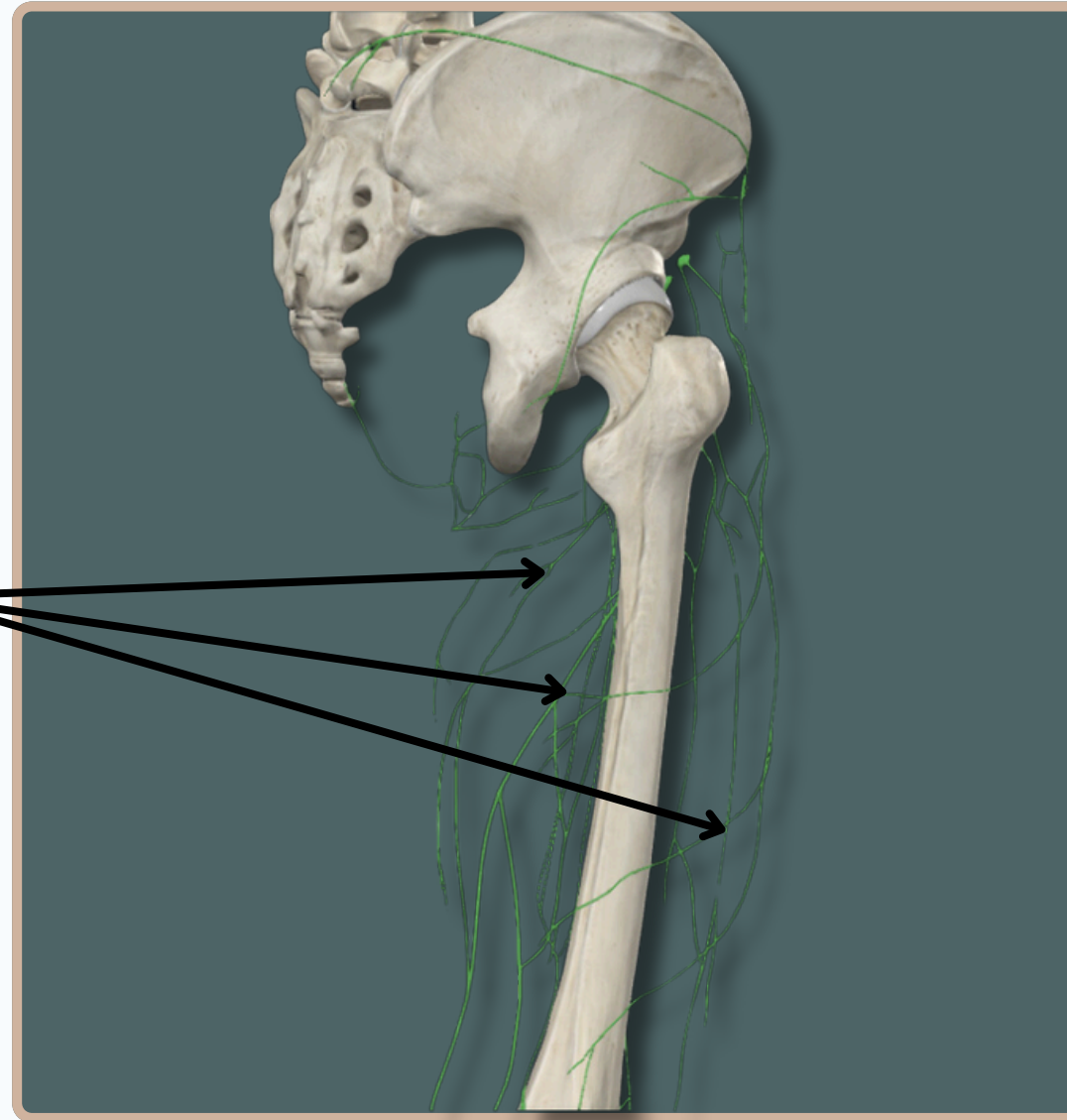


Anterior View

LYMPHATIC SYSTEM

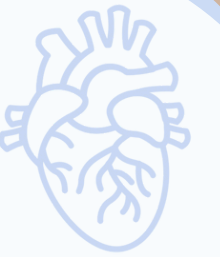

**Anteromedial Superficial
Lymph Vessels**

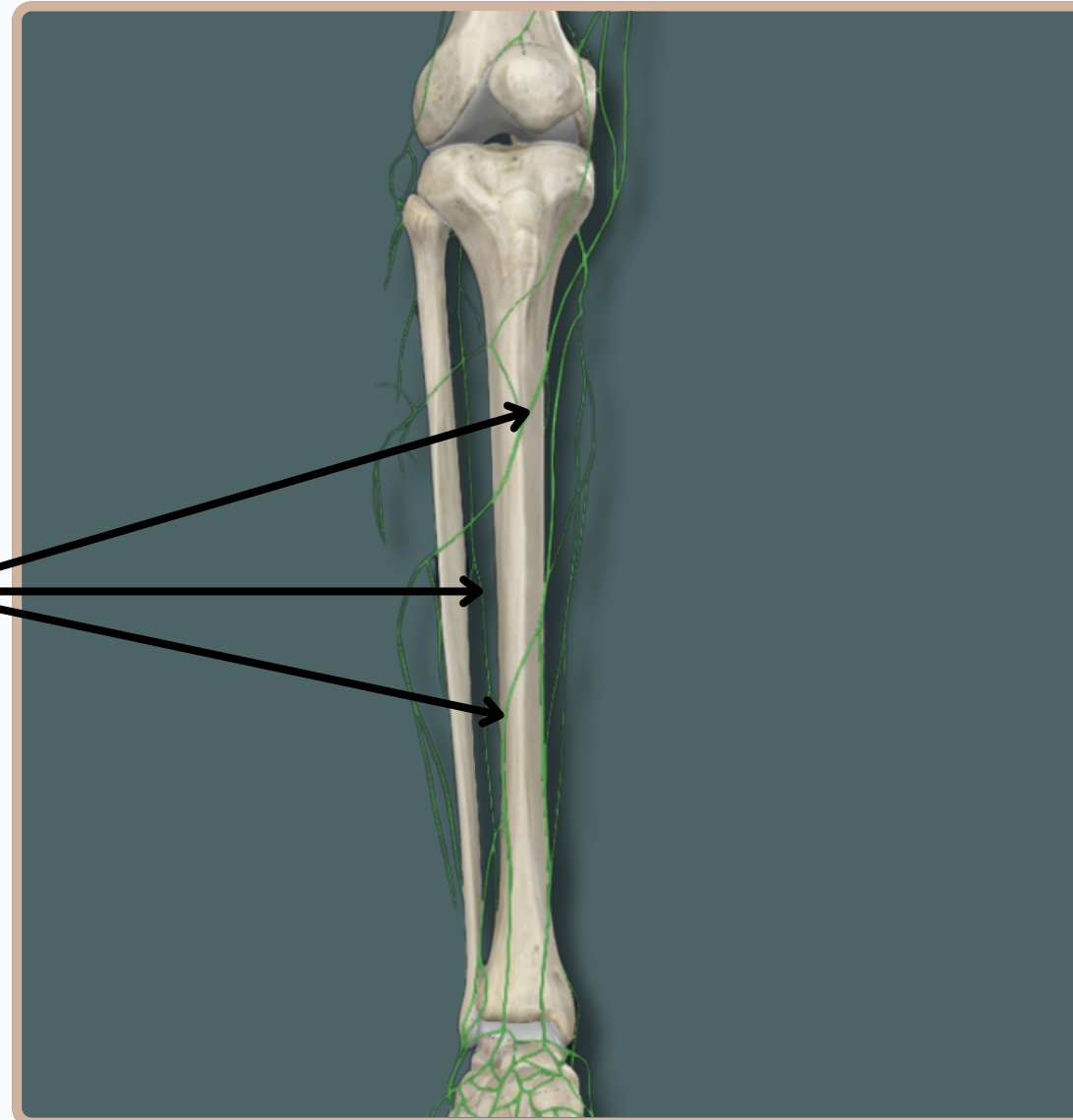


Posterior View

LYMPHATIC SYSTEM



**Anteromedial Superficial
Lymph Vessels**

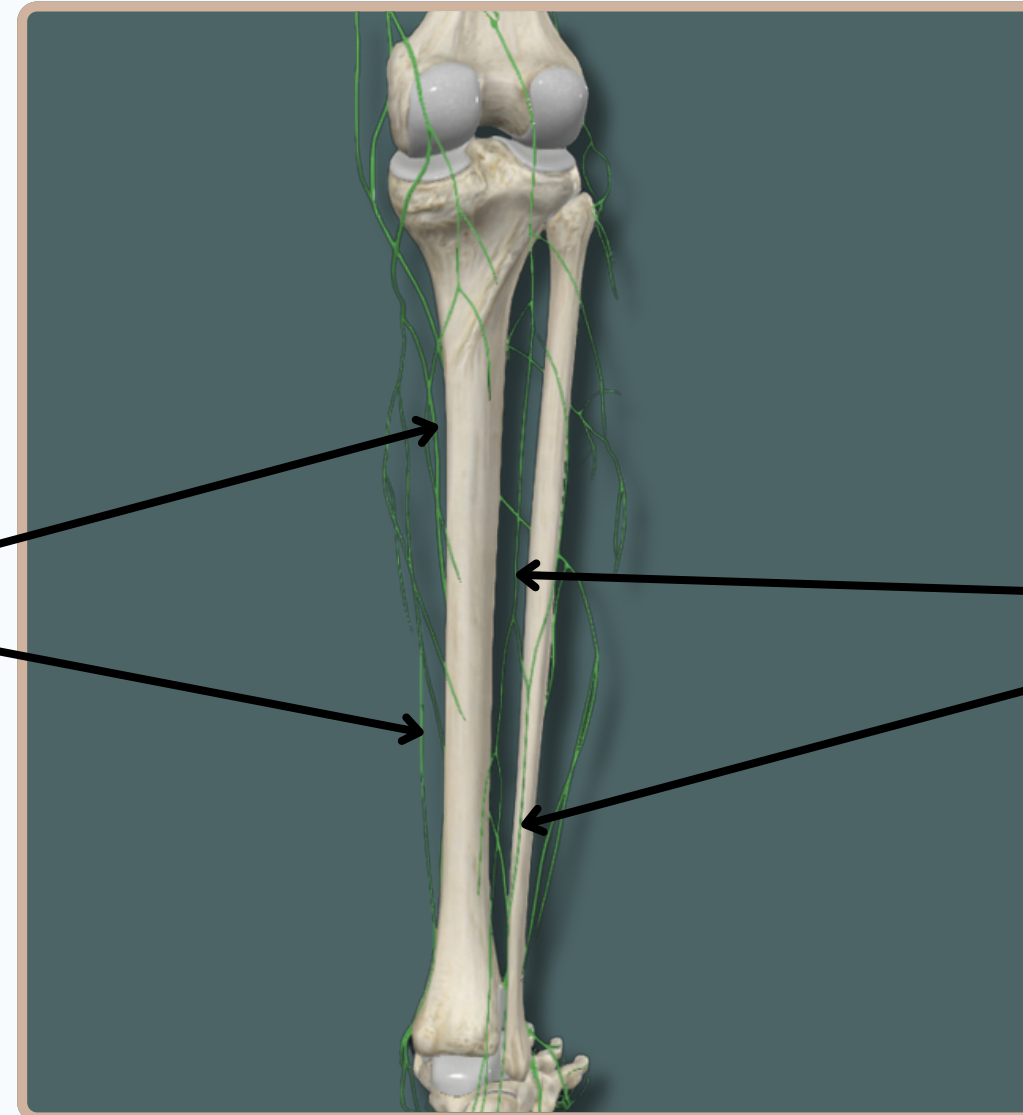


Anterior View

LYMPHATIC SYSTEM



**Anteromedial Superficial
Lymph Vessels**



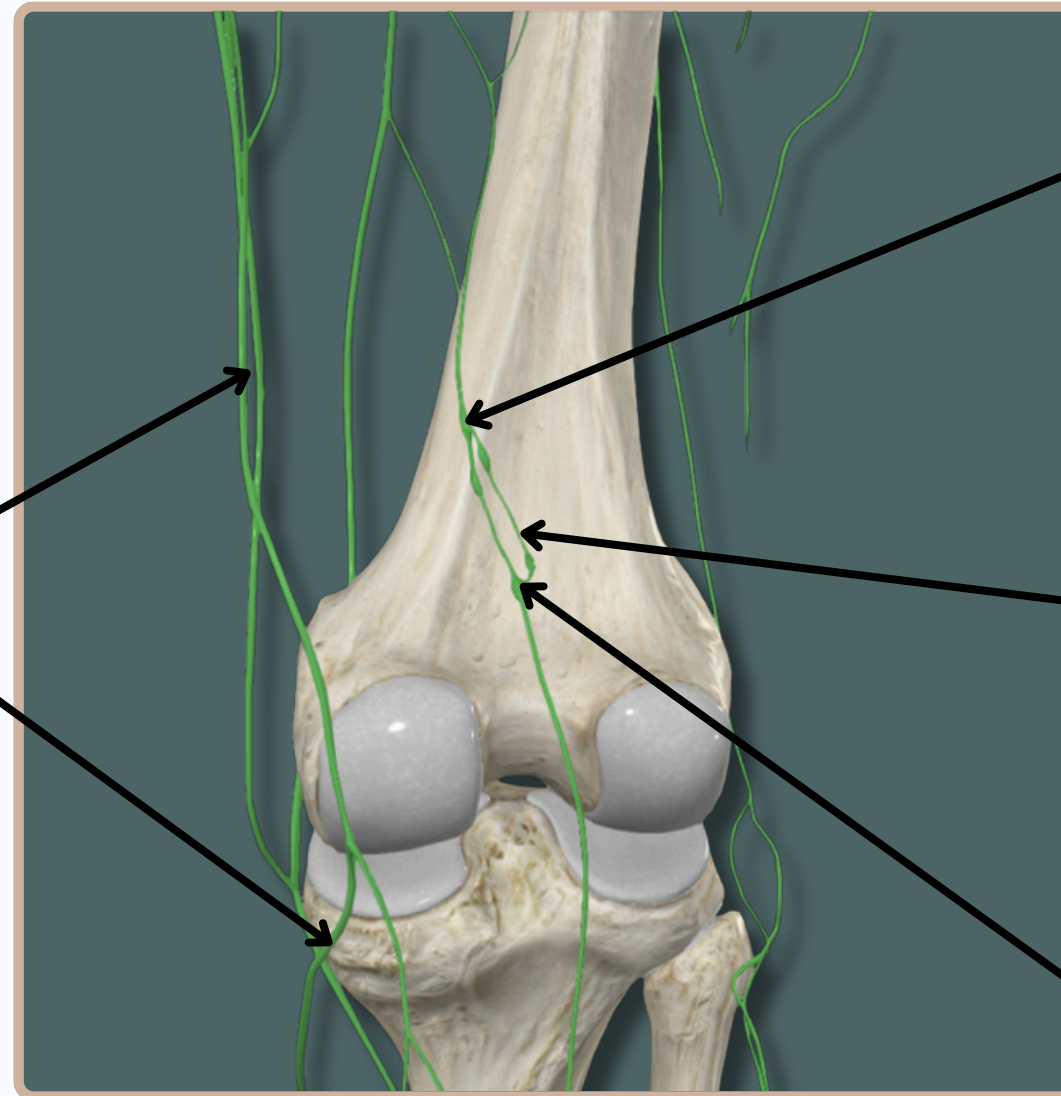
**Posterolateral Superficial
Lymph Vessels**

Posterior View

LYMPHATIC SYSTEM



**Anteromedial Superficial
Lymph Vessels**



Deep Popliteal Nodes

**Deep Lymph Vessels of
Lower Limb**

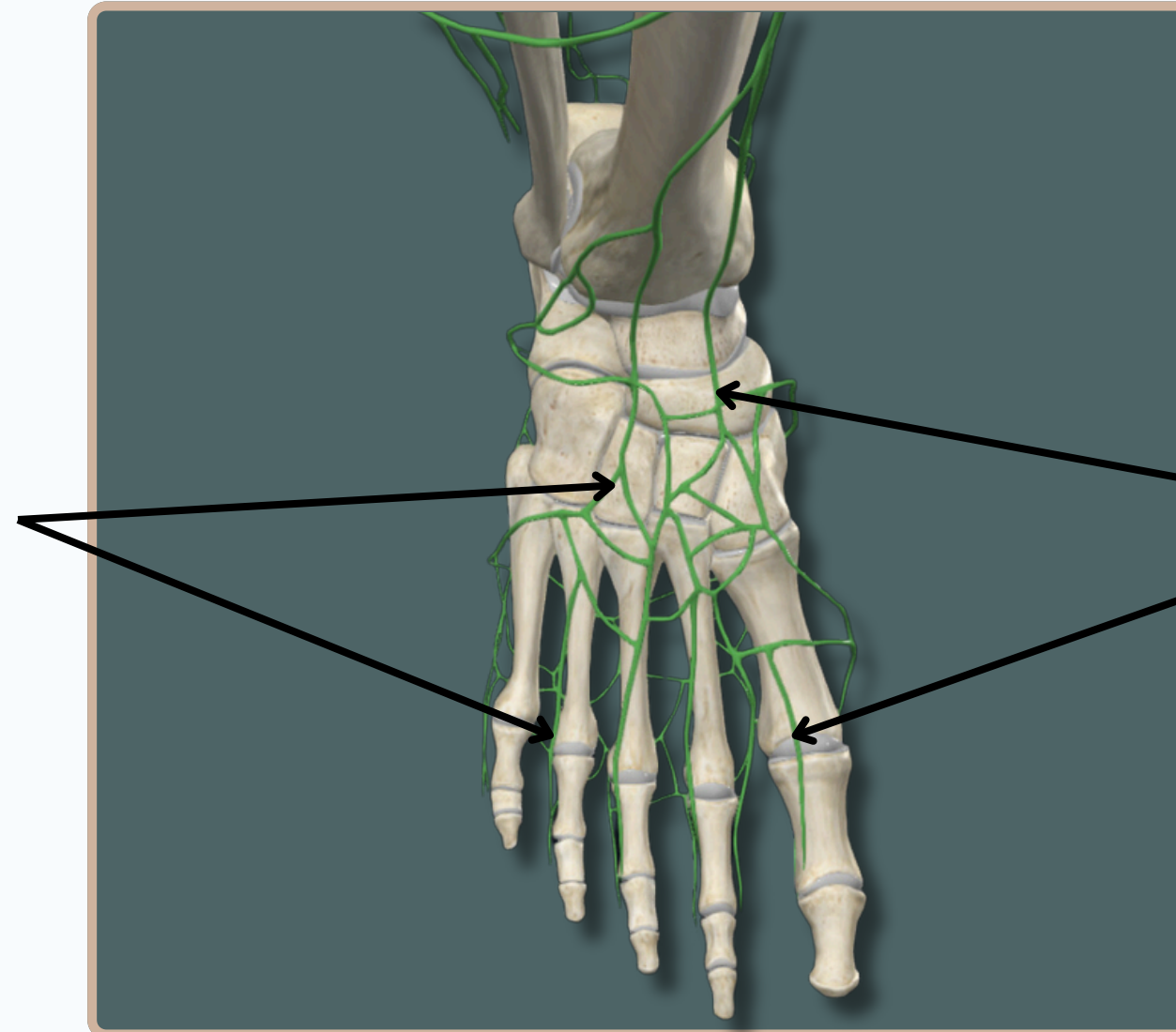
Superficial Popliteal Nodes

Posterior View

LYMPHATIC SYSTEM



**Posterolateral Superficial
Lymph Vessels**



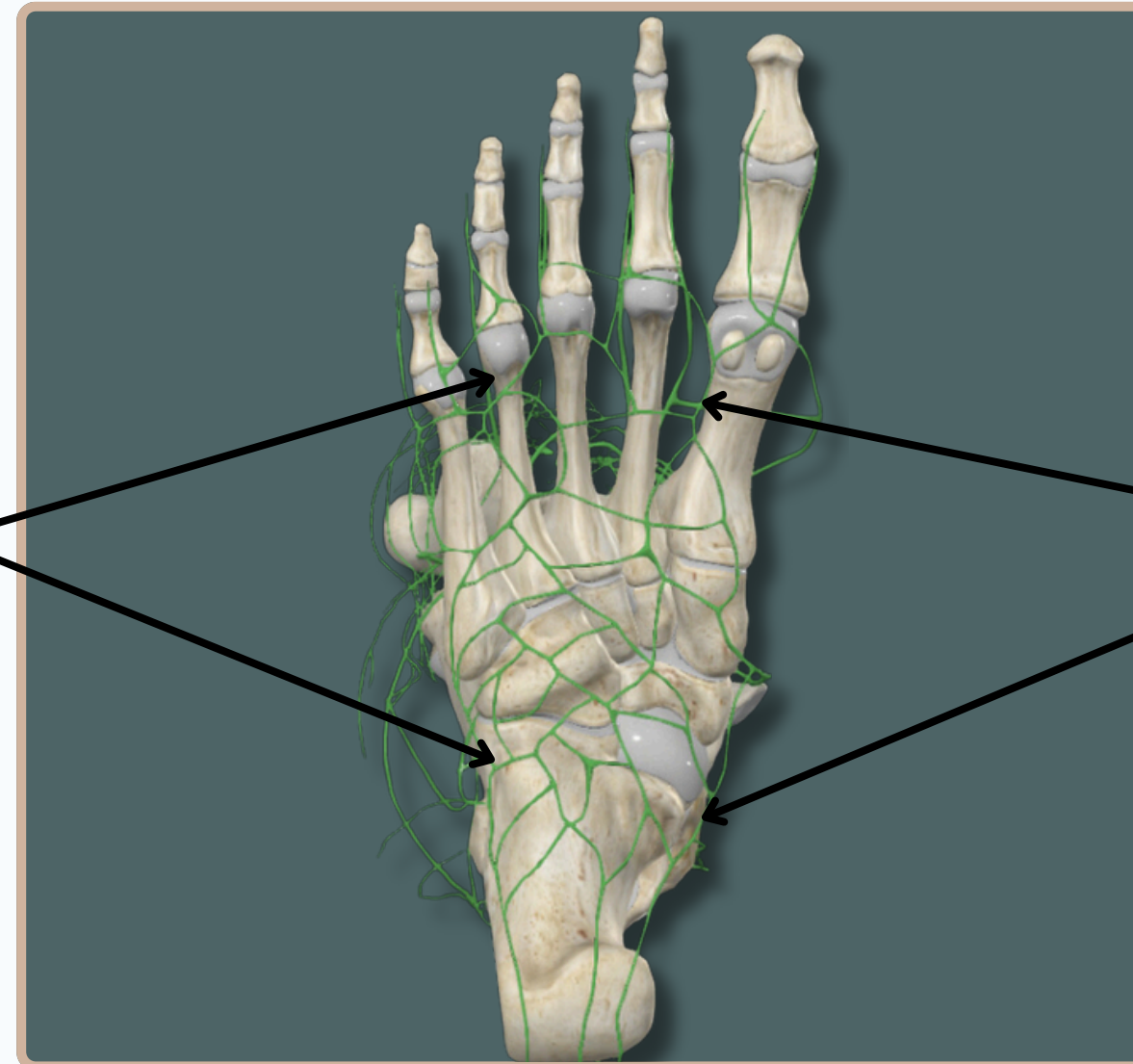
**Anteromedial Superficial
Lymph Vessels**

Superior View

LYMPHATIC SYSTEM



**Posterolateral Superficial
Lymph Vessels**



**Anteromedial Superficial
Lymph Vessels**

Inferior View

THANK YOU

EDITED BY



SATURN
MEDIC



ARECH

© ALL COPYRIGHT ARE RESERVED FOR
SATURN MEDIC AND ARECH

WWW.SATURNMEDIC.COM