

ANATOMY OF LOWER LIMB

PRACTICAL LECTURE - 6 -

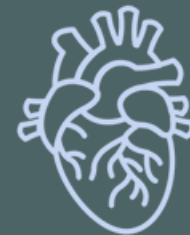MUSCLES / PART 2

MEDIAL ADDUCTOR MUSCLES OF THE THIGH

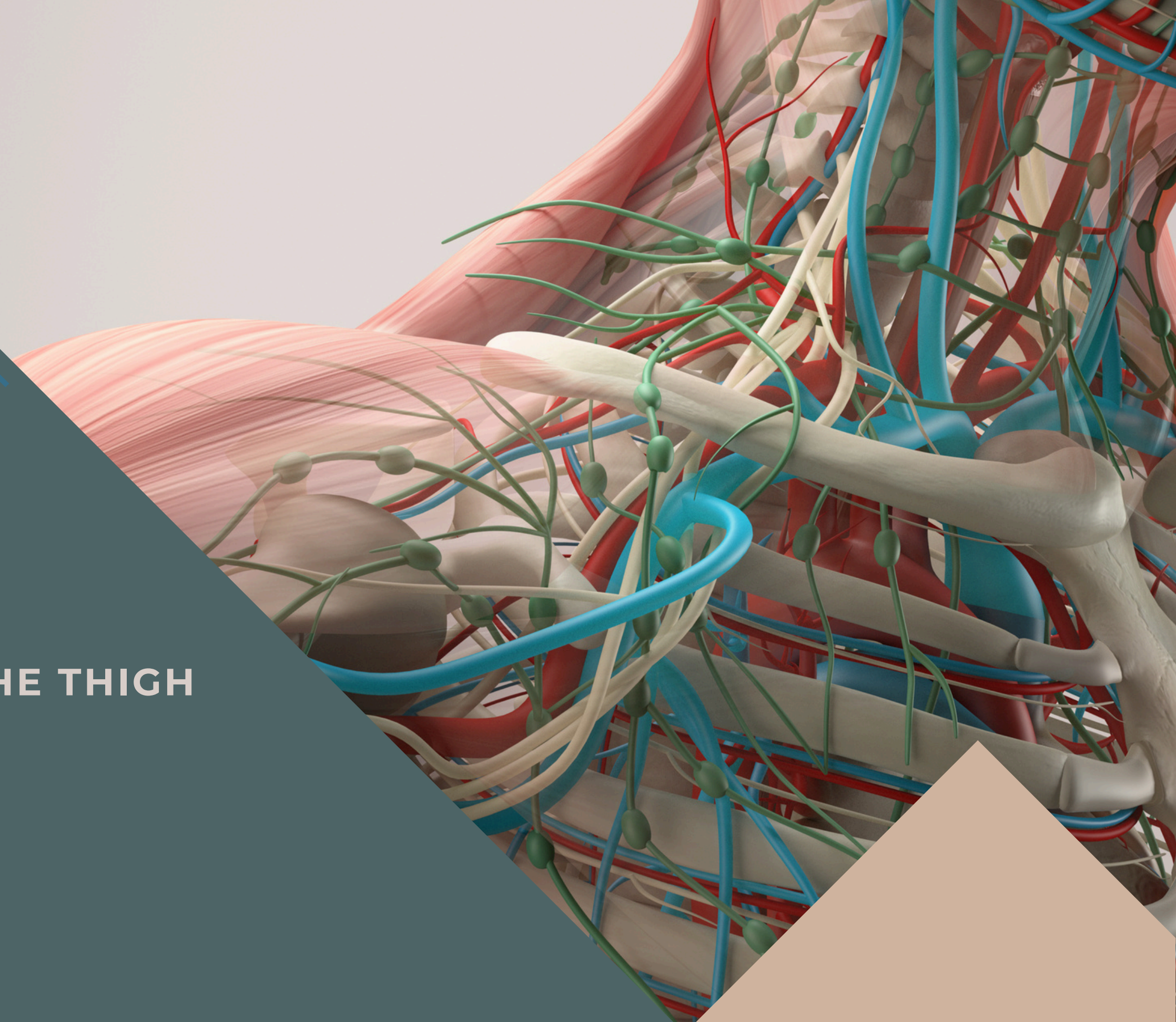
EDITED BY



SATURN
MEDIC



ARECH



ALL COPYRIGHT ARE RESERVED FOR
SATURN MEDIC AND ARECH

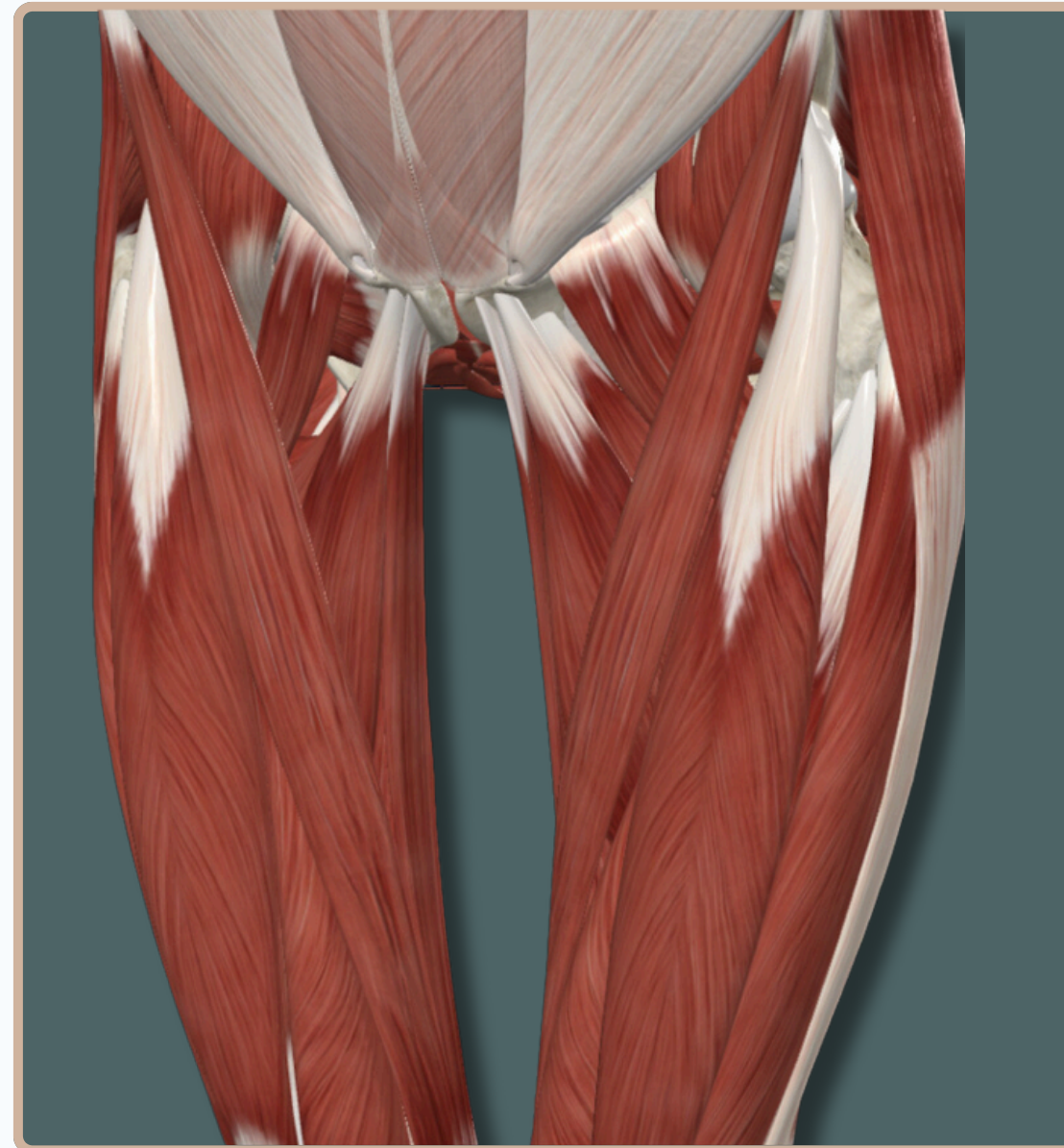
WWW.SATURNMEDIC.COM



-All The Muscles of The **Medial Compartment of The Thigh** Are Responsible For :

- **Adduction** of the **Thigh**

-All The Muscles of The **Medial Compartment of The Thigh** Are Supplied By **Obturator Nerve**

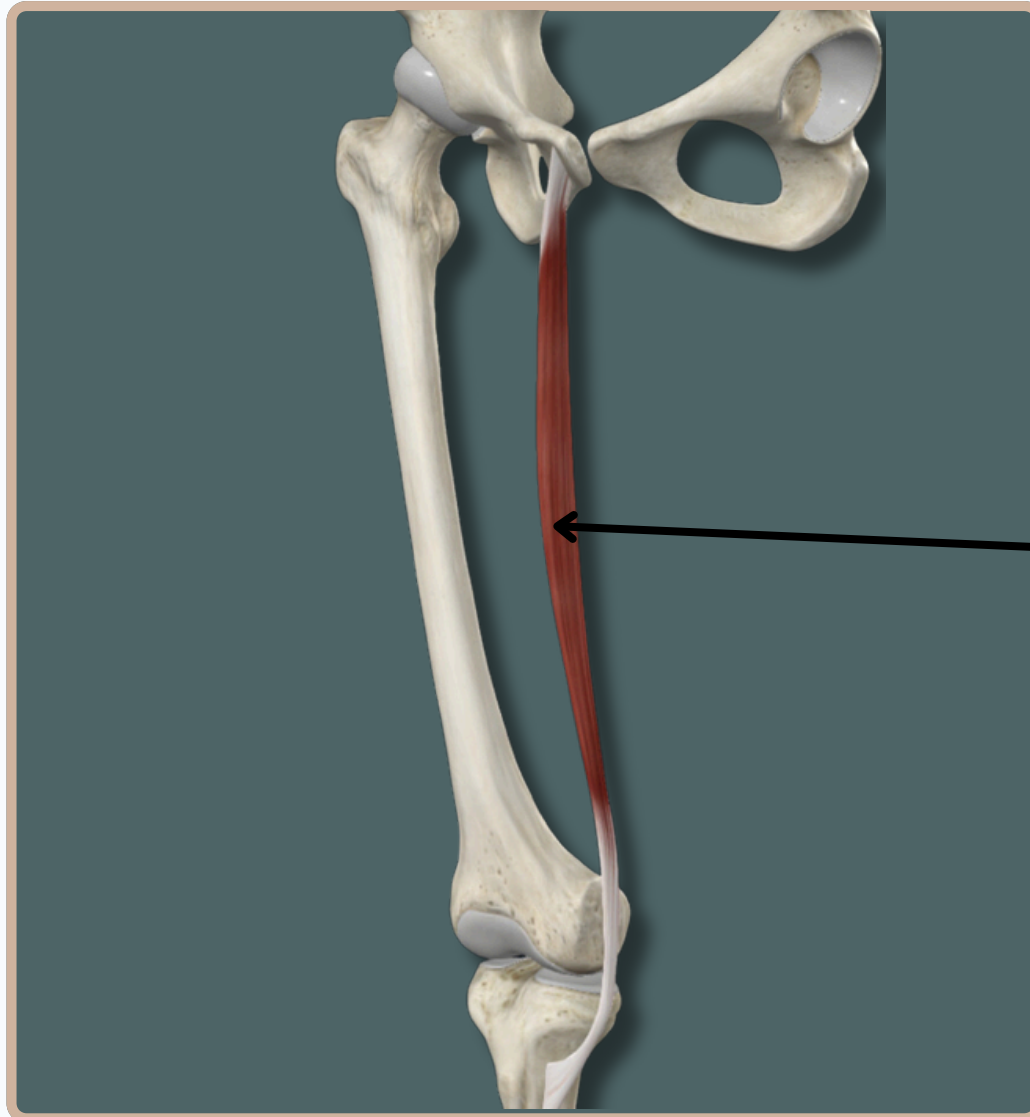


Medial View

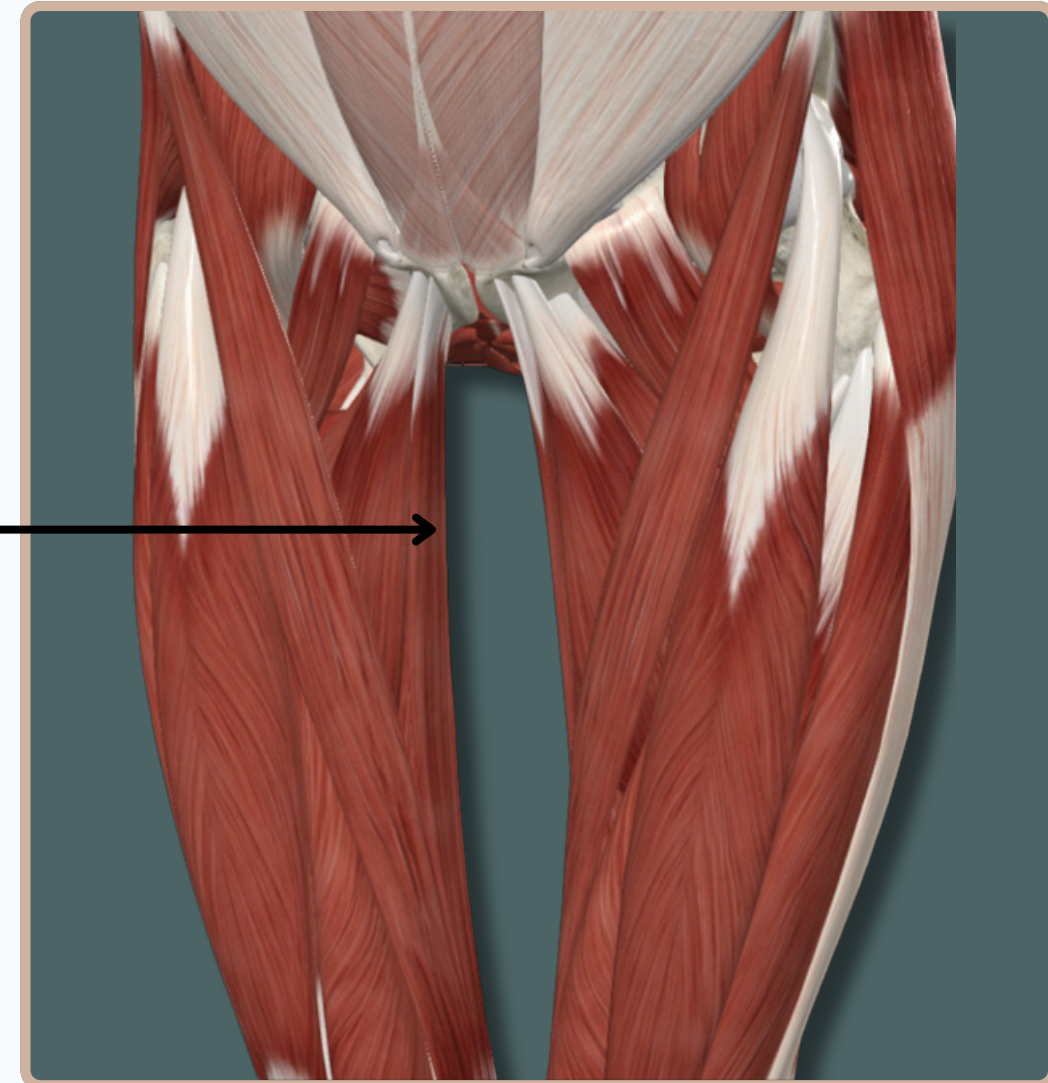
MEDIAL ADDUCTOR MUSCLES OF THE THIGH

GRACILIS

Origin : Body of **pubis** and inferior **pubic** ramus



Gracilis



Insertion : Medial aspect of proximal part of **tibia**

Action :

- Flexes** and **Medially** Rotates leg at **knee** joint
- Assists in **Adduction** of thigh at **Hip** joint

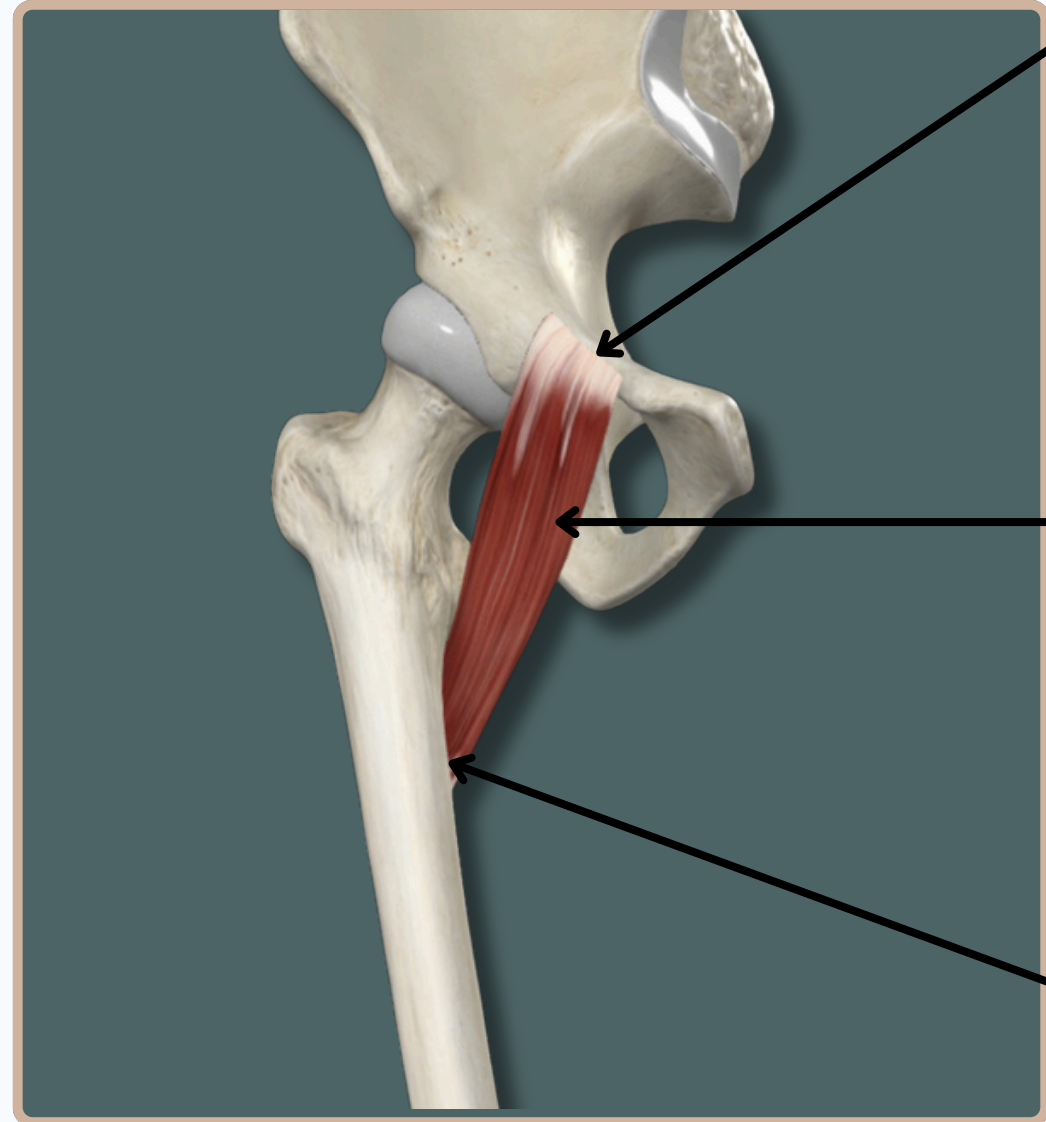
Nerve Supply :
Obturator Nerve

Medial View

MEDIAL ADDUCTOR MUSCLES OF THE THIGH

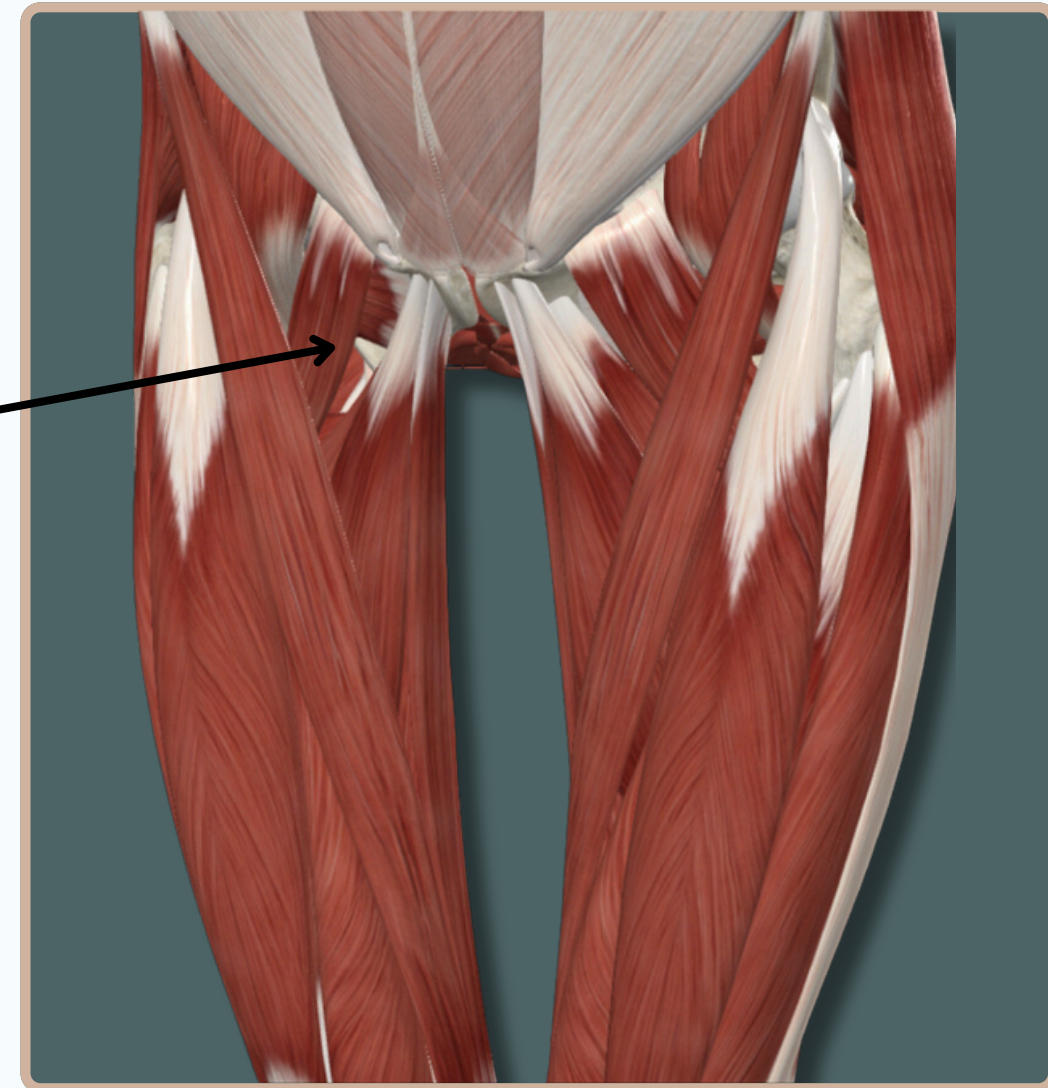
PECTINEUS

Origin : Superior **pubic** ramus



Pectineus

Insertion : Pectineal line of **femur**



Action :

-Adducts and **Flexes** thigh at **Hip** joint

Nerve Supply :

Obturator And **Femoral Nerve**

Medial View

MEDIAL ADDUCTOR MUSCLES OF THE THIGH

ADDUCTOR MAGNUS

Origin : -Inferior **pubic** ramus

-Ramus of **ischium**

-**Ischial** tuberosity

Insertion : -**Gluteal** tuberosity

-**linea** aspera

-medial **supracondylar** line

-**adductor** tubercle

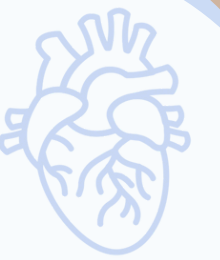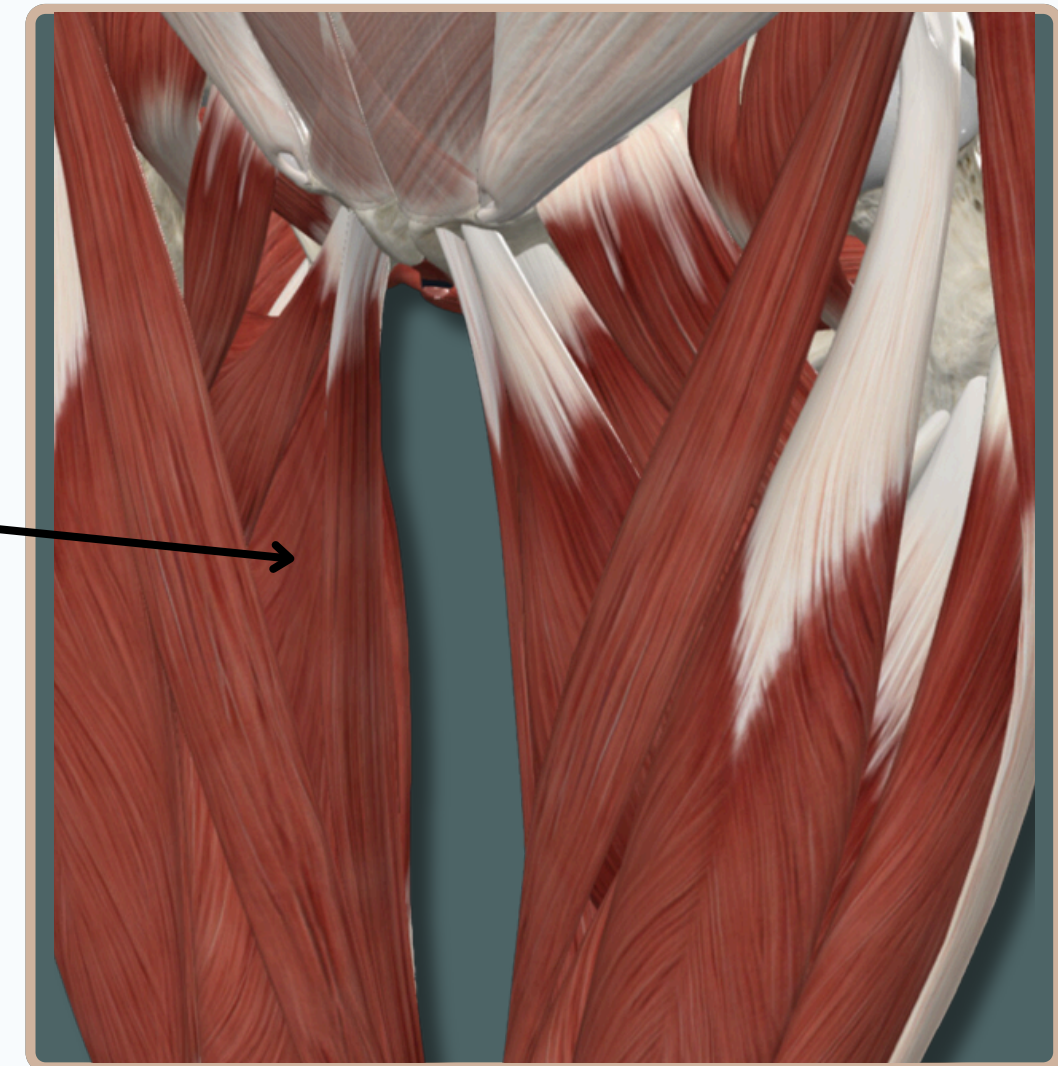
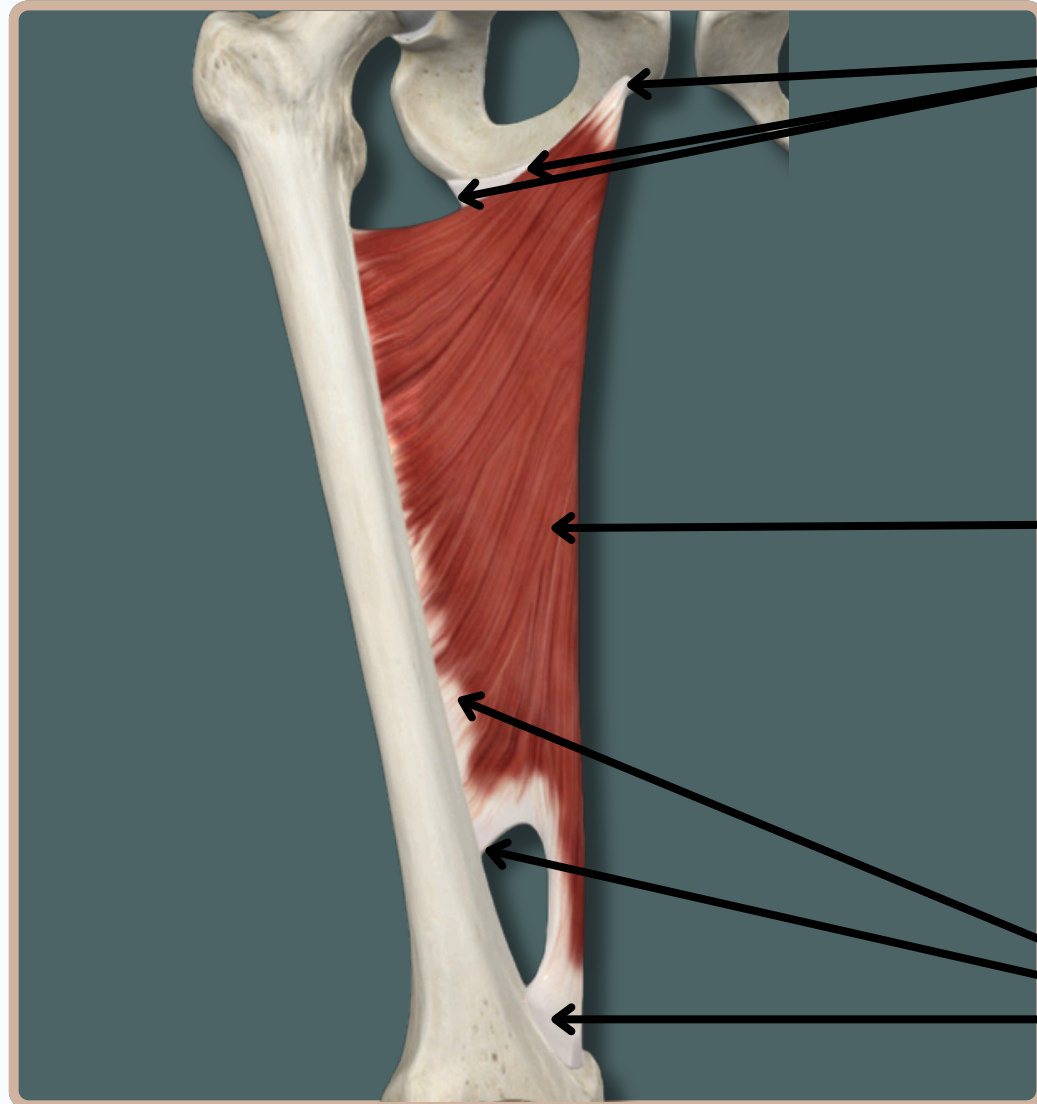
Action :

-**Adducts, Flexes,** and **Extends**
thigh at hip joint

Nerve Supply :

-**Obturator Nerve**
-tibial division of **Sciatic Nerve**

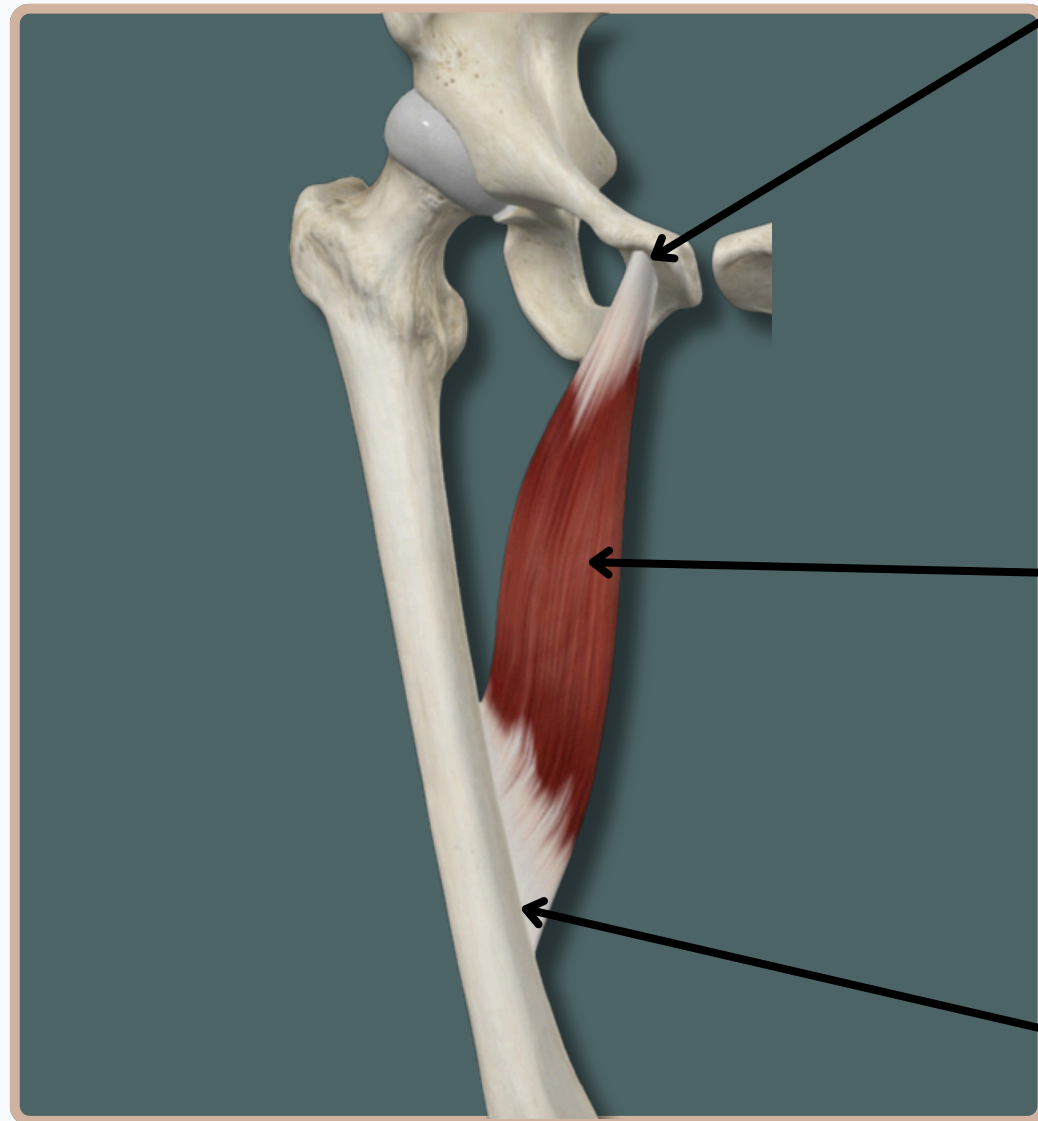
Medial View



MEDIAL ADDUCTOR MUSCLES OF THE THIGH

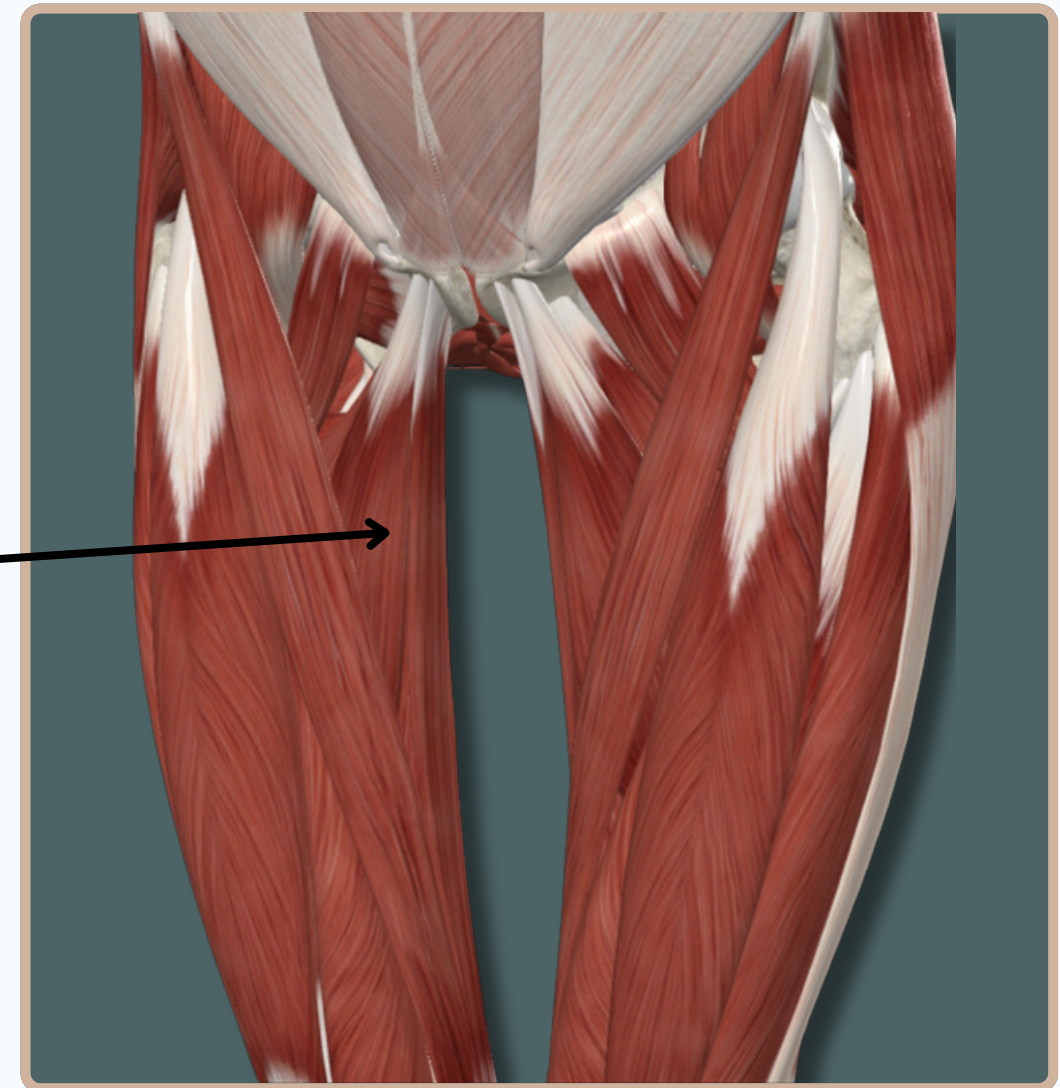
ADDUCTOR LONGUS

Origin : Body of **pubis** and inferior **pubic** ramus



Adductor Longus

Insertion : Medial aspect of proximal part of **tibia**



Action :
-**Adducts** thigh at **Hip** joint

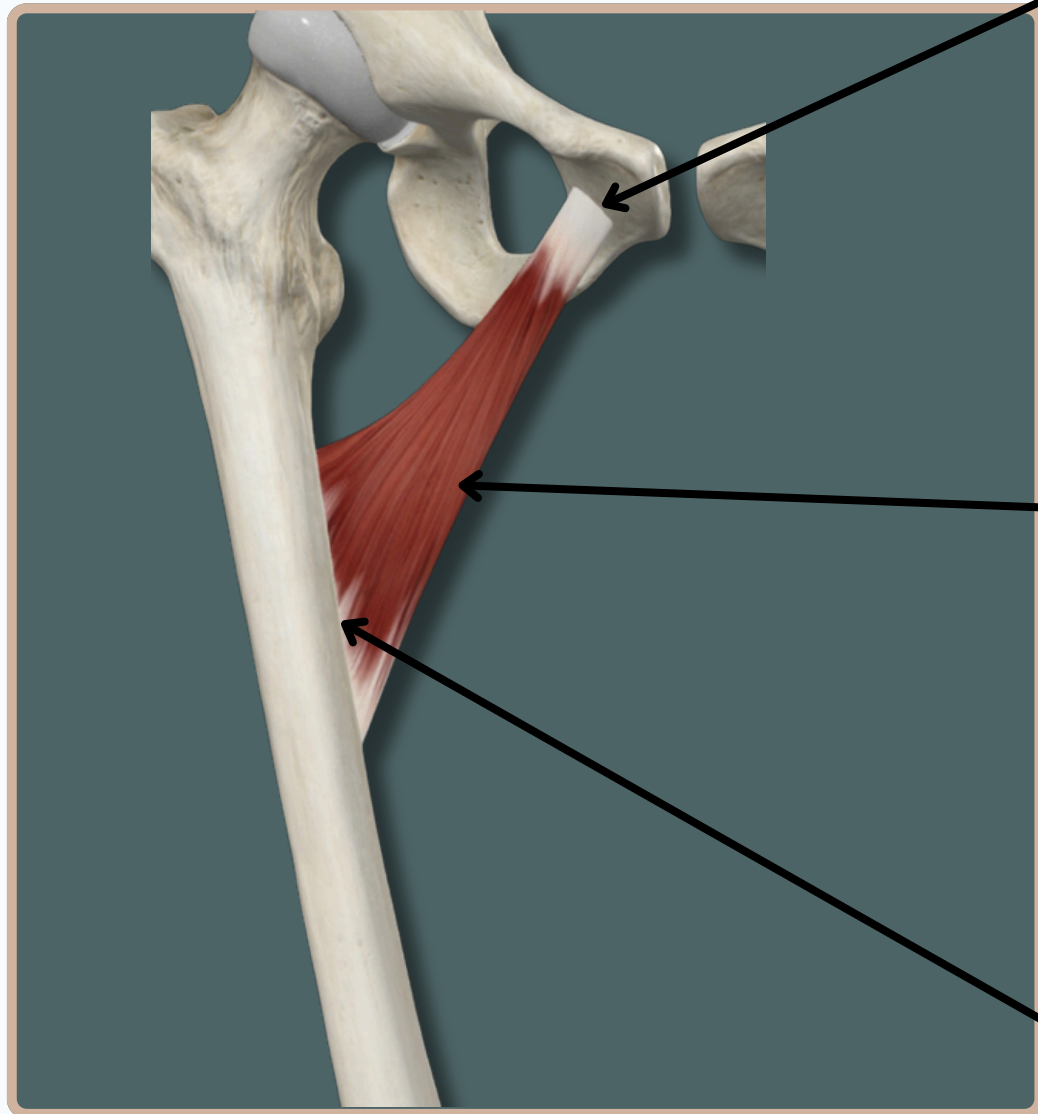
Nerve Supply :
Obturator Nerve

Medial View

MEDIAL ADDUCTOR MUSCLES OF THE THIGH

ADDUCTOR BREVIS

Origin : Anterior surface of body of **pubis**



Adductor Brevis

Insertion : Middle one third of linea aspera of **femur**



Action :
-**Adducts** thigh at **Hip** joint

Nerve Supply :
Obturator Nerve

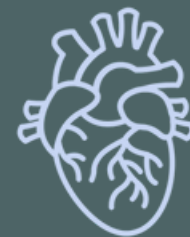Medial View

THANK YOU

EDITED BY



SATURN
MEDIC



ARECH

© ALL COPYRIGHT ARE RESERVED FOR
SATURN MEDIC AND ARECH

WWW.SATURNMEDIC.COM