

ANATOMY OF LOWER LIMB

PRACTICAL LECTURE - 7 -

MUSCLES / PART 3

POSTERIOR FLEXOR MUSCLES OF THE THIGH

EDITED BY



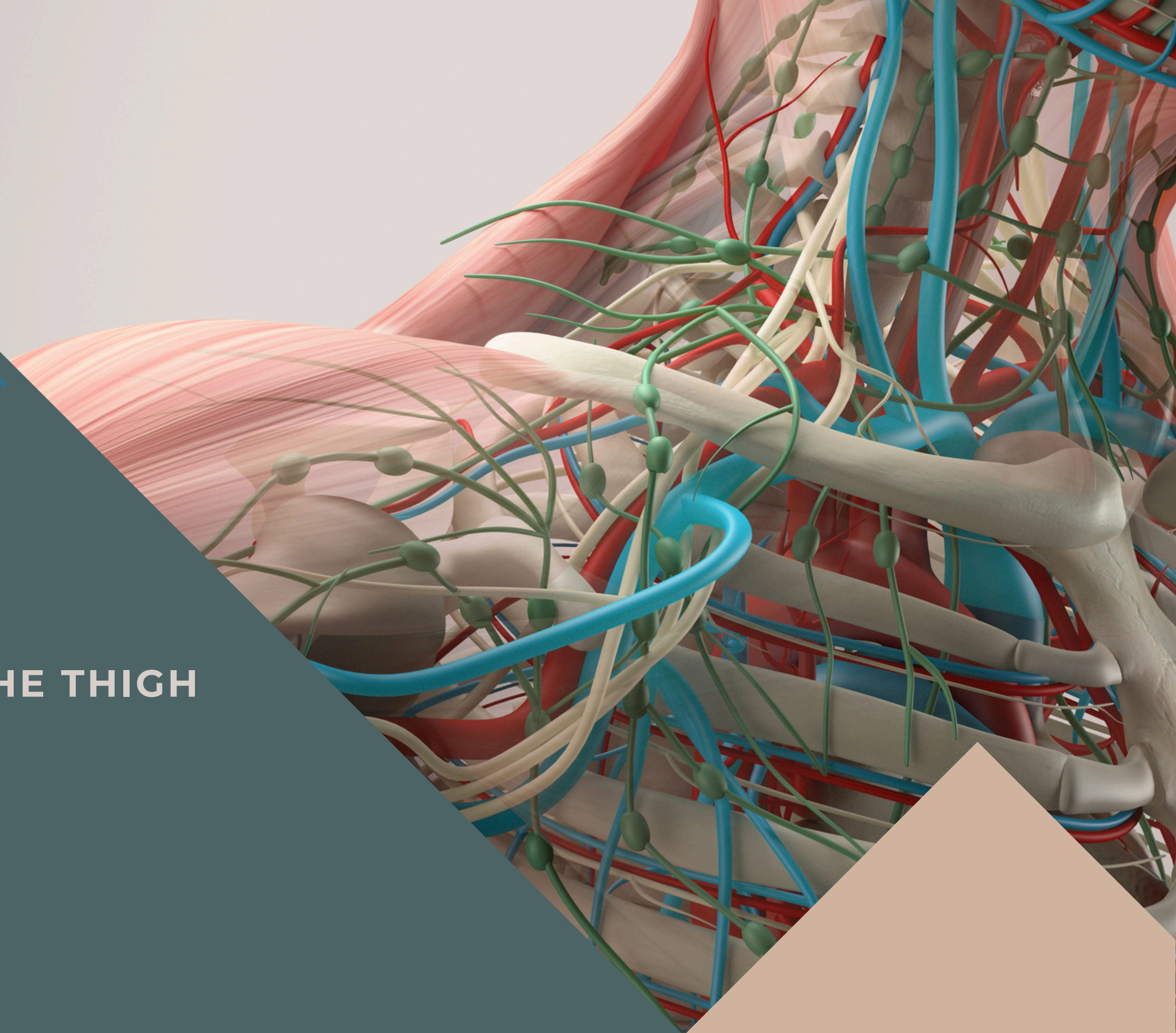
SATURN
MEDIC

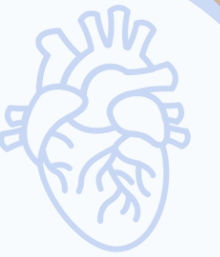

ARECH

© ALL COPYRIGHT ARE RESERVED FOR
SATURN MEDIC AND ARECH

WWW.SATURNMEDIC.COM



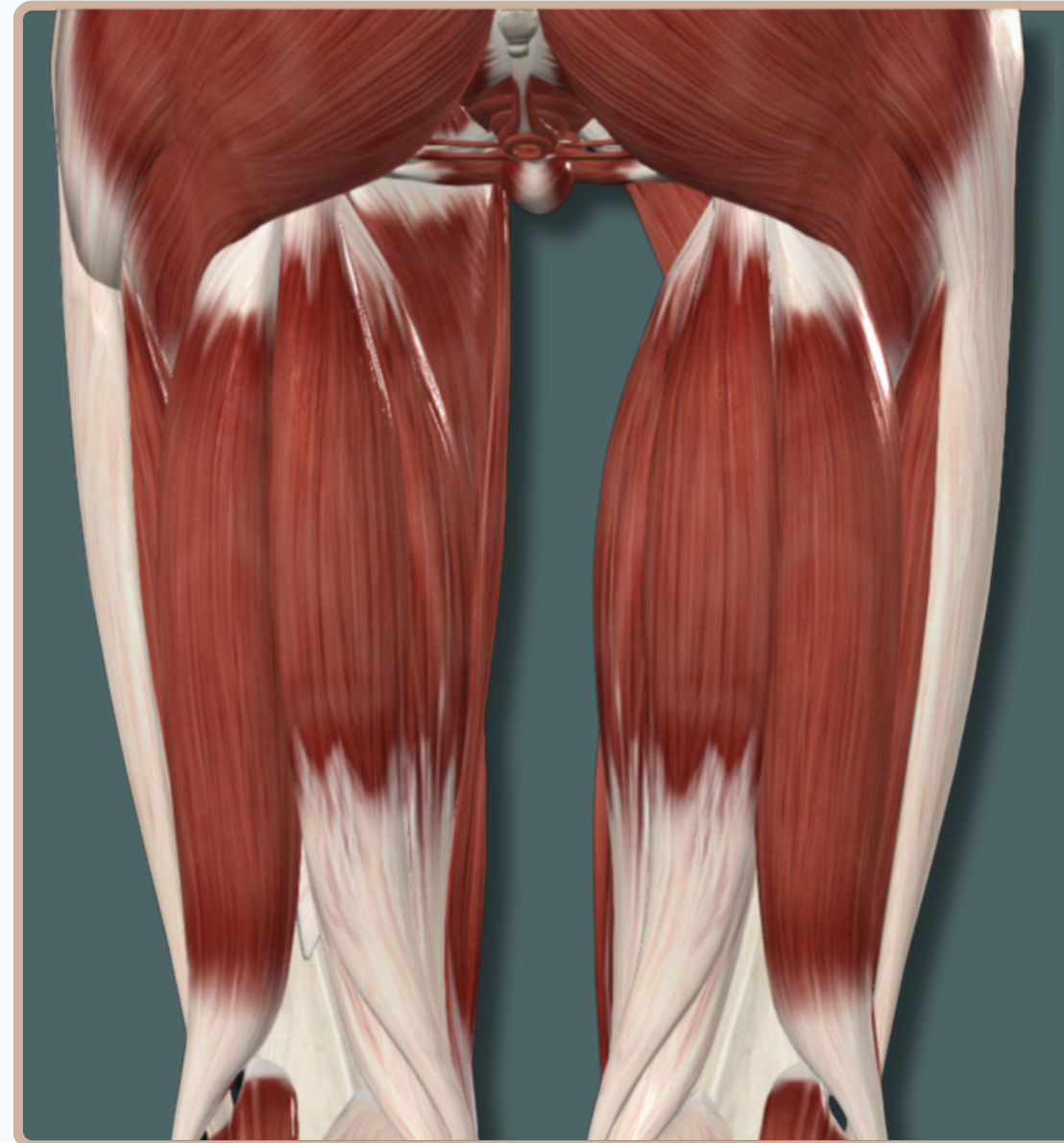

-All The Muscles of The **Posterior Compartment of The Thigh** Are Responsible For :

- **Knee Flexion**
- **Hip Extension**

-All The Muscles of The **Posterior Compartment of The Thigh** Are Supplied By

- Tibial** division of **Sciatic Nerve**
- Common fibular** division of Sciatic nerve



Posterior View

POSTERIOR FLEXOR MUSCLES OF THE THIGH



BICEPS FEMORIS

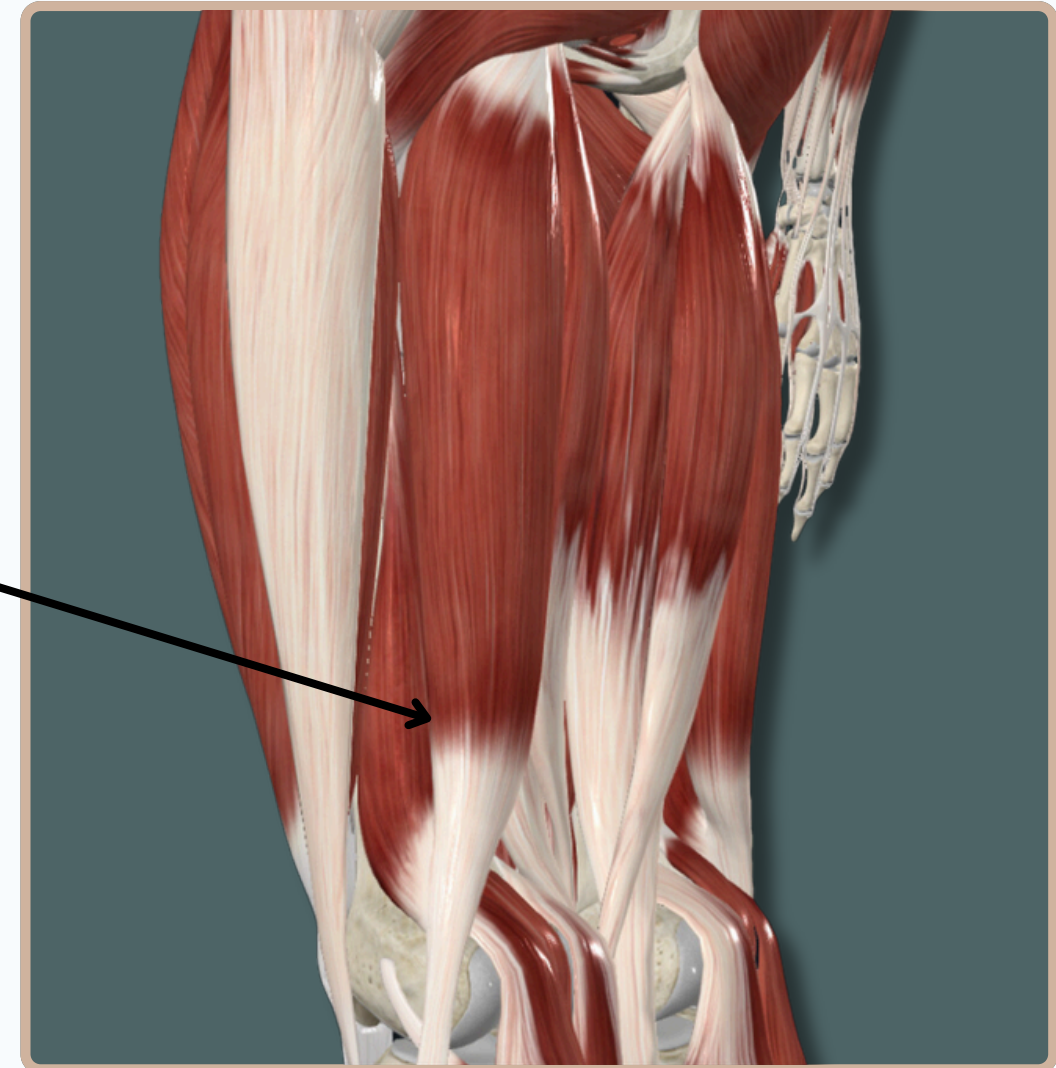
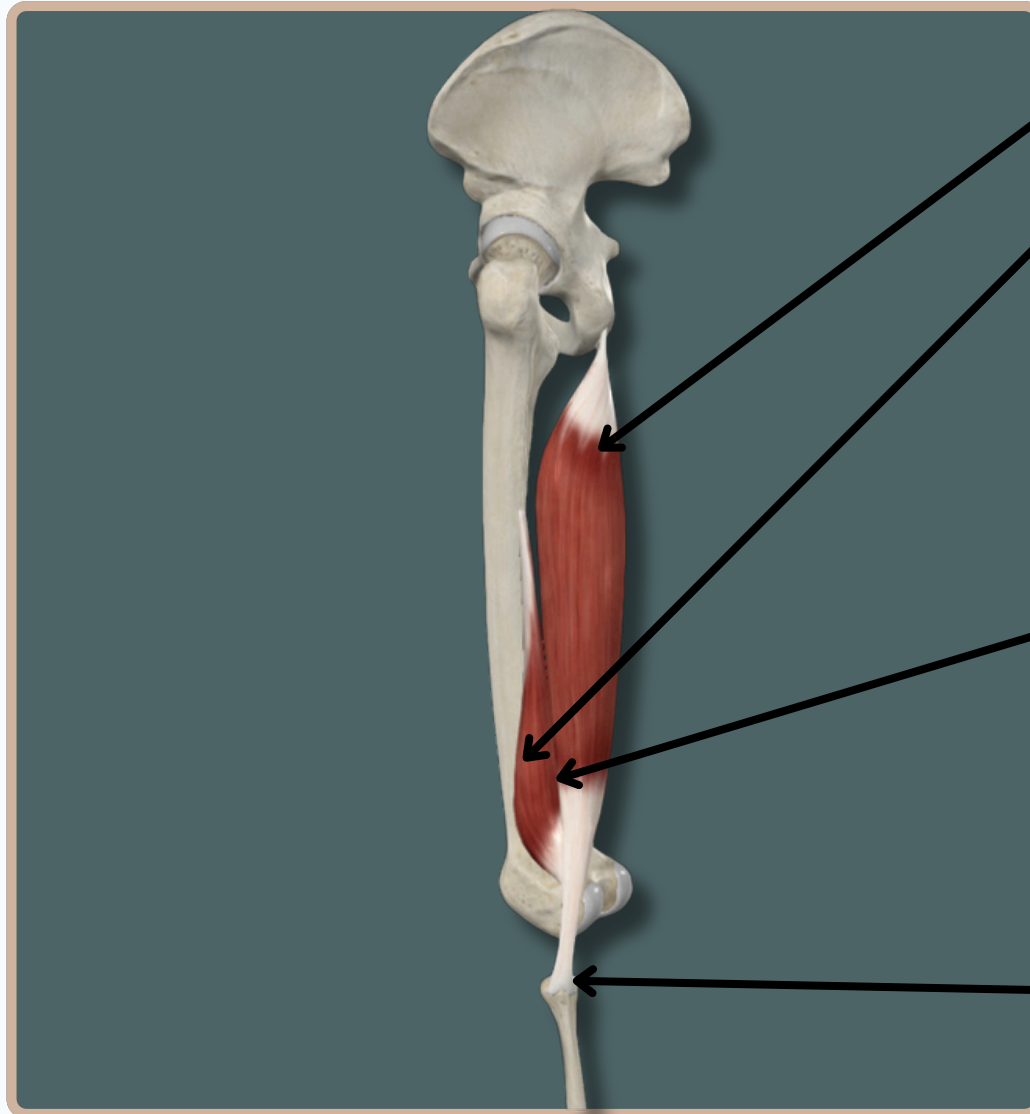
Origin :

Long Head : Ischial tuberosity

Short Head : Linea aspera and lateral supracondylar line of **Femur**

Biceps Femoris

Insertion : Head of **fibula**



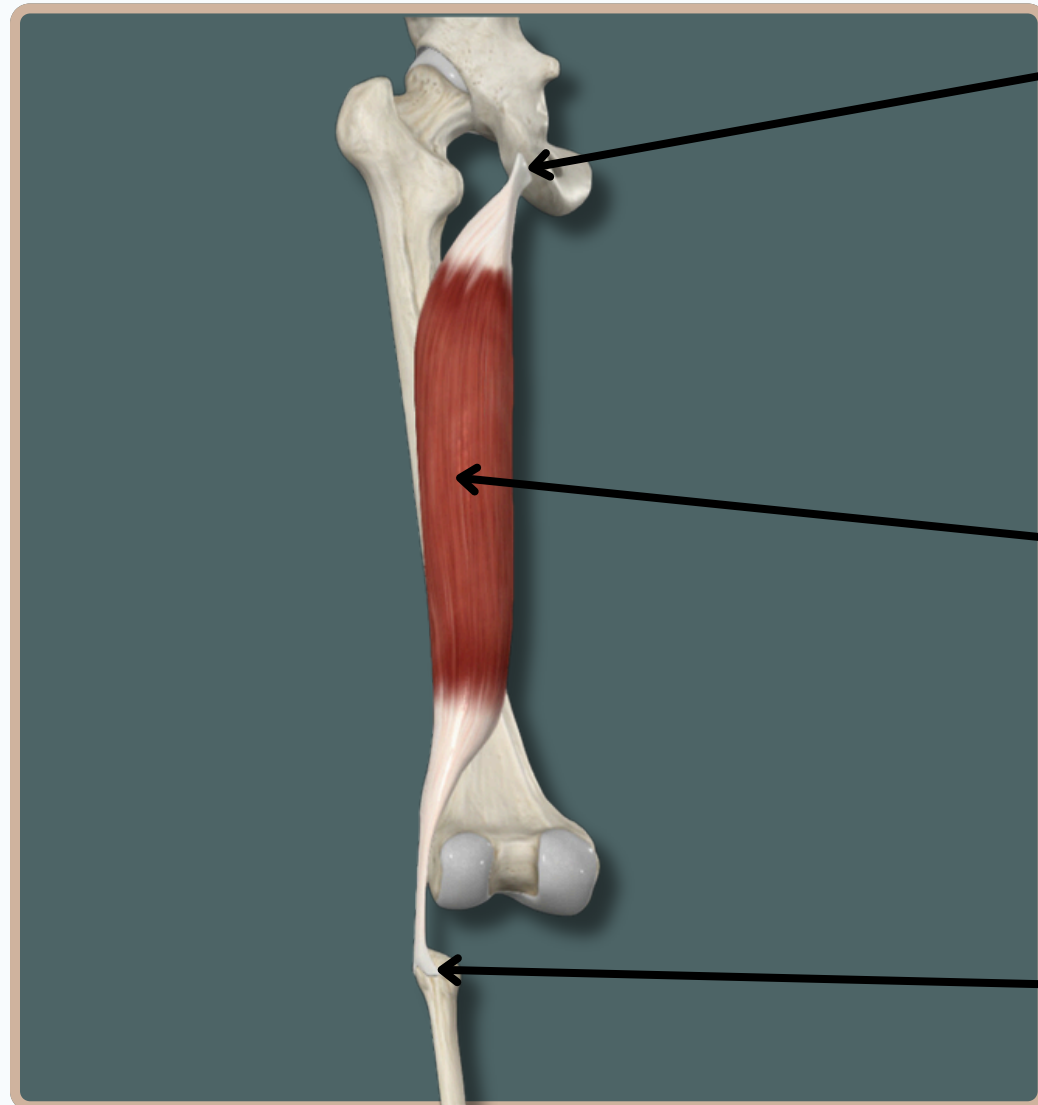
Posterior View

POSTERIOR FLEXOR MUSCLES OF THE THIGH

BICEPS FEMORIS

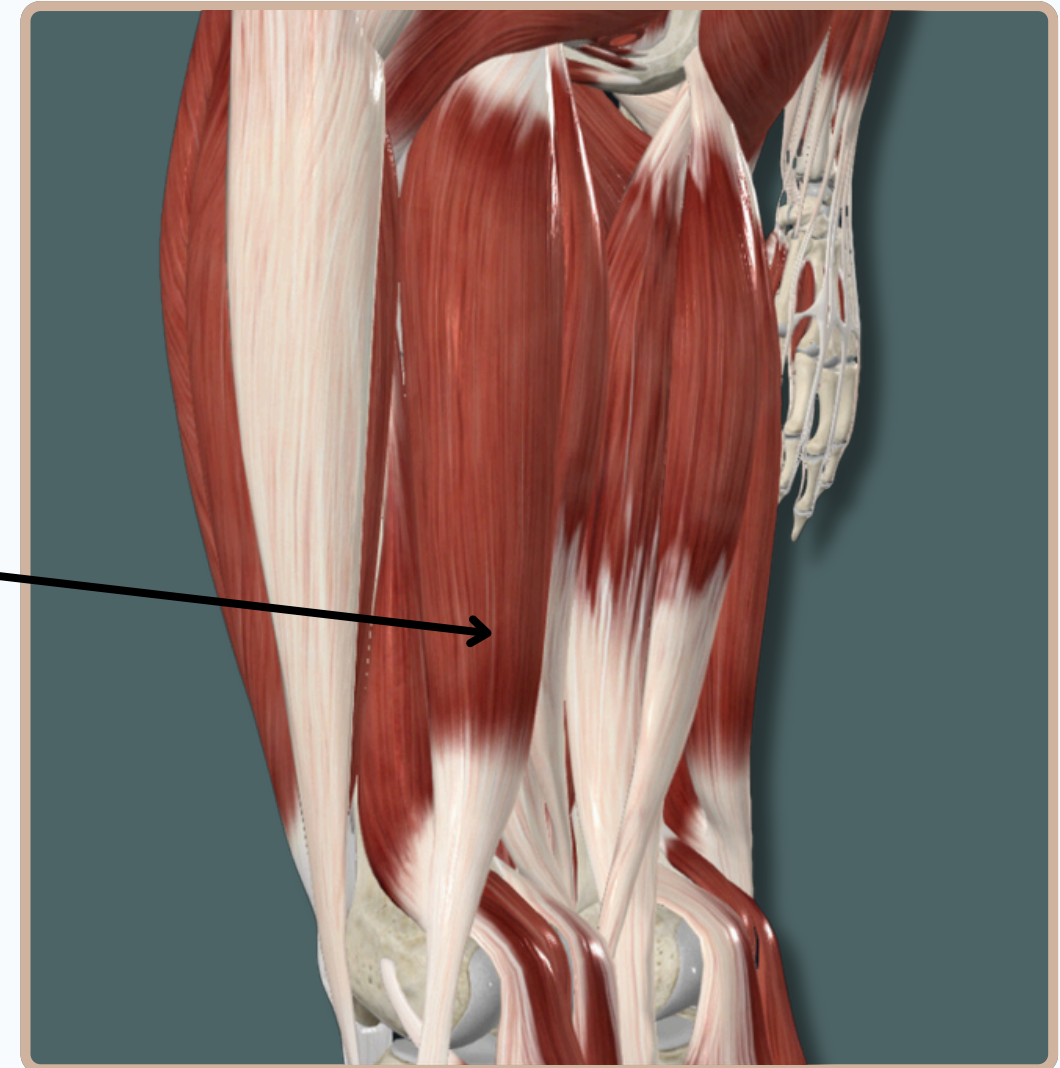
Origin :

Long Head : Ischial tuberosity



Long Head of
Biceps Femoris

Insertion : Head of **fibula**



Action :

Long Head : -Flexes and **laterally** rotates leg at **knee** joint

-**Extends** thigh at **Hip** joint

Nerve Supply :

Long Head : **Tibial** division of **Sciatic Nerve**

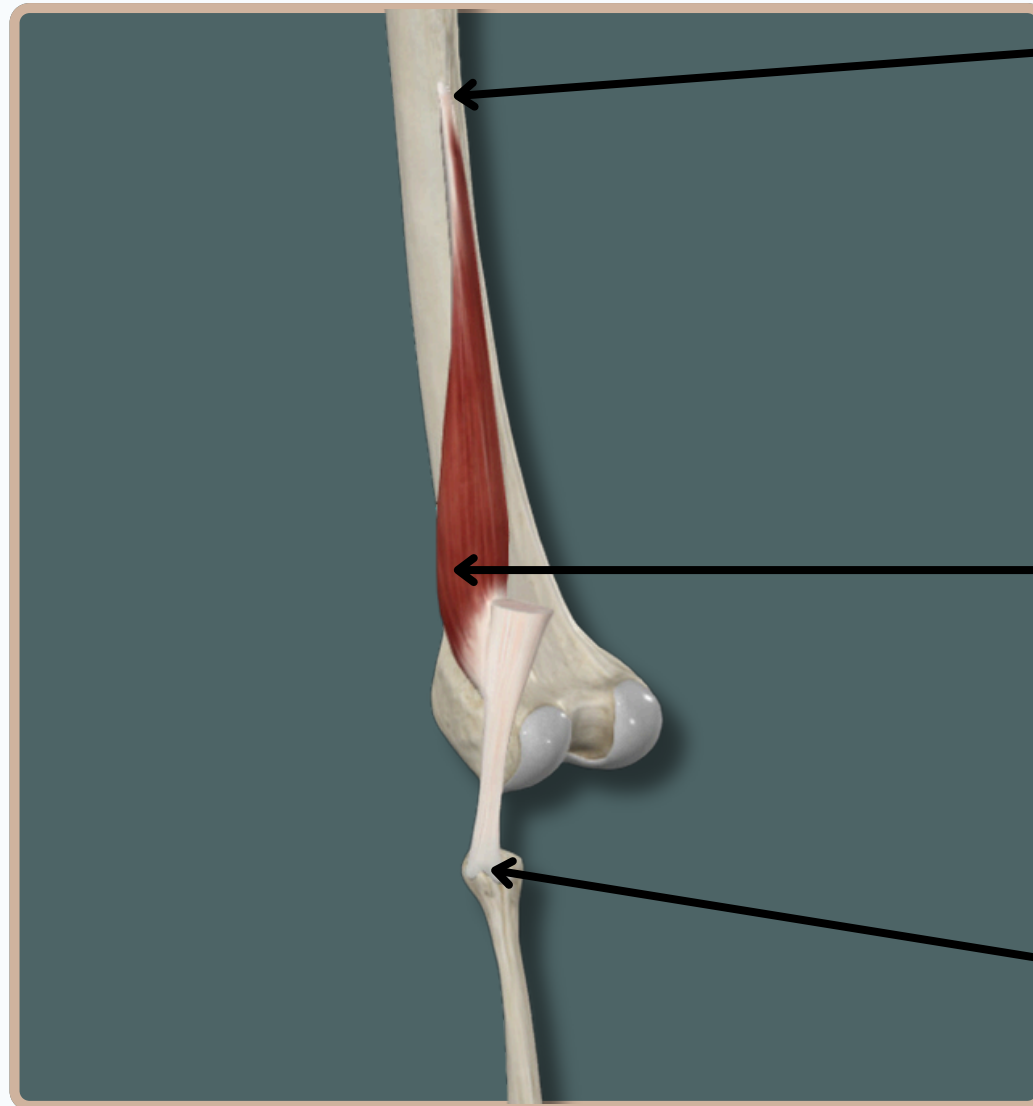
Posterior View

POSTERIOR FLEXOR MUSCLES OF THE THIGH

BICEPS FEMORIS

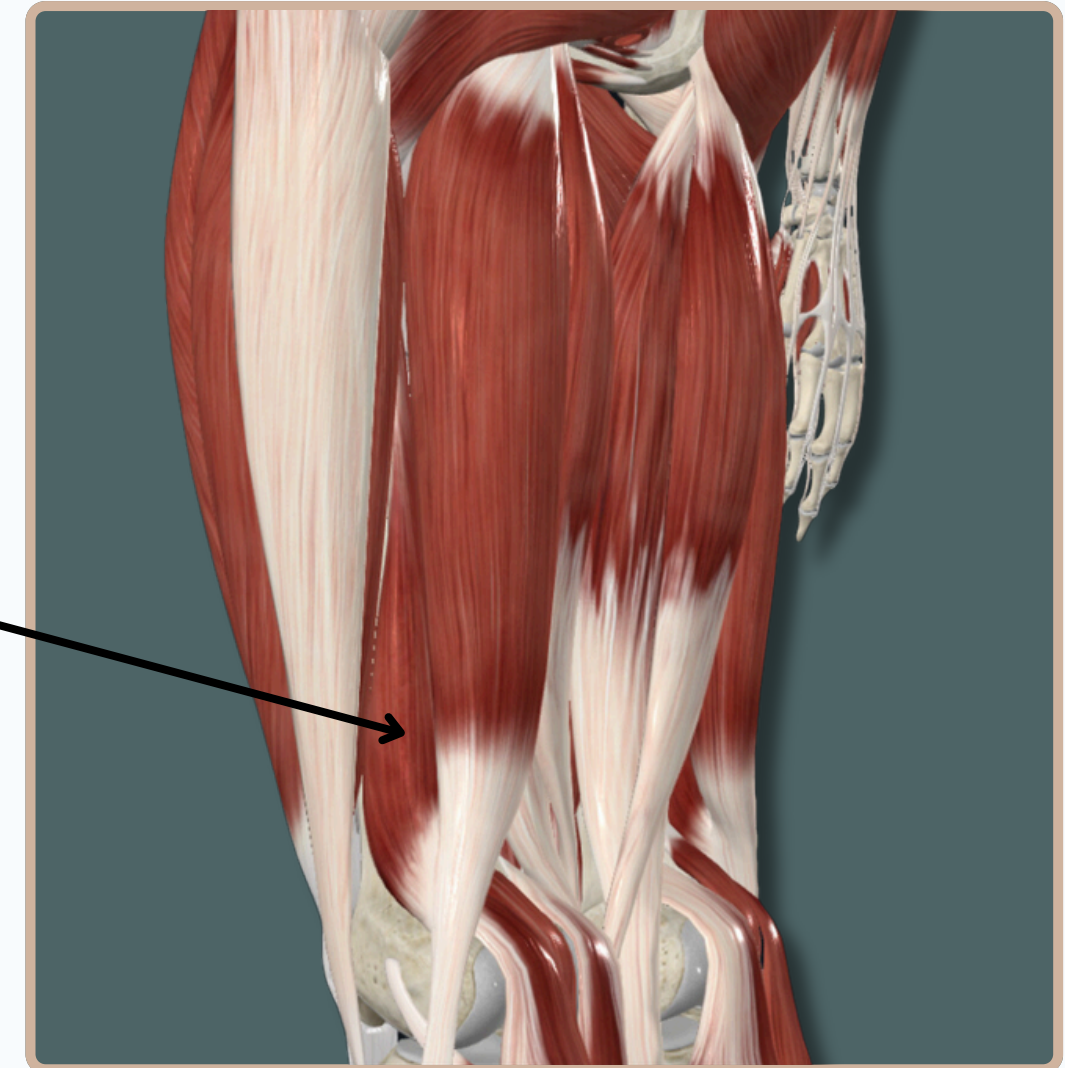
Origin :

Short Head : Linea aspera and lateral supracondylar line of **Femur**



Short Head of Biceps Femoris

Insertion : Head of **fibula**



Nerve Supply :

Short Head : Common fibular division of **Sciatic Nerve**

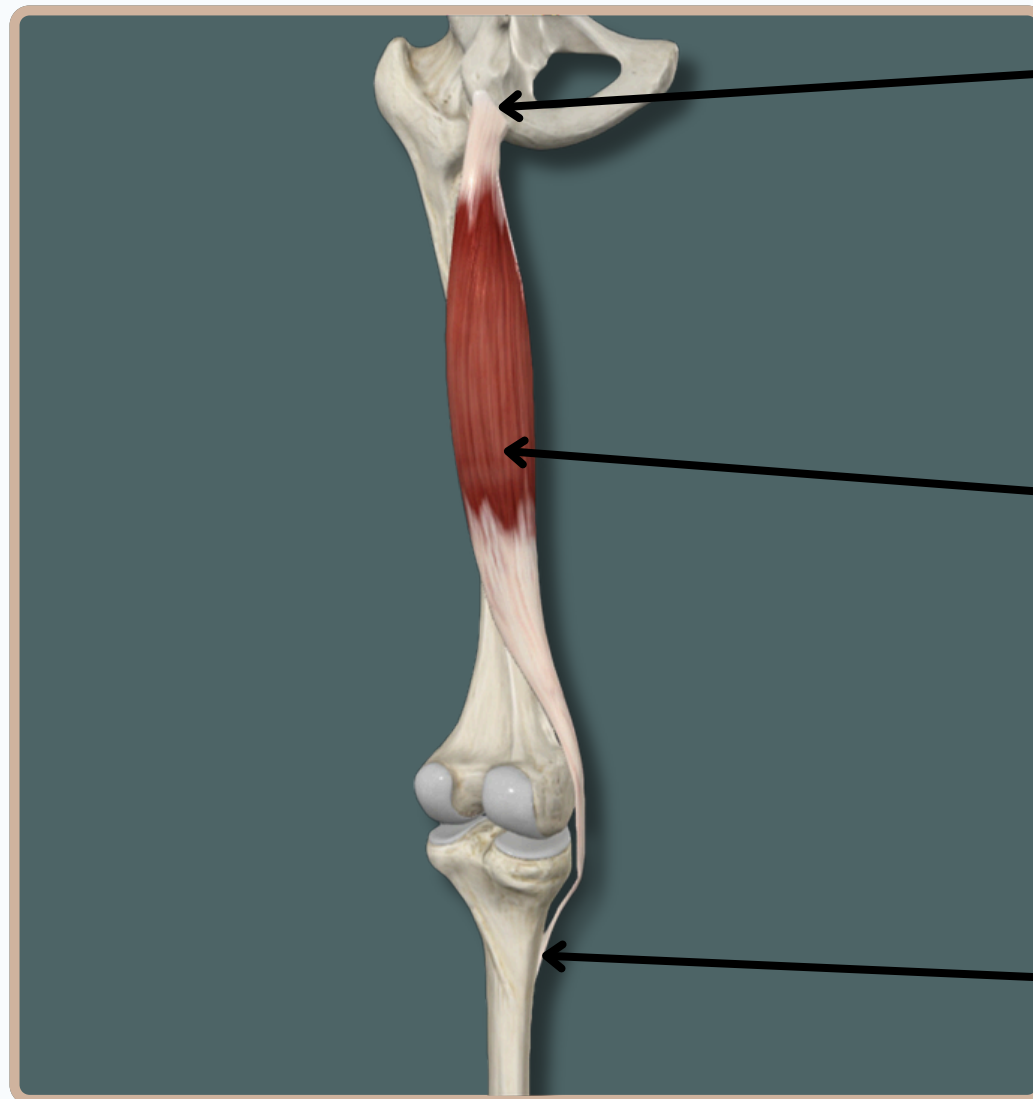
Action :

Short Head : -**Flexes** and **laterally** rotates leg at **knee** joint

Posterior View

POSTERIOR FLEXOR MUSCLES OF THE THIGH

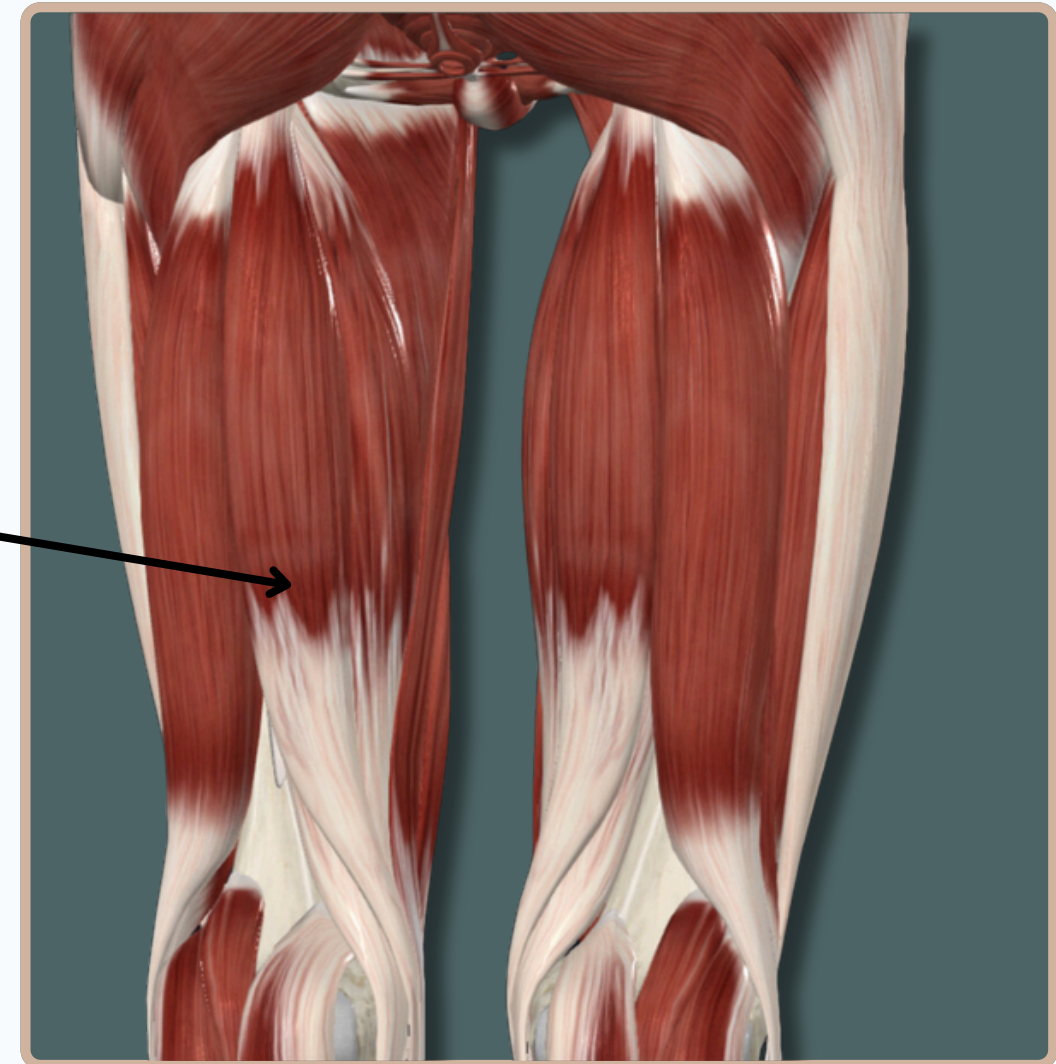
SEMITENDINOSUS



Origin : Ischial tuberosity

Semitendinosus

Insertion : Medial aspect of proximal part of **tibia**



Action :

- Flexes and Medially** Rotates leg at **knee** joint
- Extends** thigh at **Hip** joint

Nerve Supply :

Tibial division of **Sciatic Nerve**

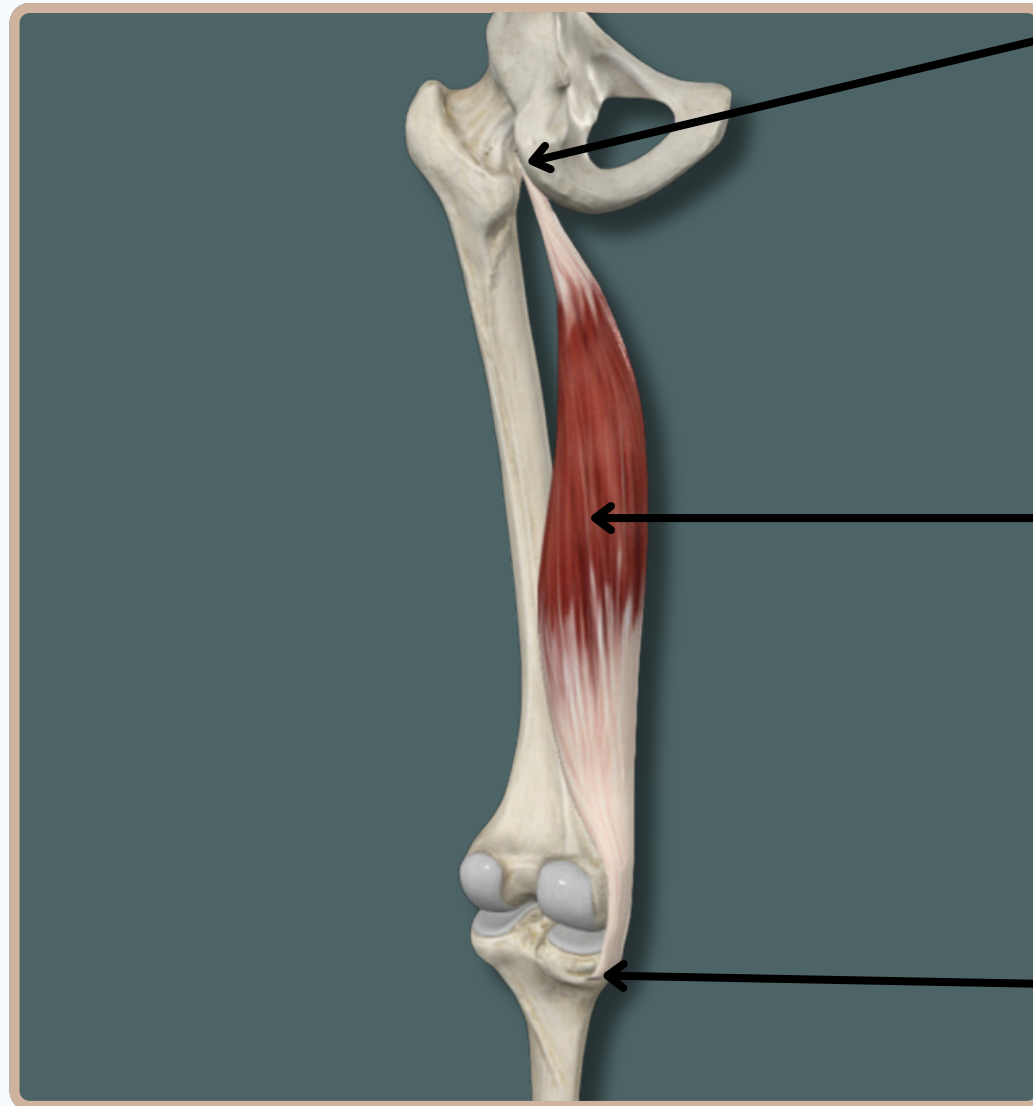
Posterior View

POSTERIOR FLEXOR MUSCLES OF THE THIGH

SEMIMEMBRANOSUS

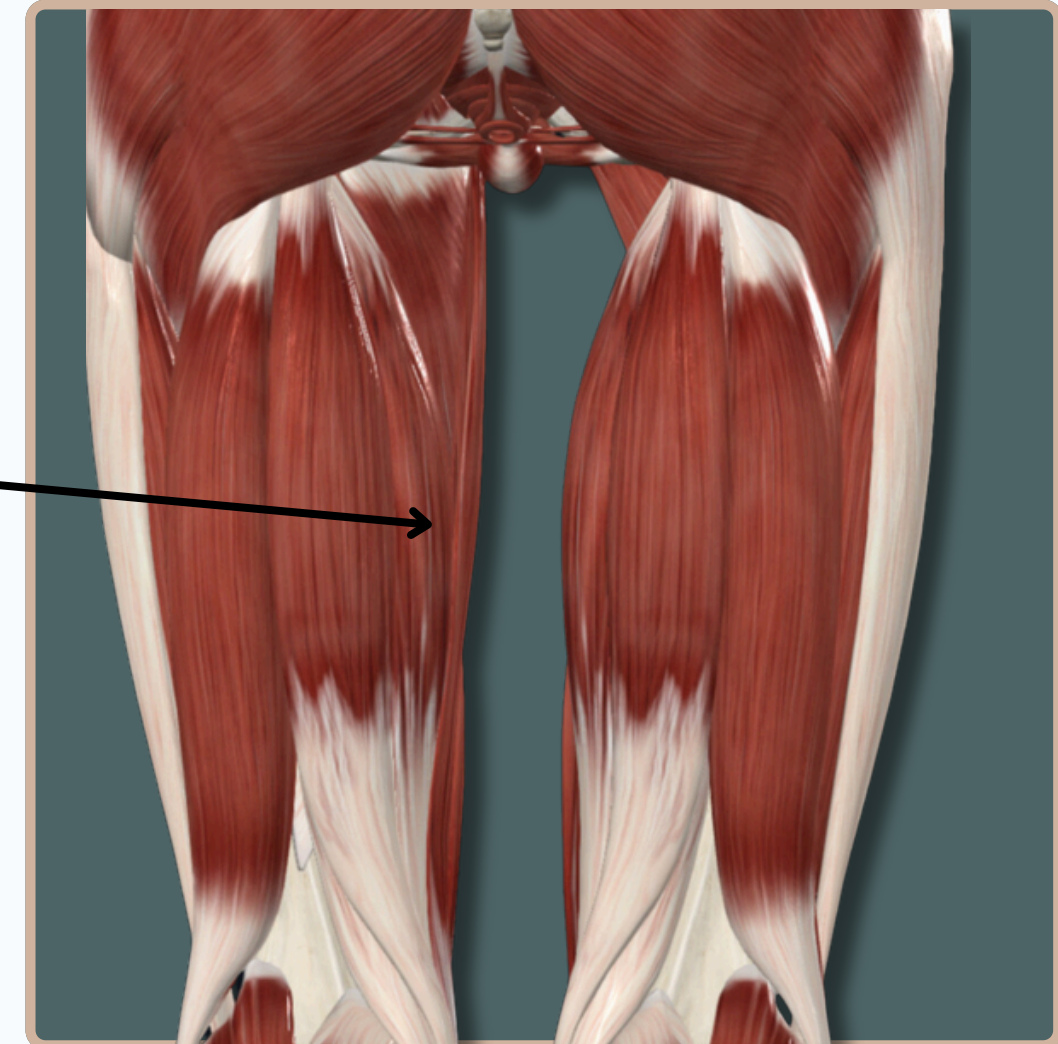


Origin : Ischial tuberosity



Semimembranosus

Insertion : Medial condyle of tibia



Action :

- Flexes and Medially** Rotates leg at **knee** joint
- Extends** thigh at **Hip** joint

Nerve Supply :

Tibial division of **Sciatic Nerve**

Posterior View

THANK YOU

EDITED BY



SATURN
MEDIC



ARECH

© ALL COPYRIGHT ARE RESERVED FOR
SATURN MEDIC AND ARECH

WWW.SATURNMEDIC.COM