

ANATOMY OF ABDOMEN

PRACTICAL LECTURE - 1 -

INTRODUCTION + MUSCLES OF THE ABDOMINAL REGION

EDITED BY



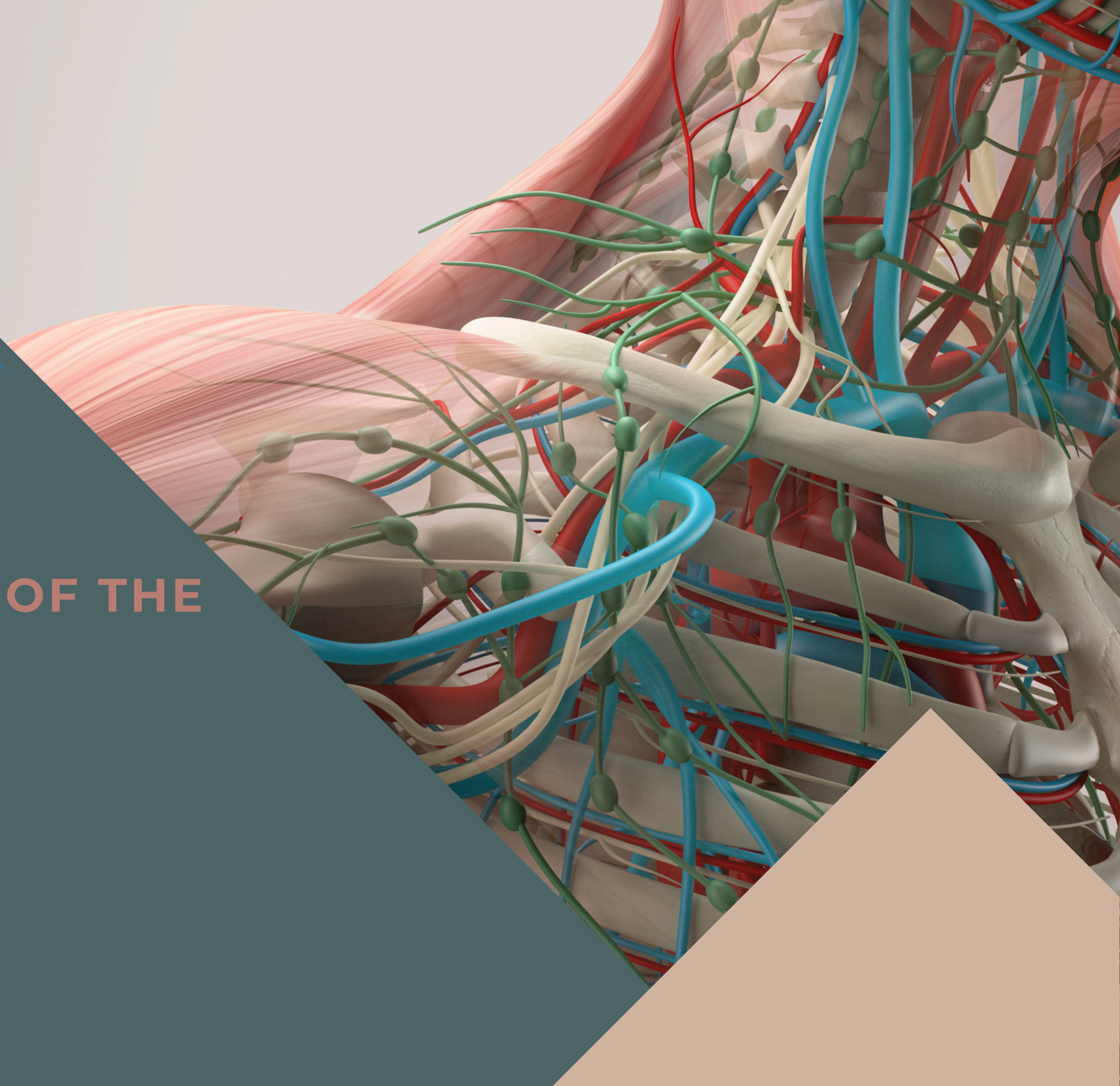
SATURN
MEDIC



ARECH

© ALL COPYRIGHT ARE RESERVED FOR
SATURN MEDIC AND ARECH

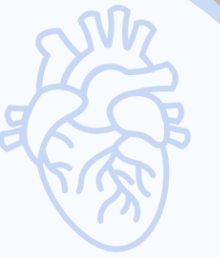WWW.SATURNMEDIC.COM



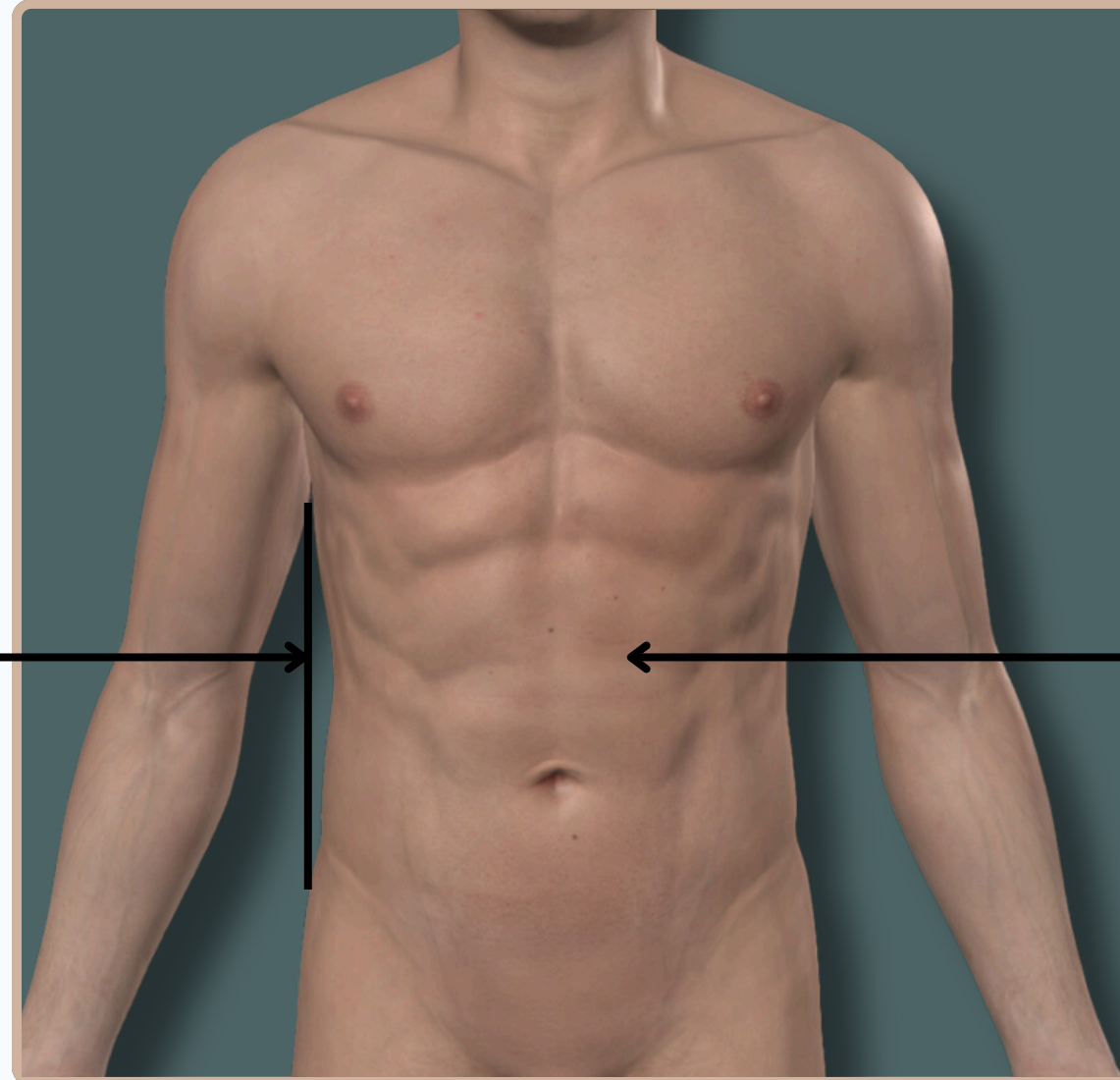


ABDOMEN

INTRODUCTION



Abdominal Region



Skin (First Layer)

The **Outermost** layer that covers the body

Anterior View



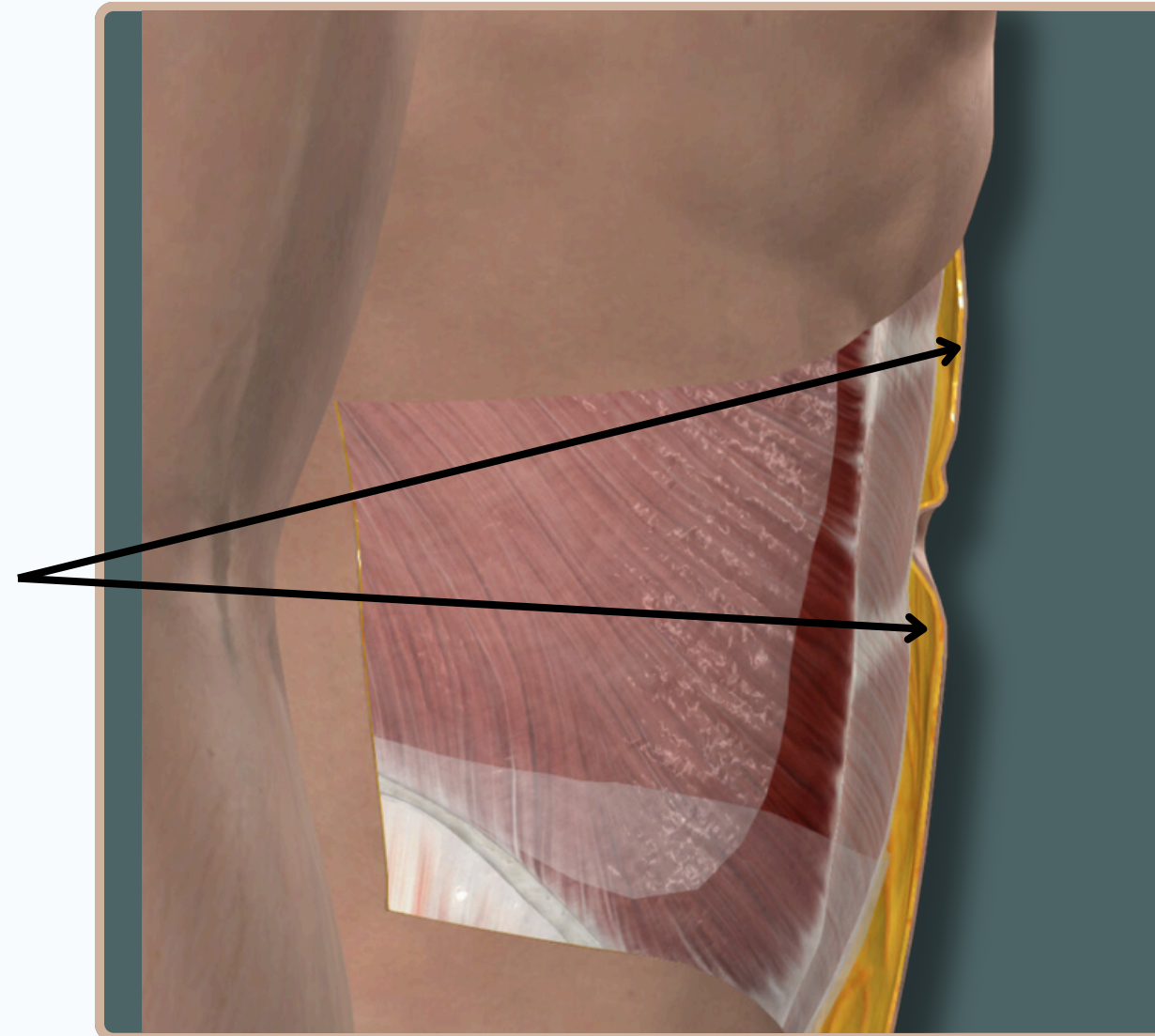
ABDOMEN



INTRODUCTION

Superficial Fascia (Second Layer)

- **Camper's Fascia:** The outer fatty layer of the superficial fascia.
- **Scarpa's Fascia:** The deeper, membranous layer of the superficial fascia.

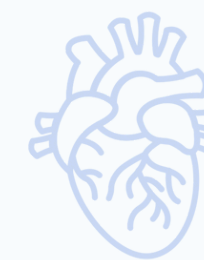

Lateral View

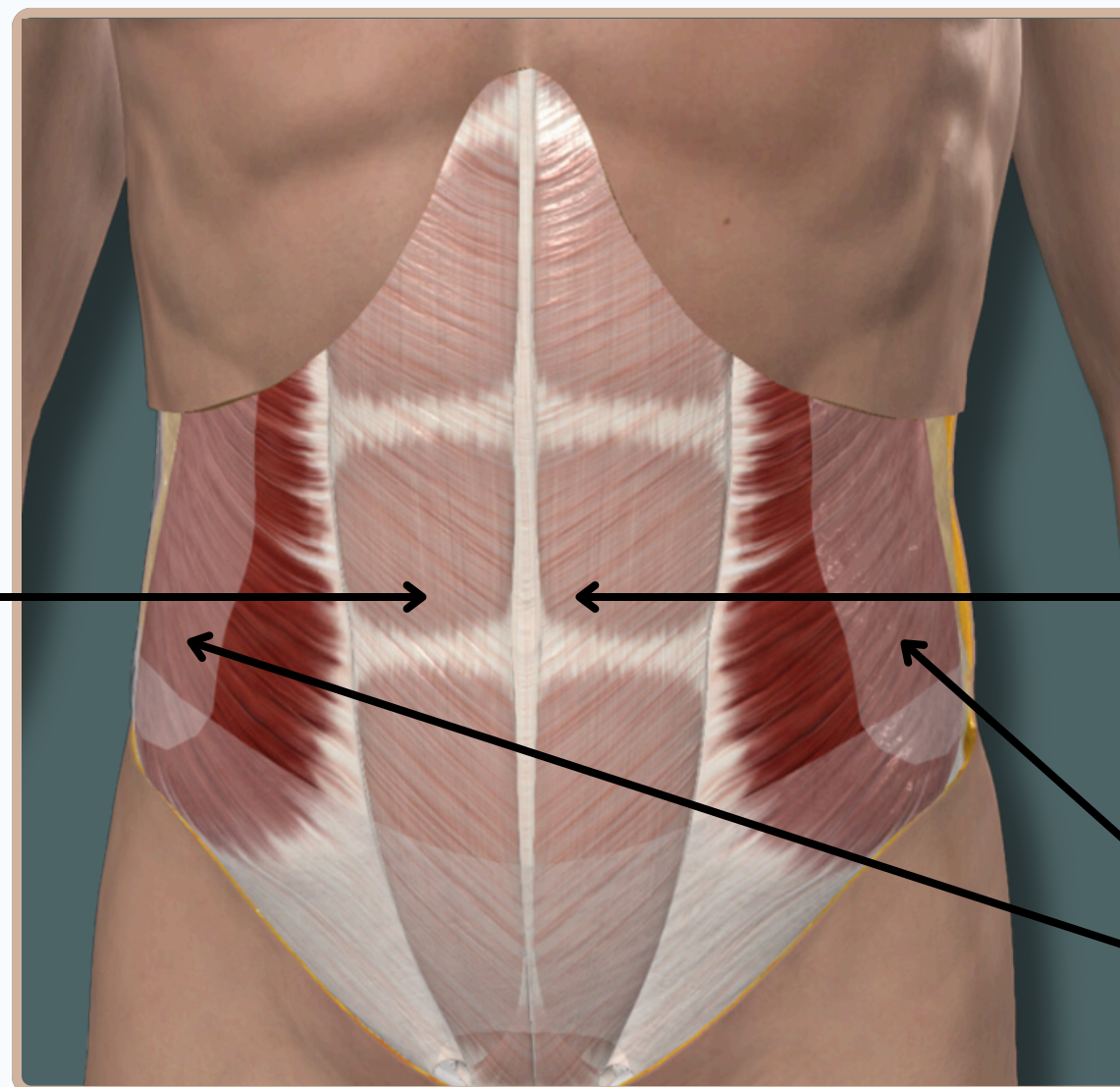


ABDOMEN

INTRODUCTION



Deep Abdominal Fascia



**Muscles and Their Fascia
(Third Layer)**

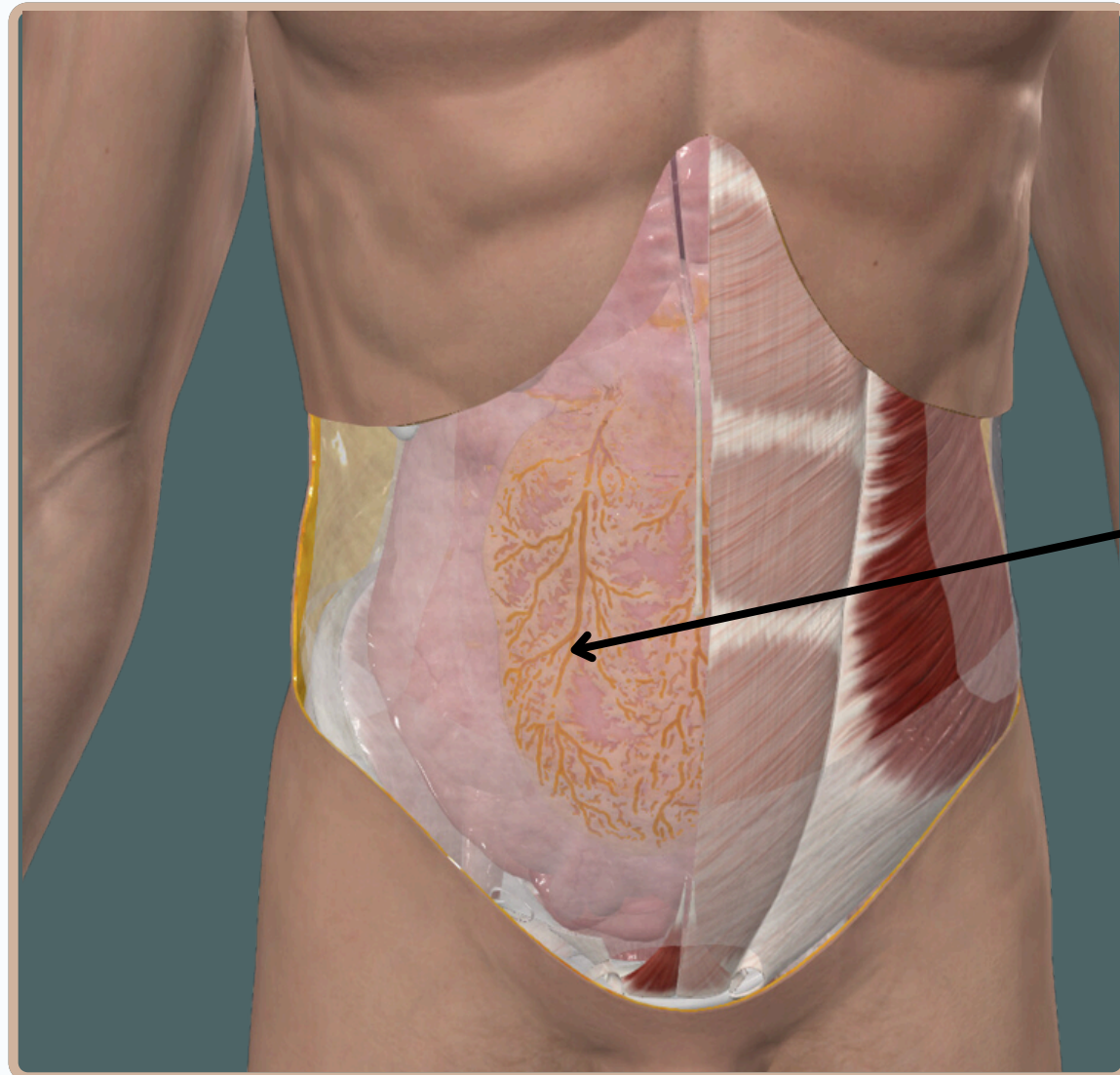
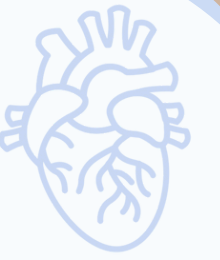Rectus Sheath

Anterior View



ABDOMEN

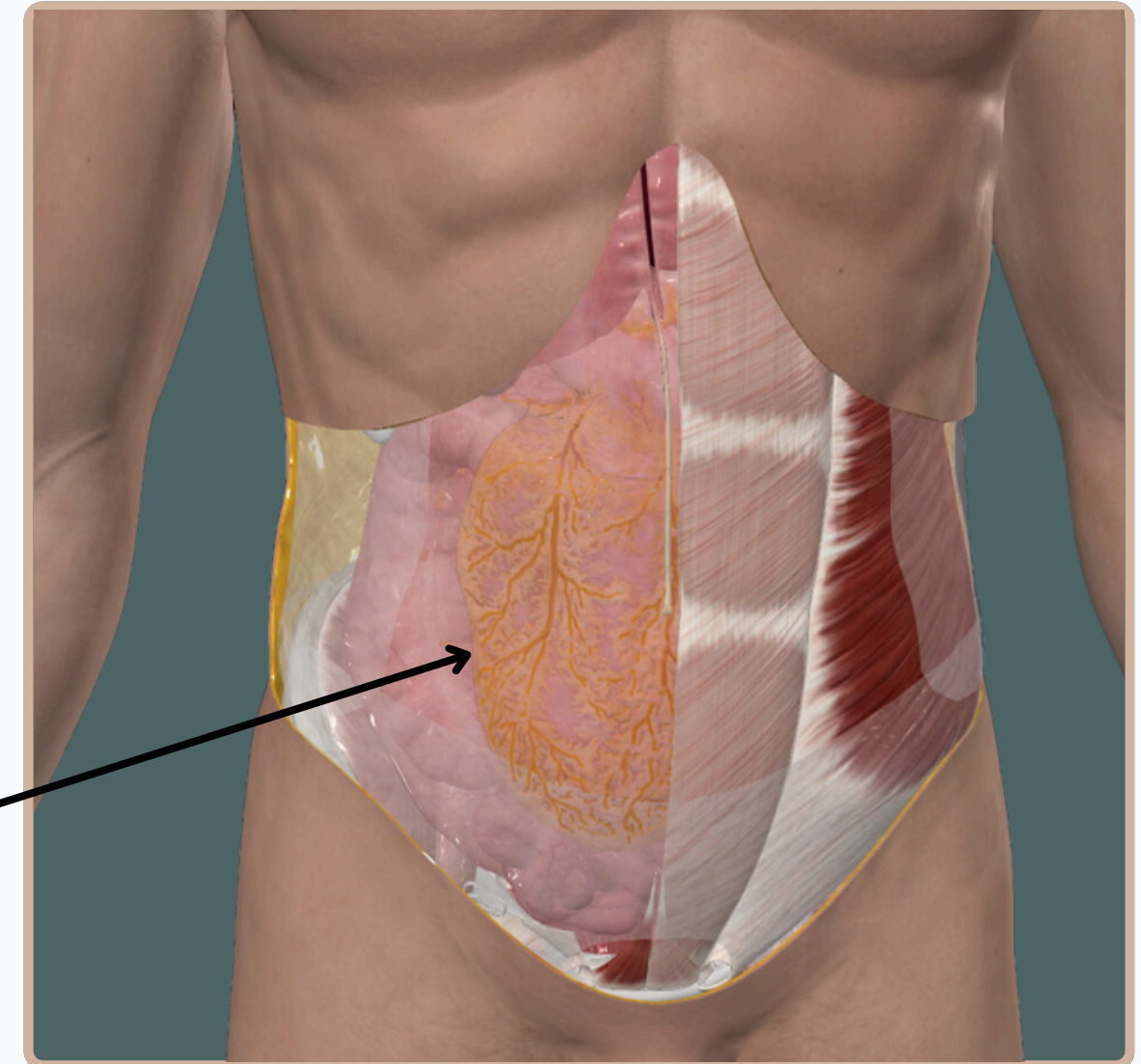
INTRODUCTION



Transversalis Fascia



**Parietal Peritoneum
(Last Layer)**



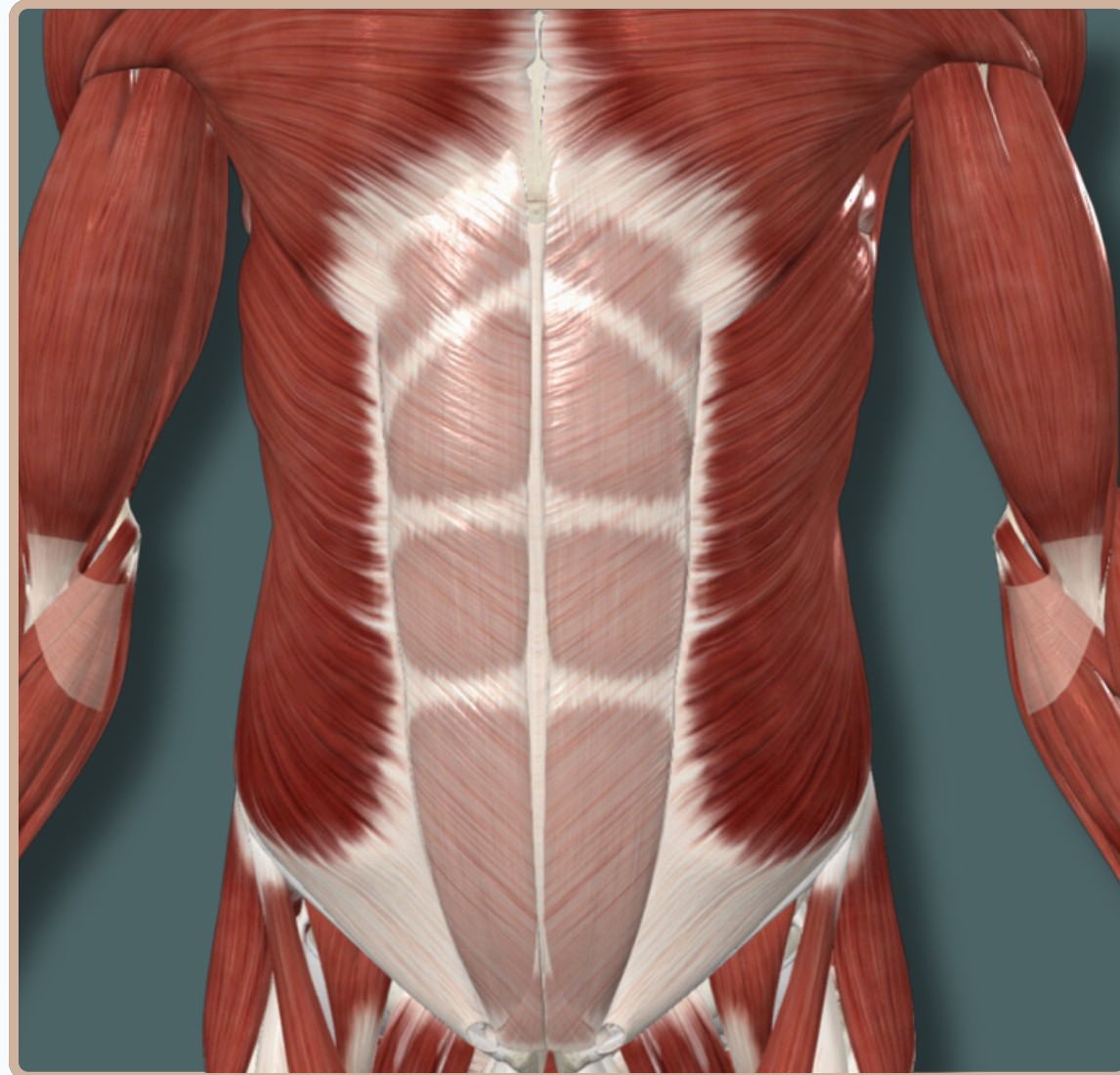
Anterior View



ABDOMEN



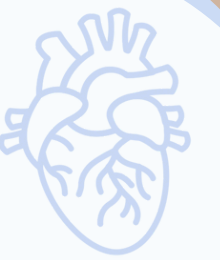MUSCLES OF THE ANTERIOR ABDOMINAL WALL



Anterior View

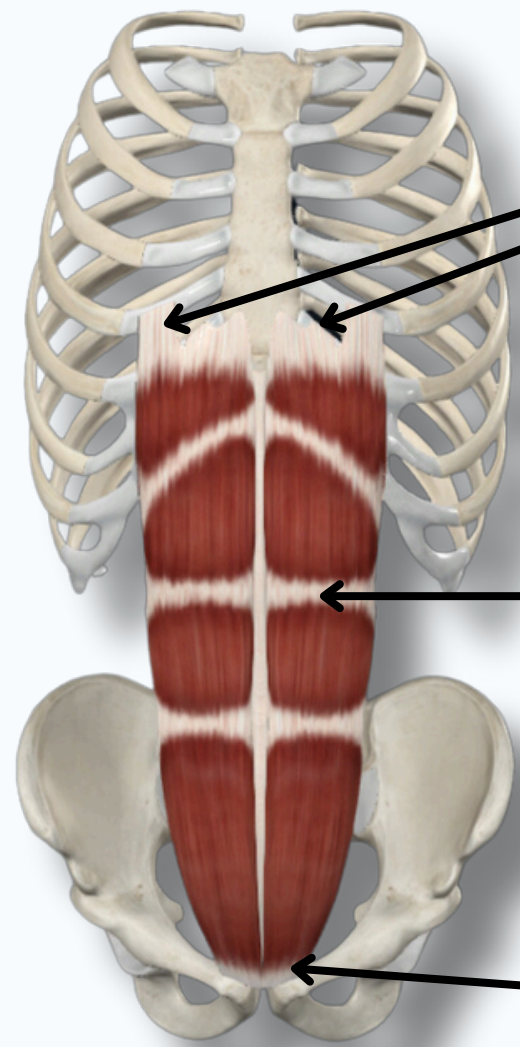


ABDOMEN



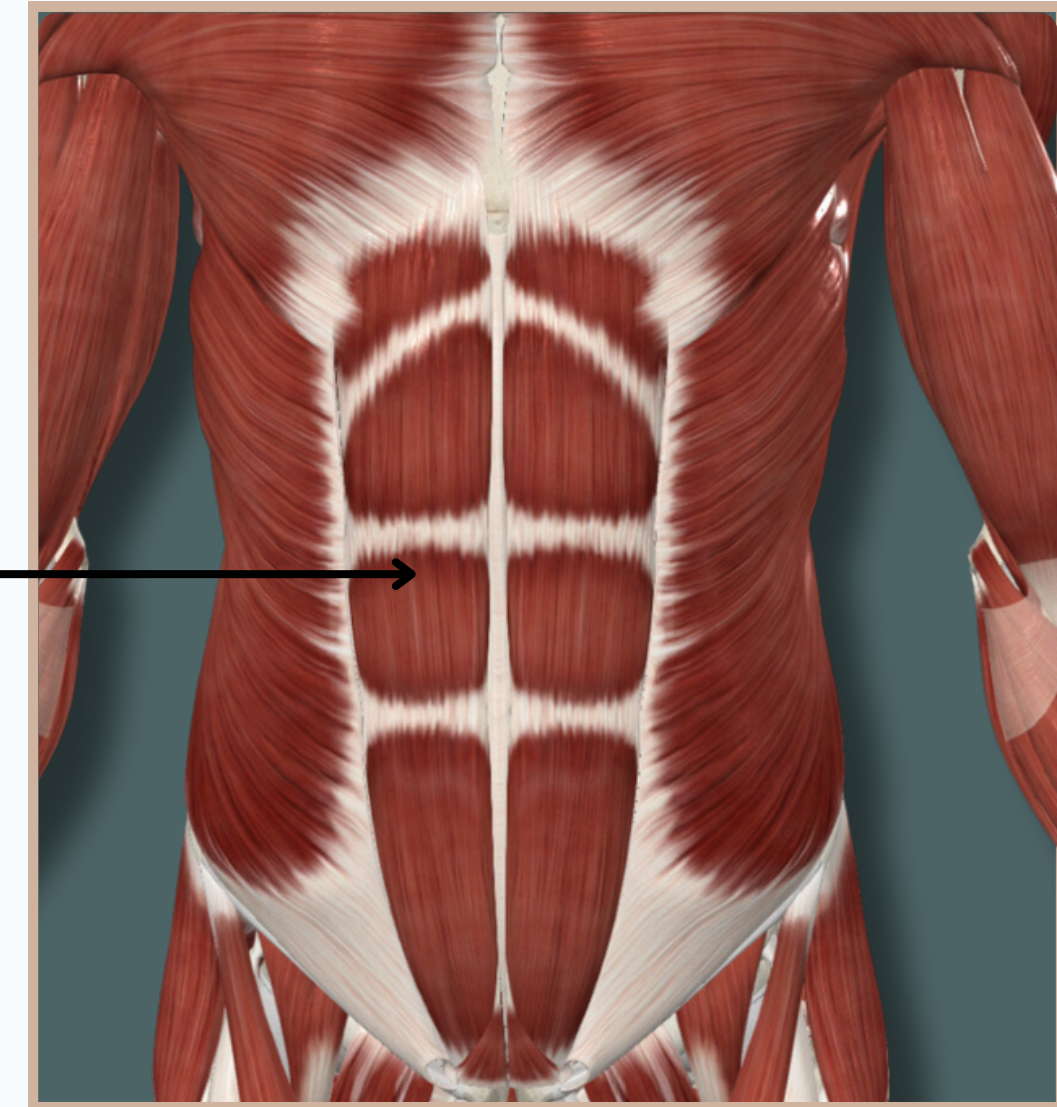
RECTUS ABDOMINIS

Insertion : Xiphoid process and costal cartilages of **fifth to seventh ribs**



Rectus Abdominis

Origin : Pubic crest and **symphysis**



Action :

- **Flexes** trunk
- **compresses** and provides **structural support** to adjacent abdominal structures

Nerve Supply :

Anterior rami of sixth to twelfth thoracic nerves

Anterior View

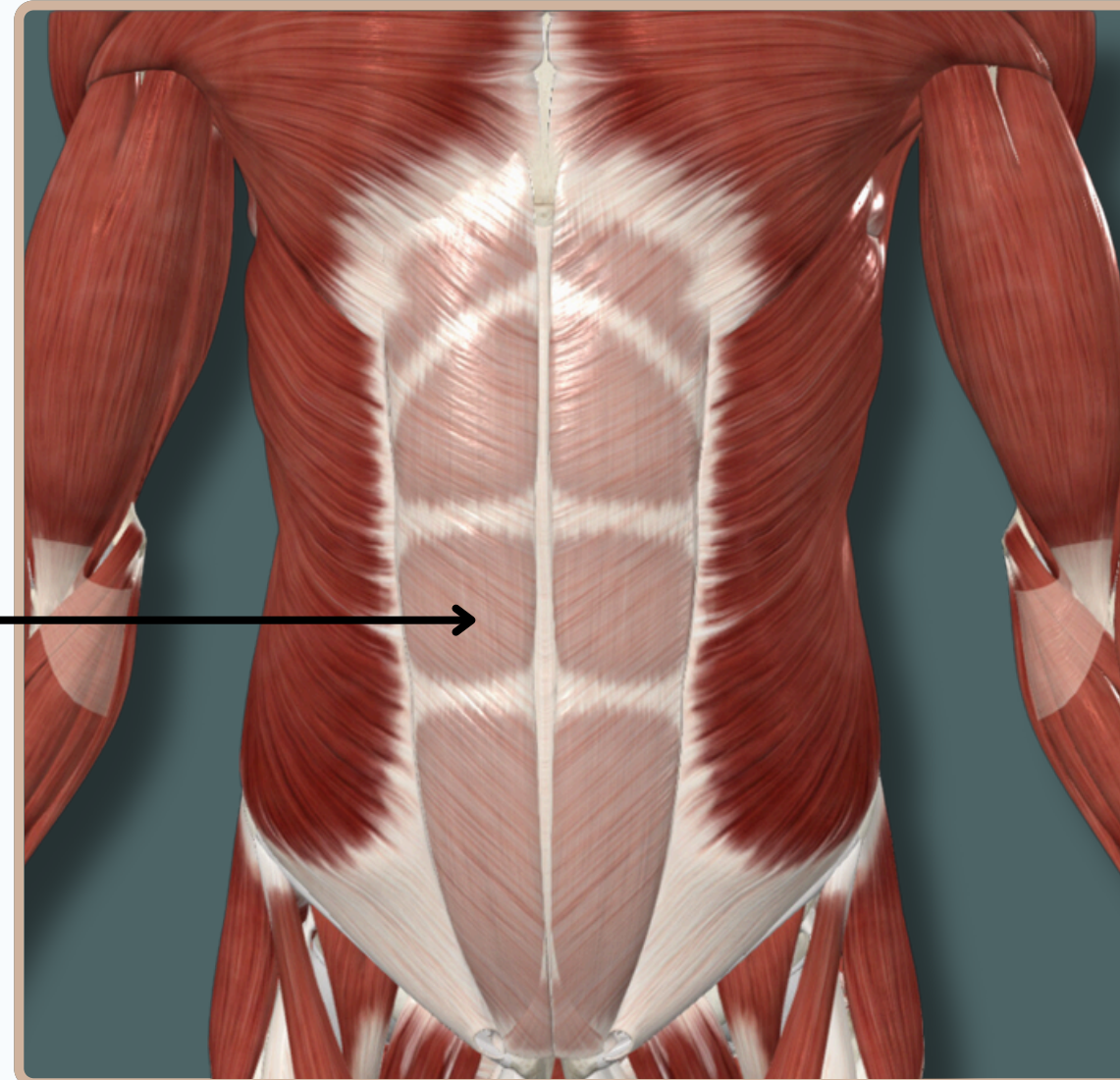
ABDOMEN

RECTUS ABDOMINIS

Rectus Sheath

long fibrous sheath Encloses the rectus abdominis and pyramidalis muscle .

Contains the **anterior rami** of lower six thoracic nerves and the **superior and inferior epigastric vessels** and lymph vessels

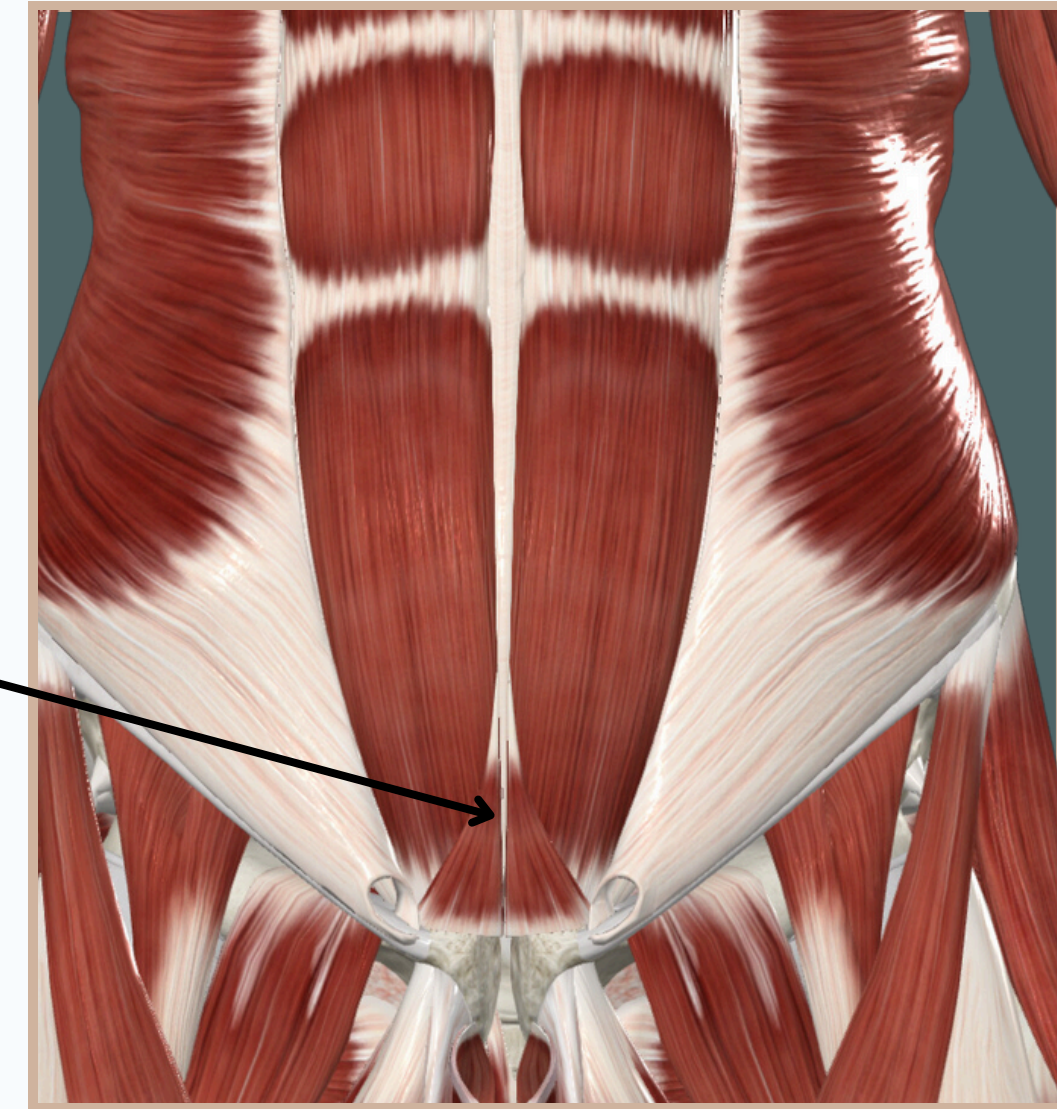
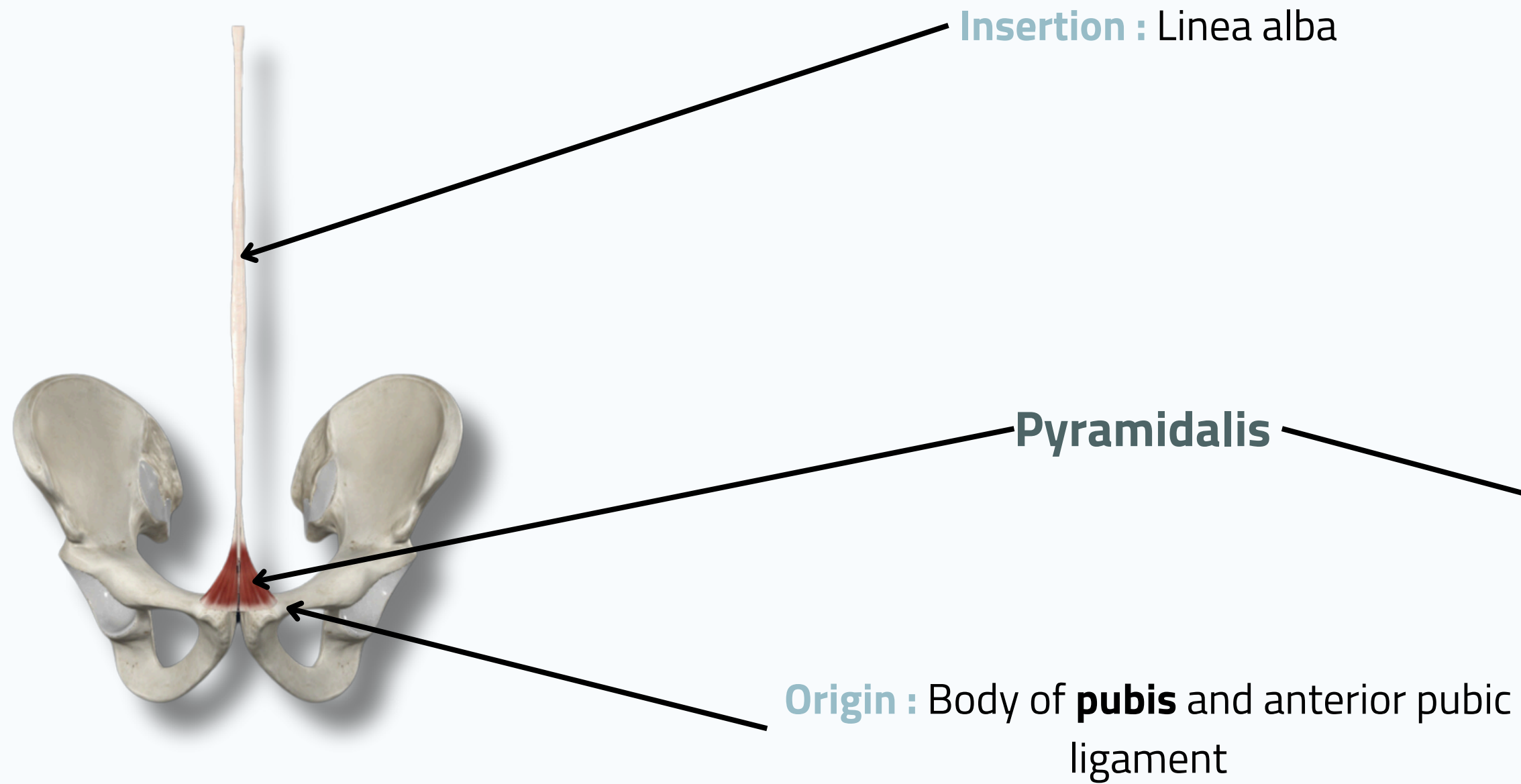


Anterior View



ABDOMEN

PYRAMIDALIS



Action :
- **Tenses** linea alba

Nerve Supply :
Anterior rami of sixth to twelfth thoracic nerves

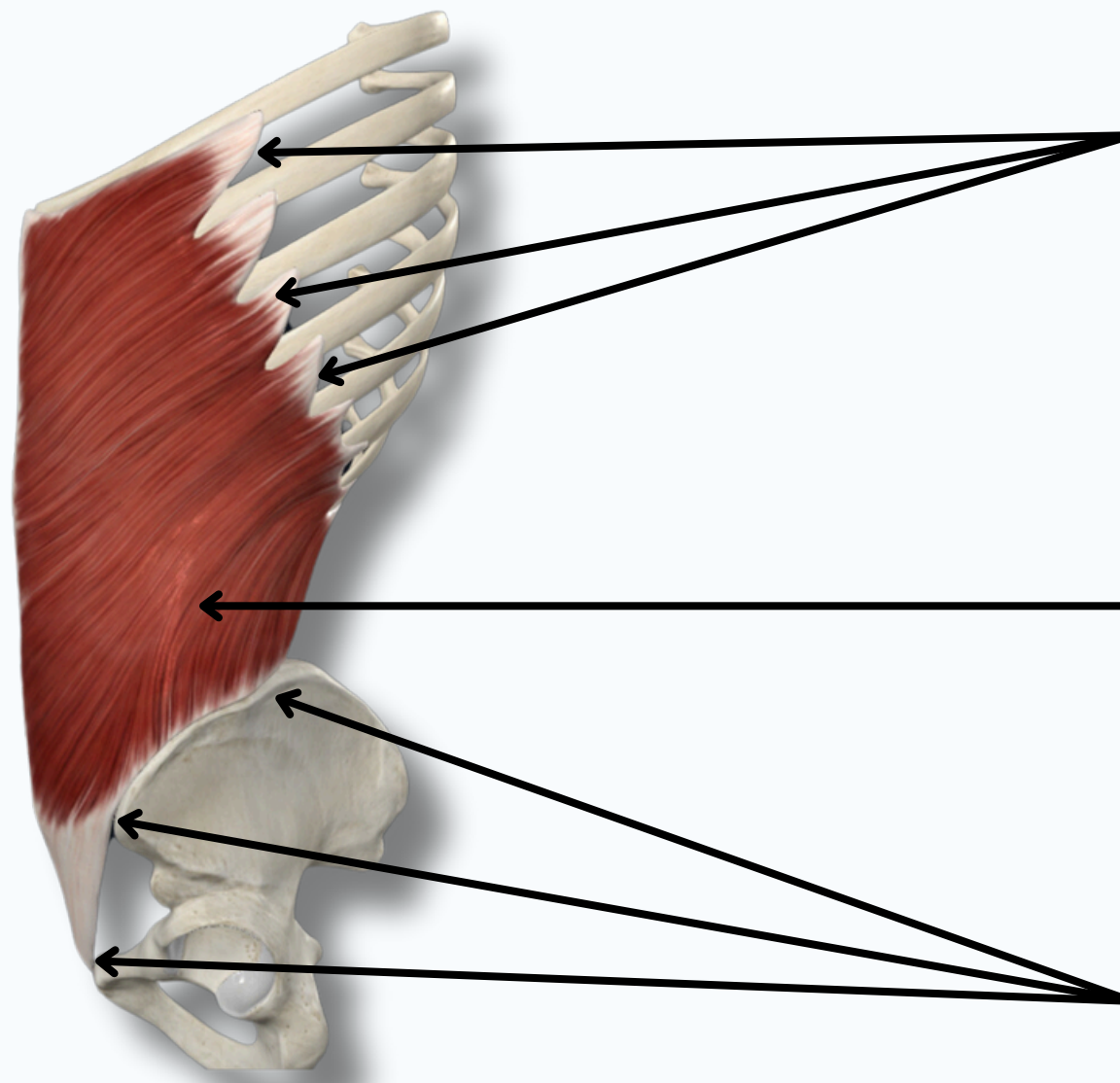
Anterior View



ABDOMEN



EXTERNAL ABDOMINAL OBLIQUE

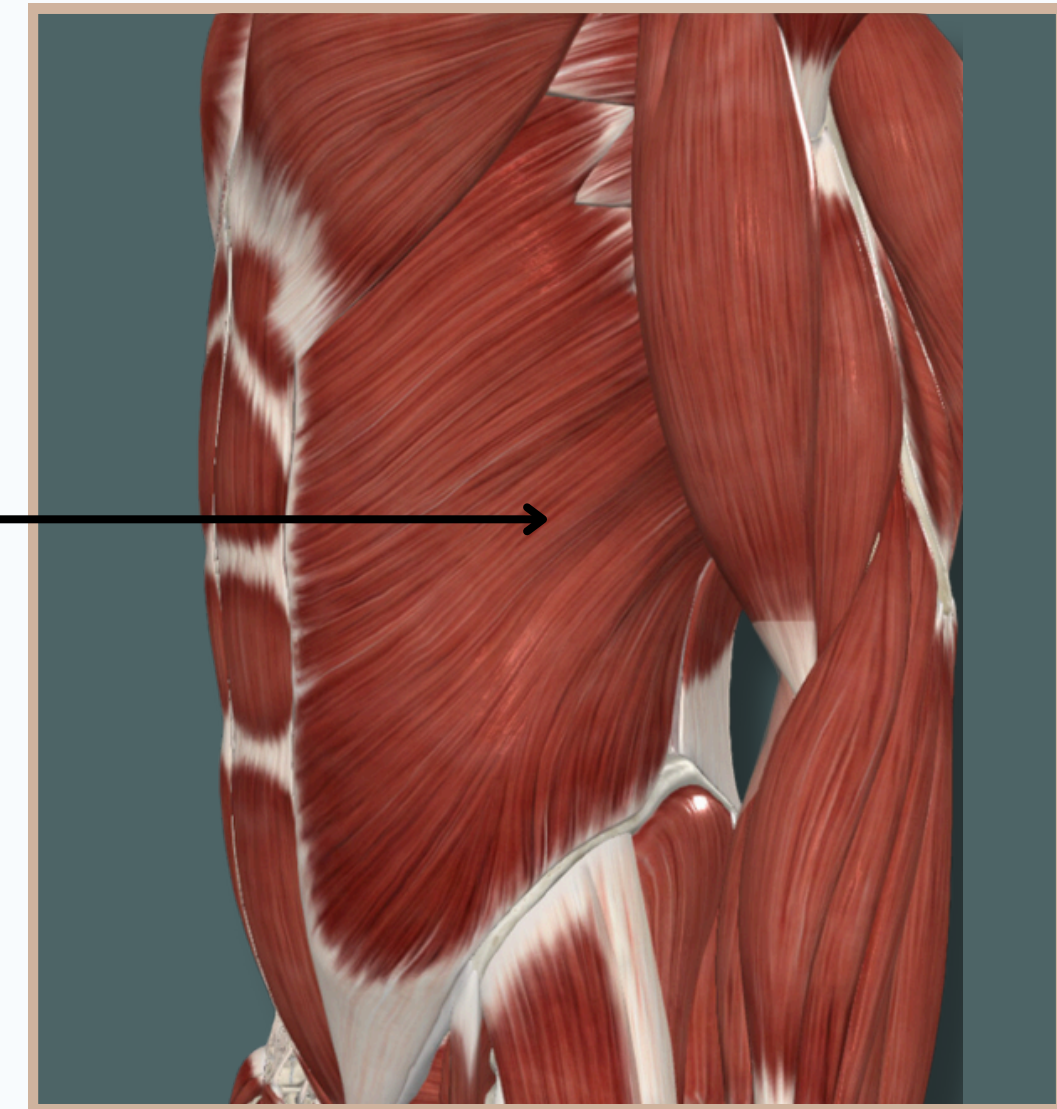

Origin : External surfaces and inferior borders of **fifth to twelfth ribs**

External Abdominal Oblique

Insertion :

- Anterior superior iliac spine
- anterior half of iliac crest
- pubic crest & pubic tubercle
- linea alba



Action :

- Flexes, laterally flexes, and rotates** trunk
- compresses** and provides **structural support** to adjacent abdominal structures

Nerve Supply :
Anterior rami of sixth to twelfth thoracic nerves

Lateral View



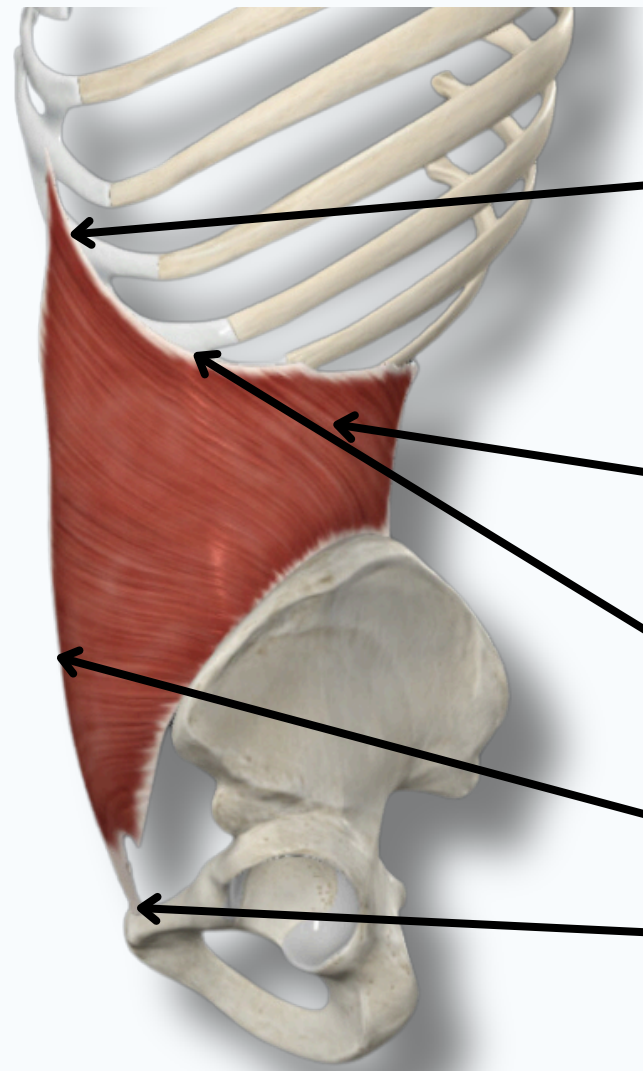
ABDOMEN



INTERNAL ABDOMINAL OBLIQUE

Origin :

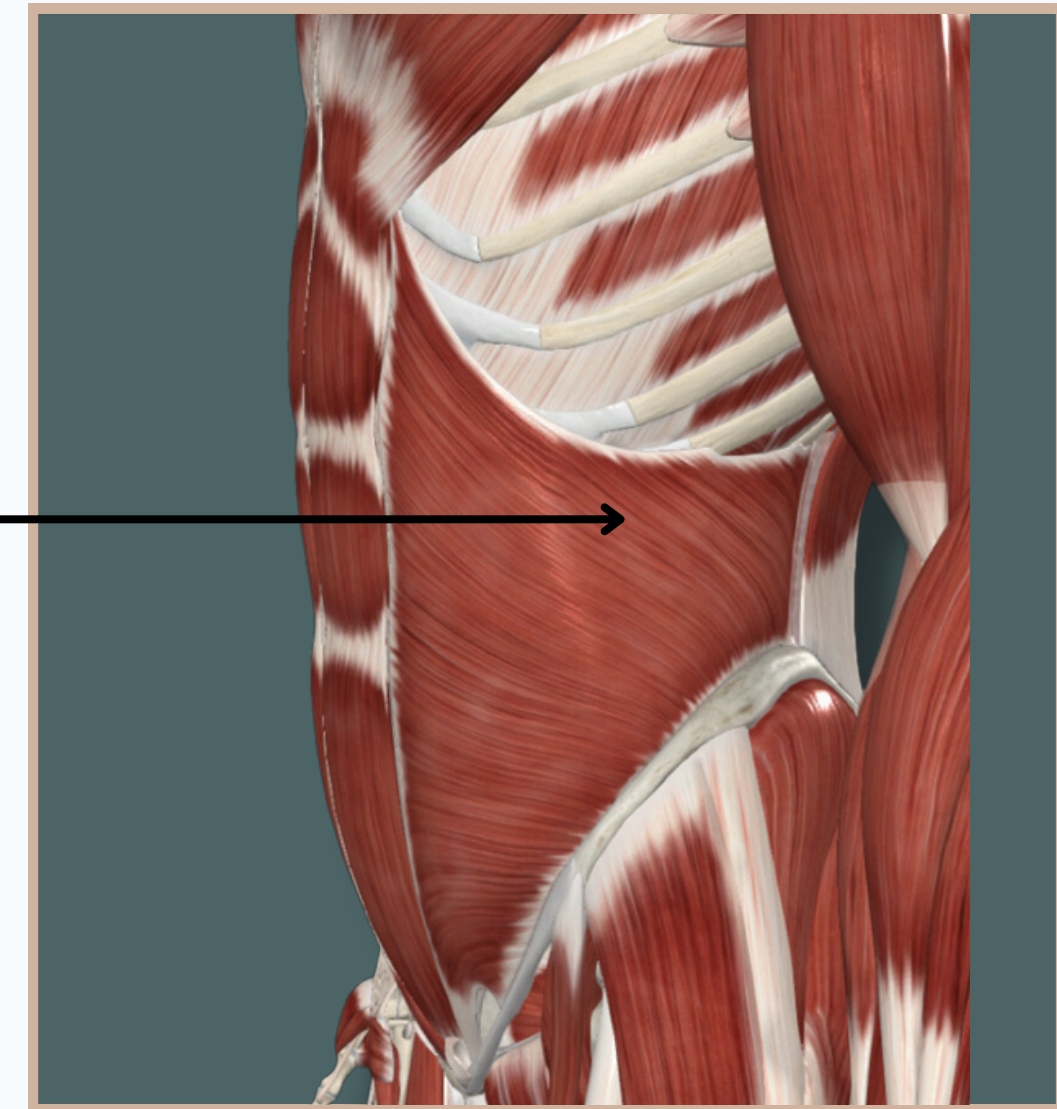
- Thoracolumbar fascia
- iliac crest
- inguinal ligament



Internal Abdominal Oblique

Insertion :

- Inferior margins of **tenth to twelfth ribs** and adjacent costal cartilages
- linea alba**
- pecten **pubis**



Action :

- Flexes, laterally flexes, and rotates** trunk
- compresses** and provides **structural support** to adjacent abdominal structures

Nerve Supply :

Anterior rami of sixth to twelfth thoracic nerves

Lateral View



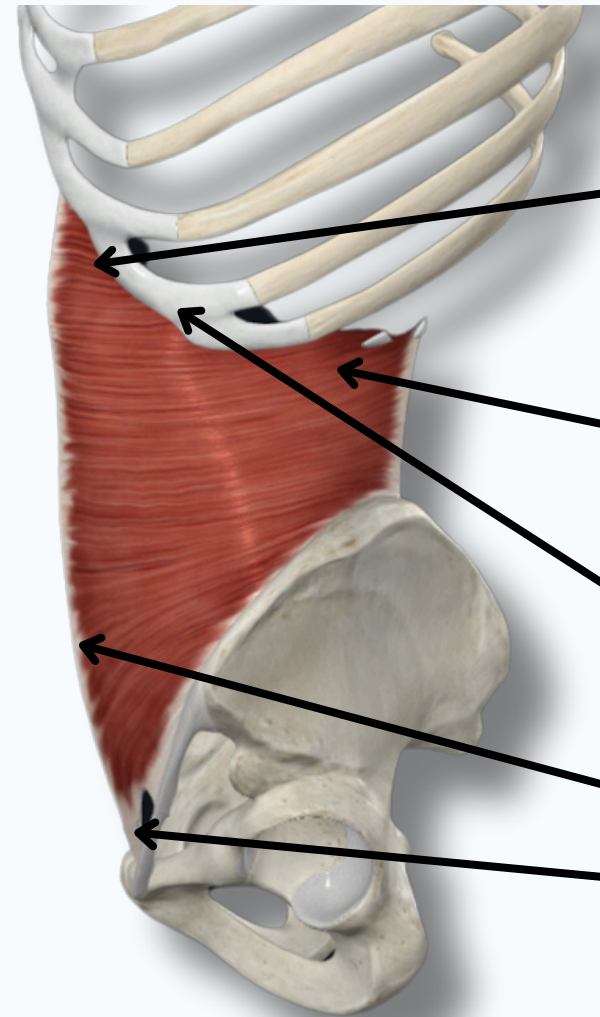
ABDOMEN

TRANSVERSUS ABDOMINIS



Origin :

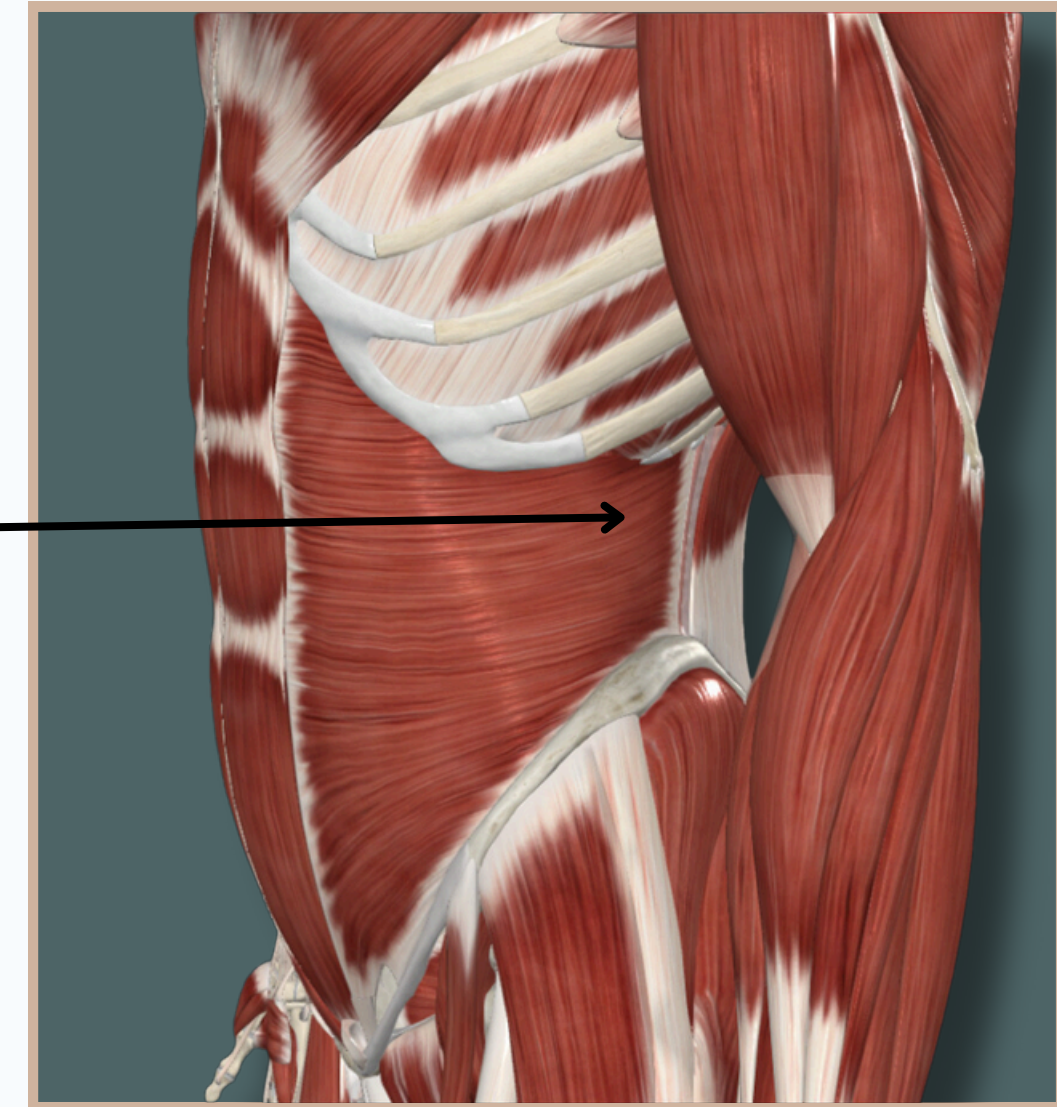
- Thoracolumbar fascia
- iliac crest
- inguinal ligament



Transversus Abdominis

Insertion :

- Inferior margins of **tenth to twelfth ribs** and adjacent costal cartilages
- linea alba**
- pecten **pubis**



Action :

- Flexes, laterally flexes, and rotates** trunk
- compresses** and provides **structural support** to adjacent abdominal structures

Nerve Supply :

Anterior rami of sixth to twelfth thoracic nerves

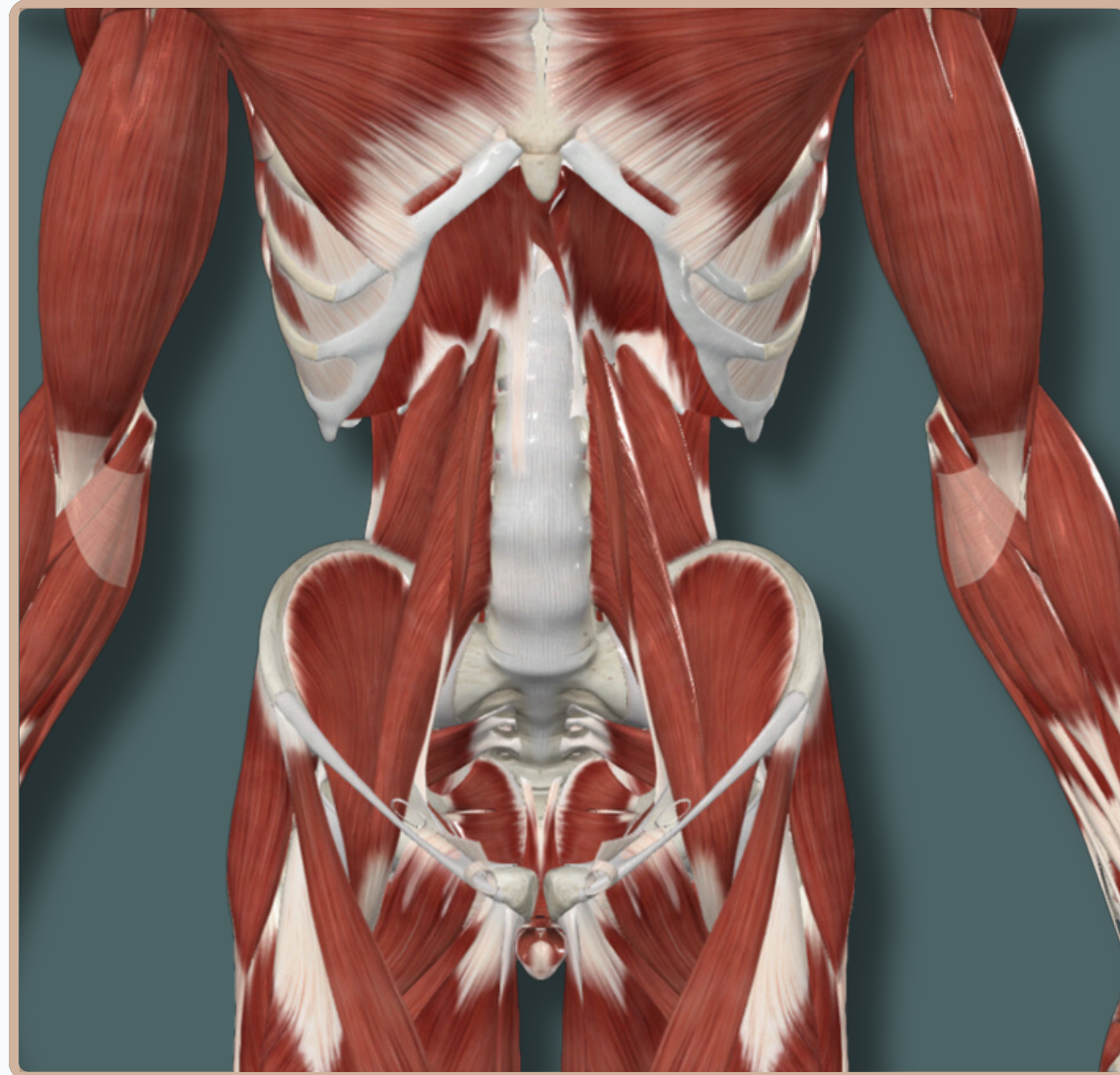
Lateral View



ABDOMEN



MUSCLES OF THE POSTERIOR ABDOMINAL WALL



Anterior View



ABDOMEN



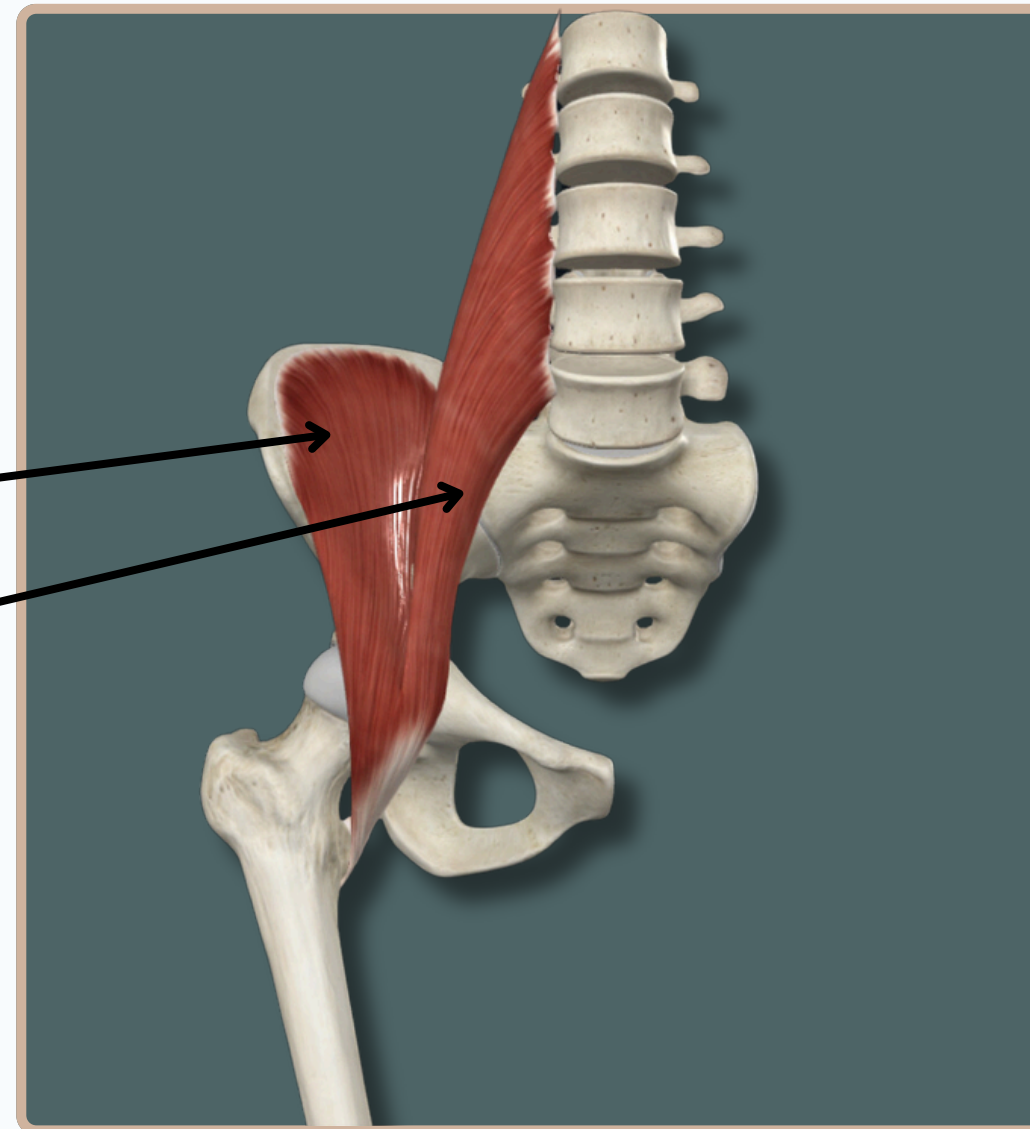
ILIPSOAS MUSCLES

Iliopsoas

Two Muscles In The Anterior
Compartment of The Thigh, Having
The Same Insertion

Which Are :

- Iliacus
- Psoas Major



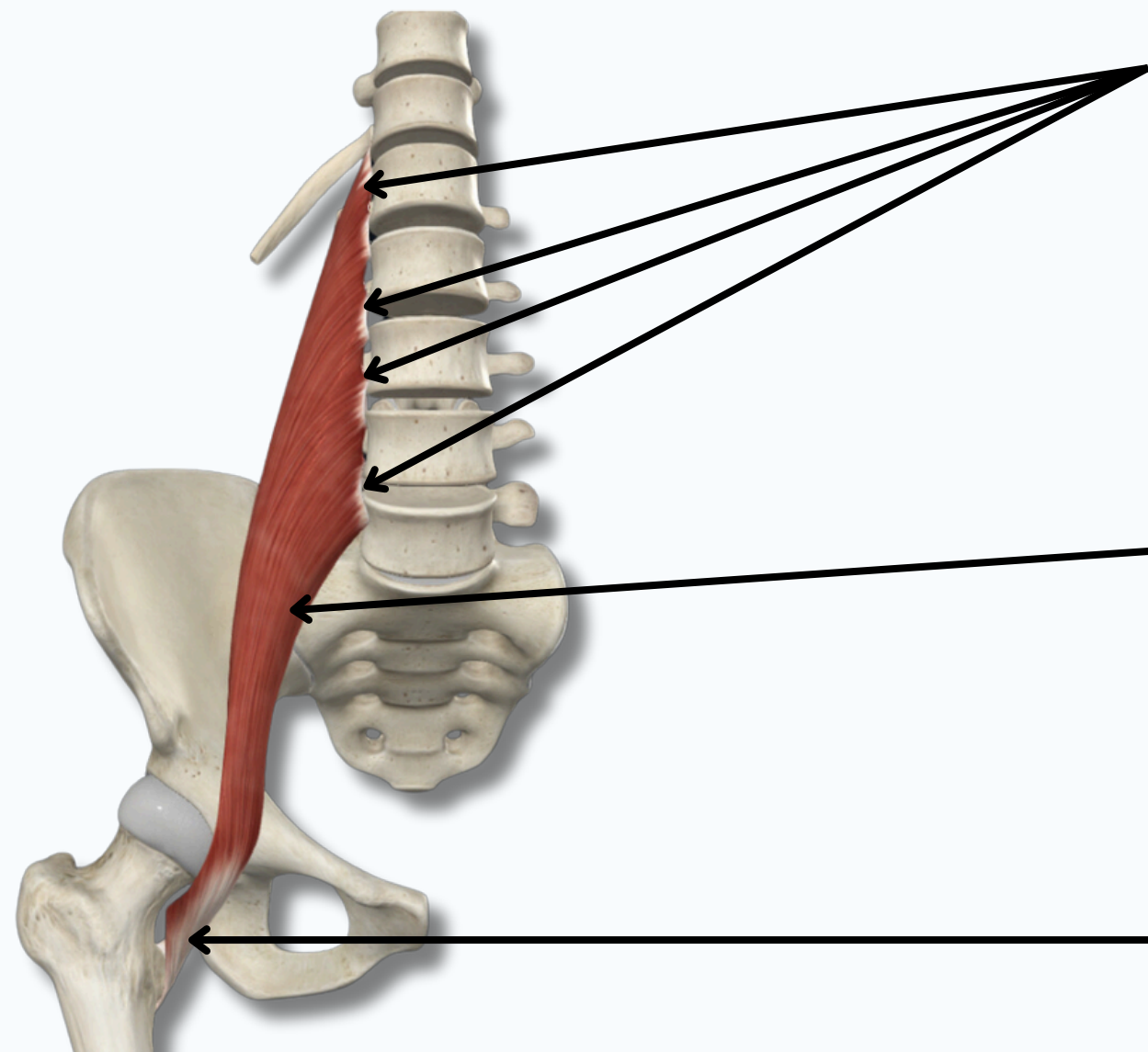
Anterior View



ABDOMEN

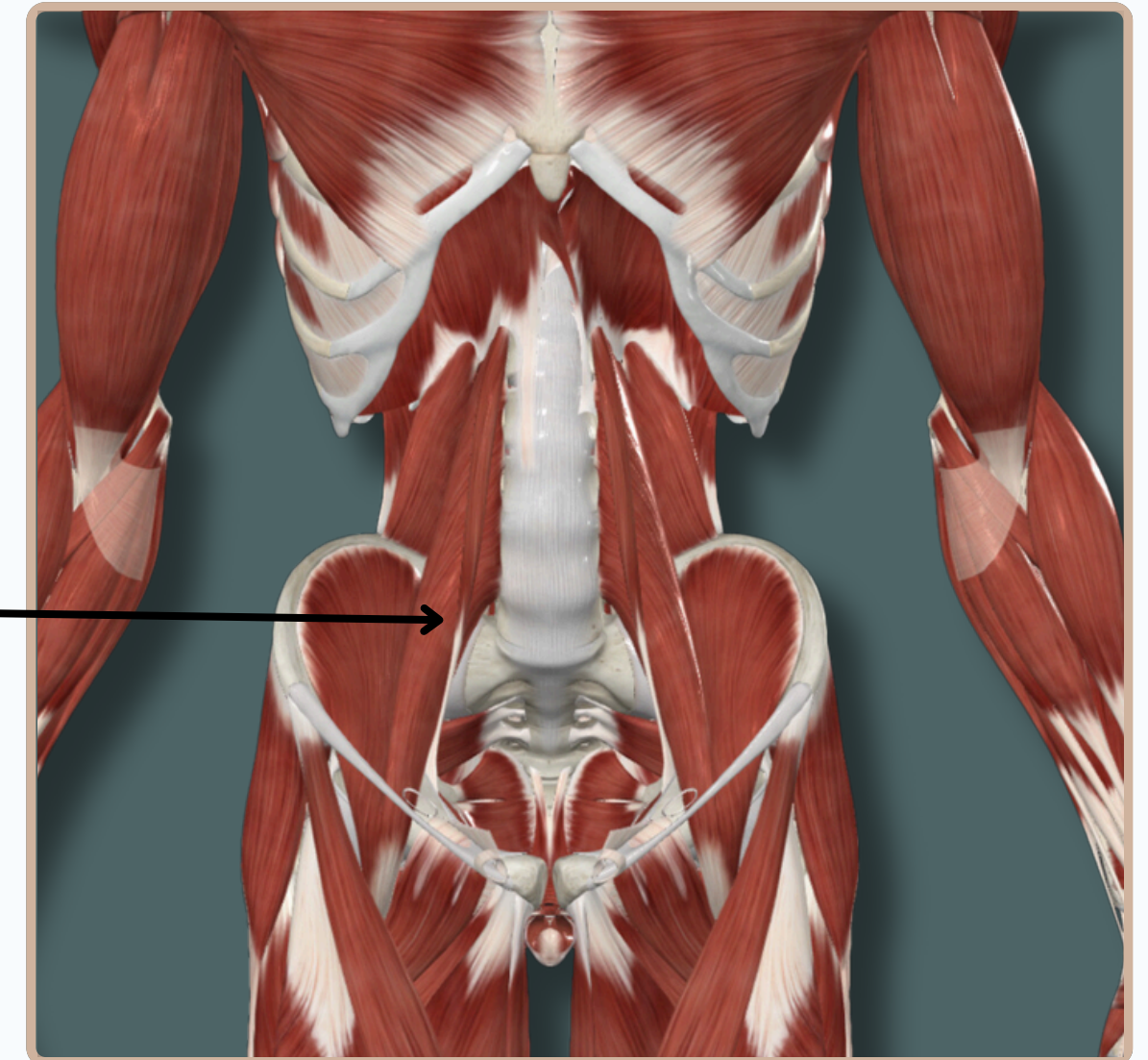
PSOAS MAJOR

Origin : Transverse processes of **L1-L5** vertebrae, vertebral bodies of **T12-L5** vertebrae, and adjacent **intervertebral discs**



Psoas Major

Insertion : Lesser trochanter of **femur**



Action :

- Flexes** thigh at **Hip** joint
- Flexes** trunk

Nerve Supply :
Femoral Nerve

Anterior View

ABDOMEN

ILIACUS

Origin : Iliac crest; superior two thirds of iliac fossa; ala of sacrum; anterior sacroiliac ligaments

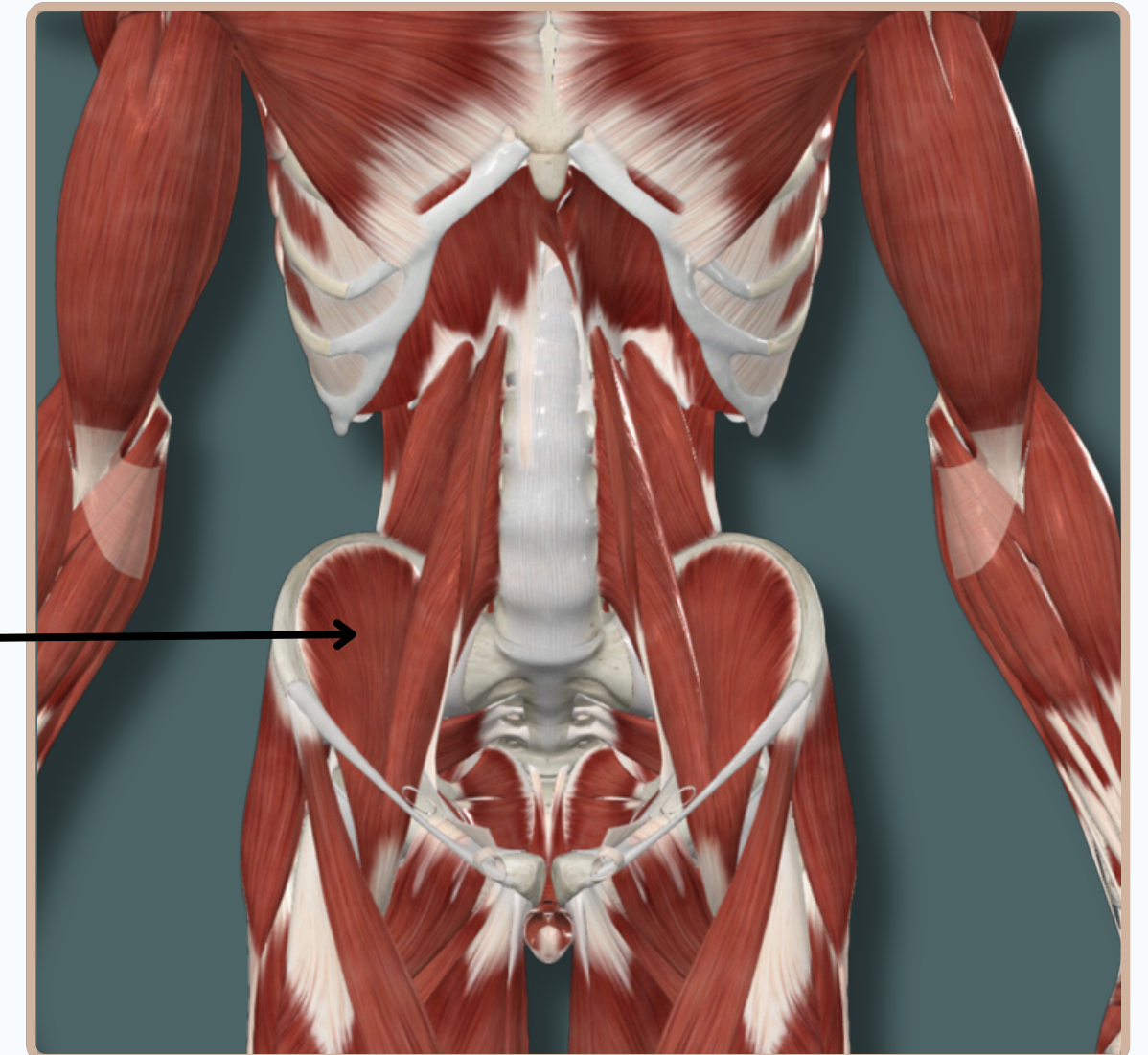
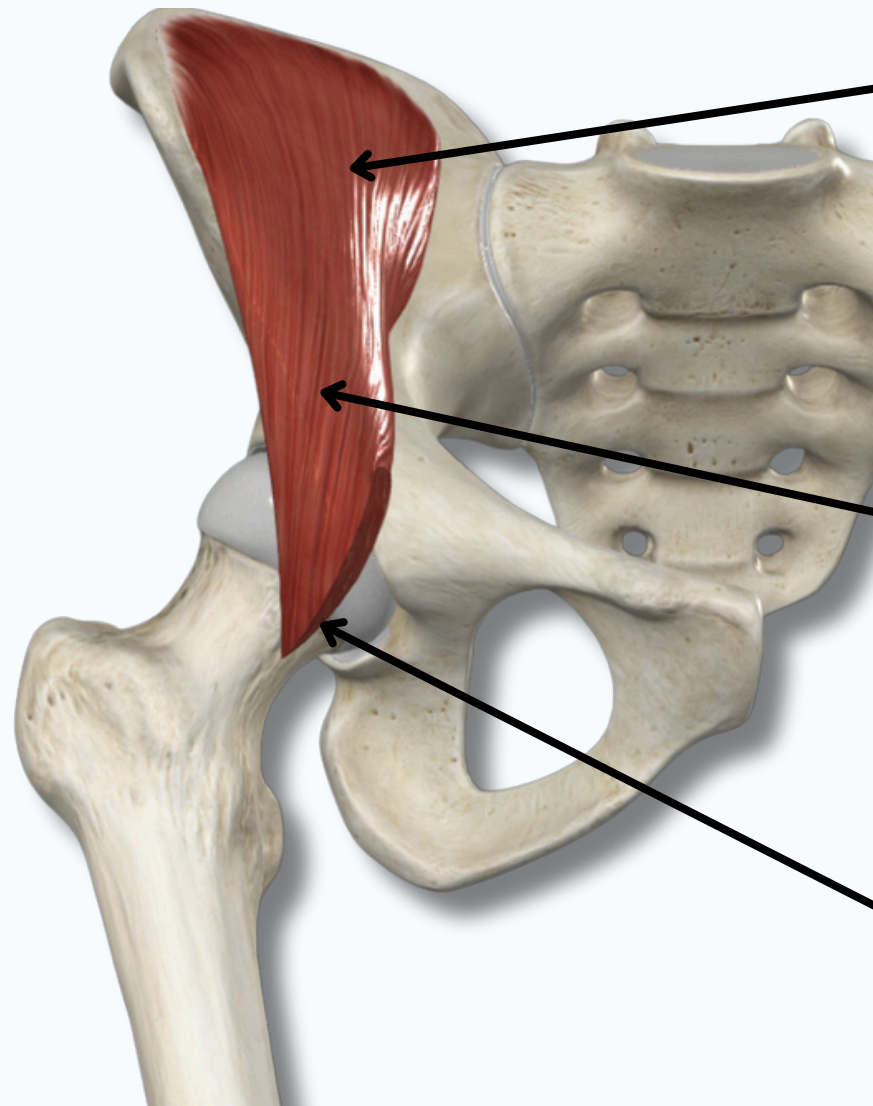
Insertion : Lesser trochanter of femur, via tendon of psoas major

Action :

- Flexes thigh at Hip joint
- Flexes trunk

Nerve Supply :
Femoral Nerve

Anterior View

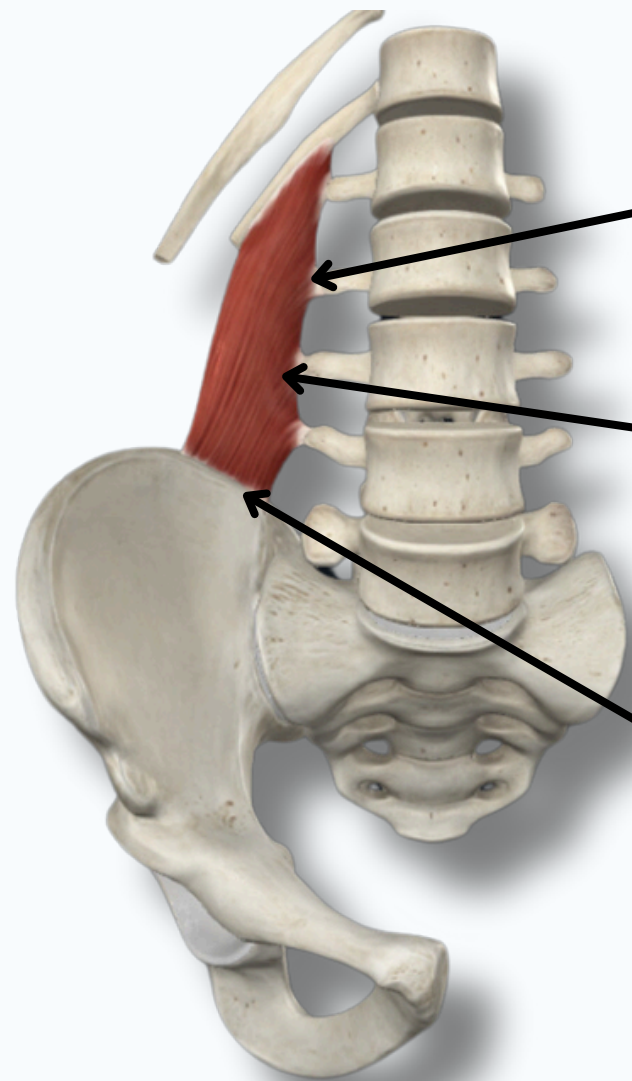




ABDOMEN



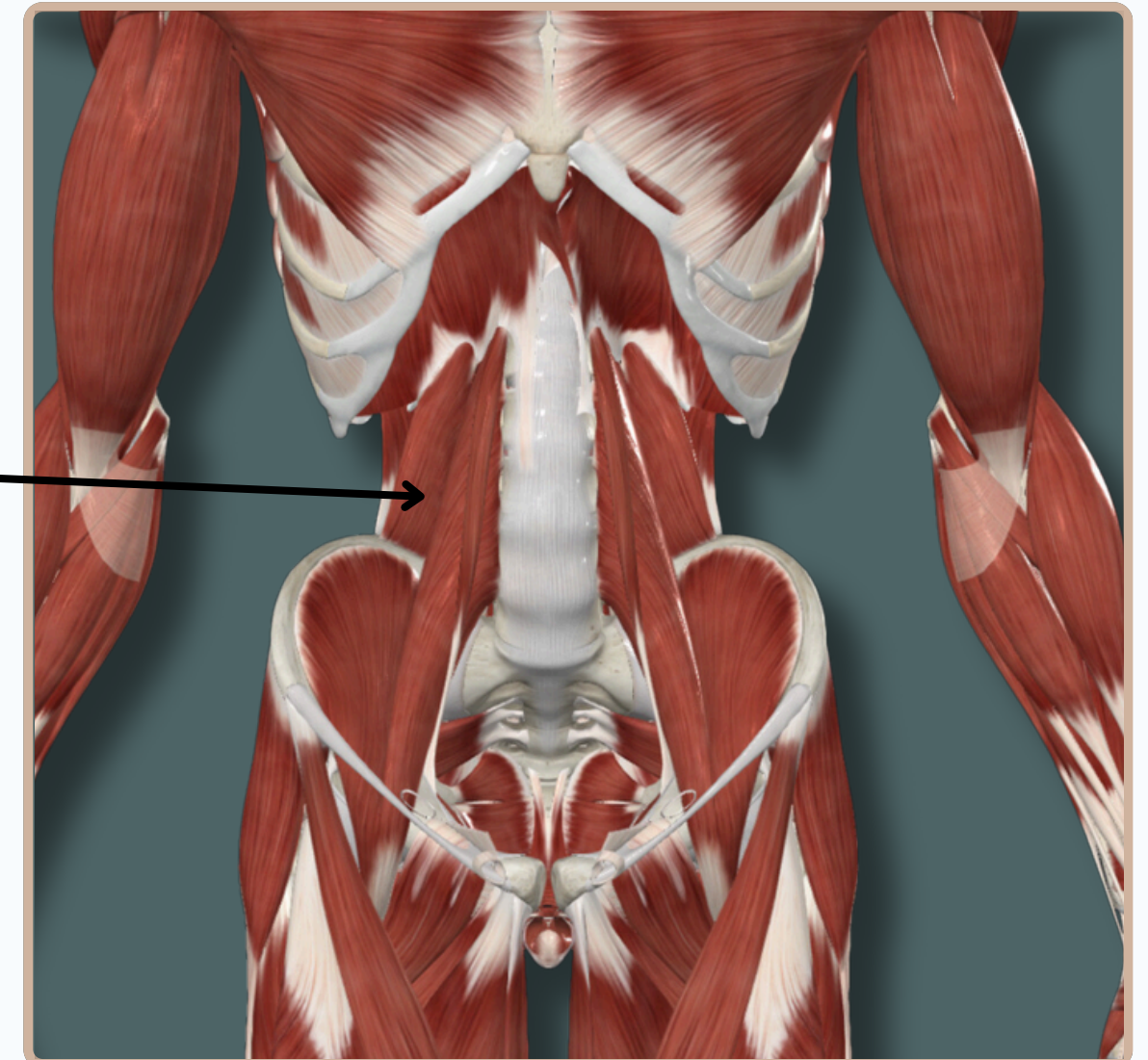
QUADRATUS LUMBORUM



Origin : Posterior half of **iliac crest** and iliolumbar ligament

Quadratus Lumborum

Insertion : Inferior border of twelfth rib, transverse processes of first to fourth lumbar vertebrae



Action :

- Extends** and **laterally** flexes trunk
- stabilizes** twelfth rib during inspiration

Nerve Supply :

Anterior rami of twelfth thoracic and first to fourth lumbar nerves.

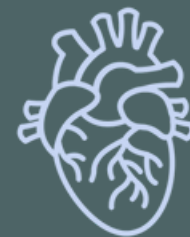Anterior View

THANK YOU

EDITED BY



SATURN
MEDIC



ARECH

© ALL COPYRIGHT ARE RESERVED FOR
SATURN MEDIC AND ARECH

WWW.SATURNMEDIC.COM