

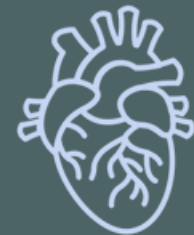# ANATOMY OF THORAX REGION

## PRACTICAL LECTURE - 5 - LYMPHATIC SYSTEM

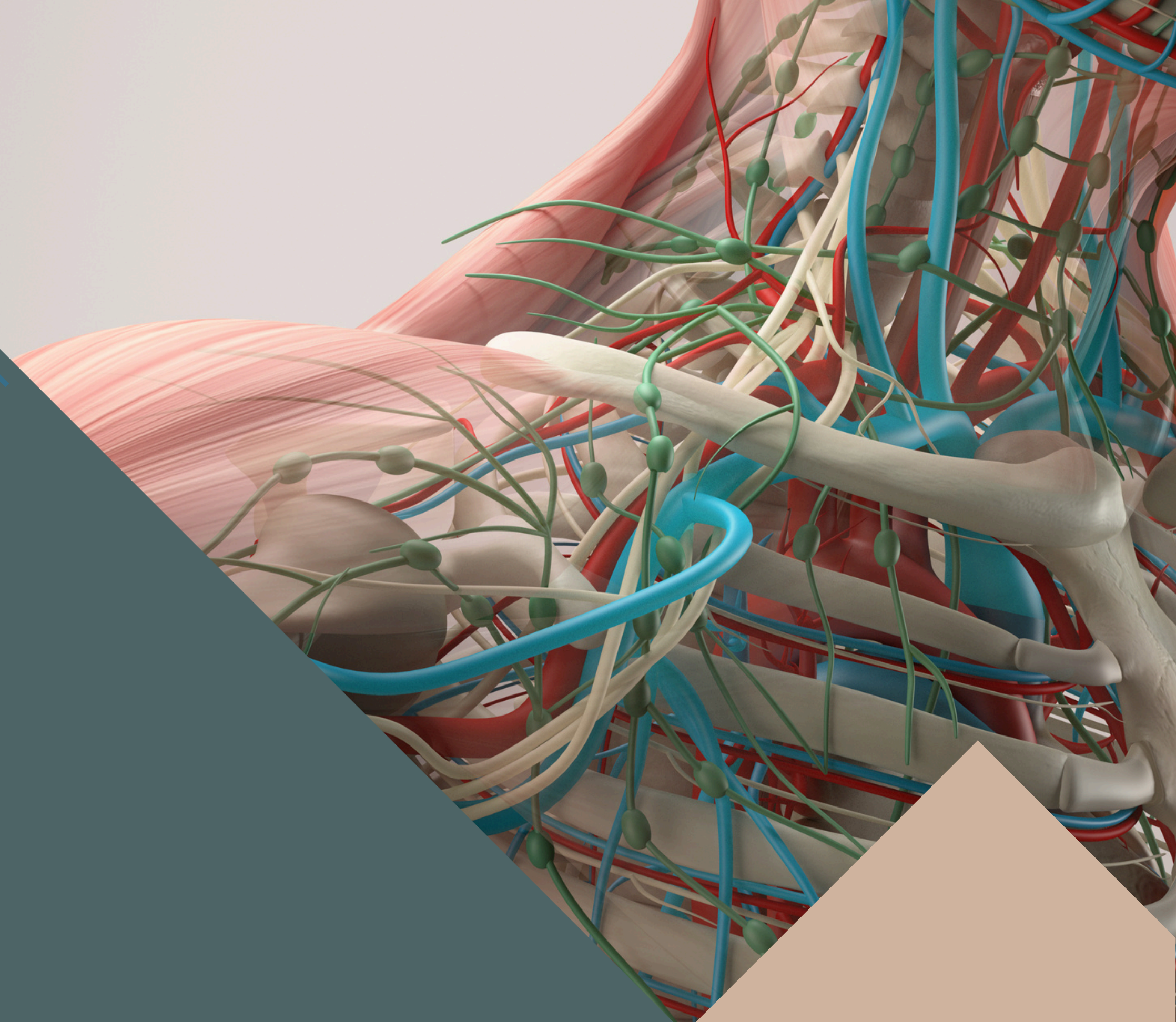
EDITED BY



SATURN  
MEDIC



ARECH

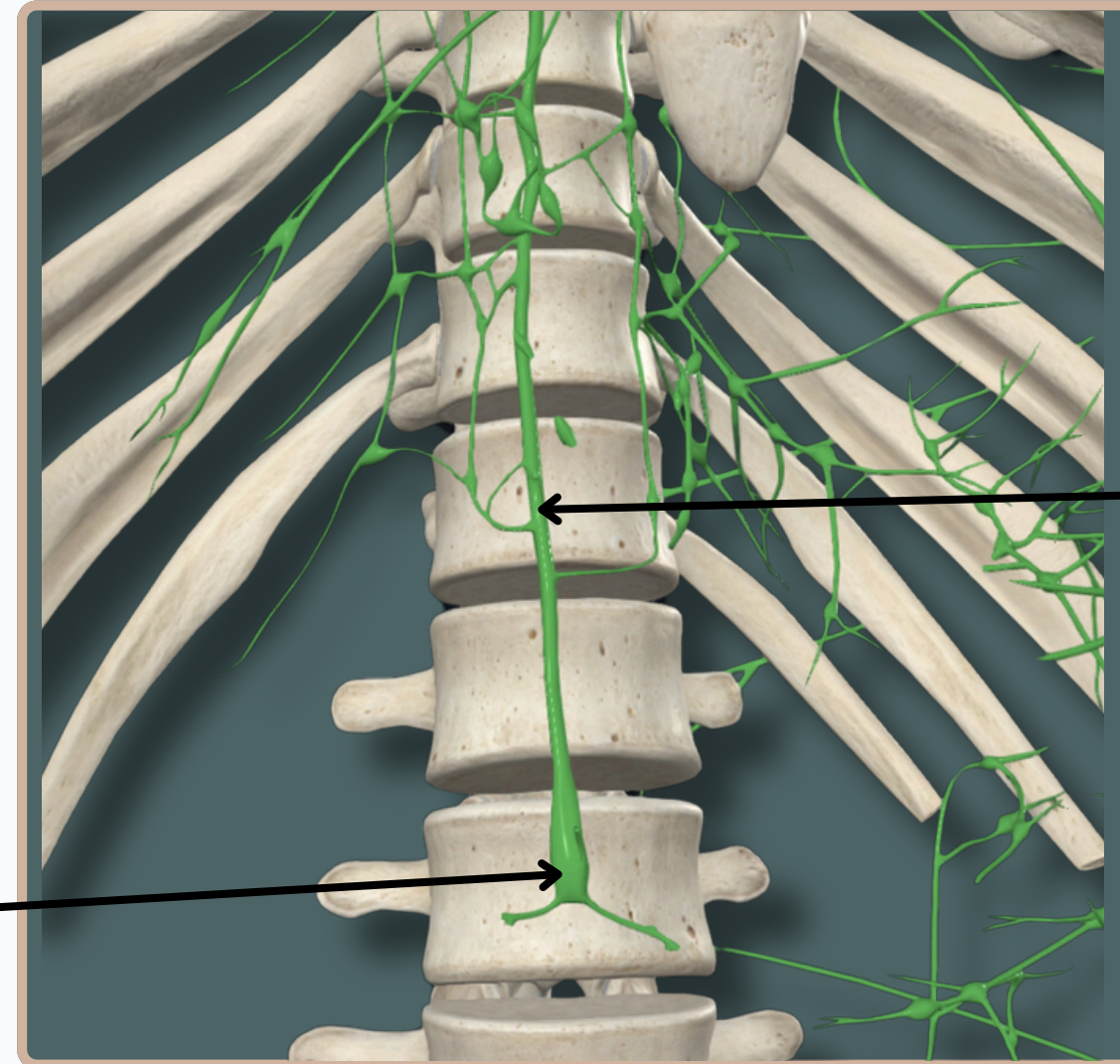


ALL COPYRIGHT ARE RESERVED FOR  
SATURN MEDIC AND ARECH

[WWW.SATURNMEDIC.COM](http://WWW.SATURNMEDIC.COM)



# LYMPHATIC SYSTEM



## Cisterna Chyli

The Thoracic Duct begins in the abdomen below the diaphragm as a **sac** called cisterna chyli

## Thoracic Duct

It is the **main** lymphatic channel of the body

**Anterior View**



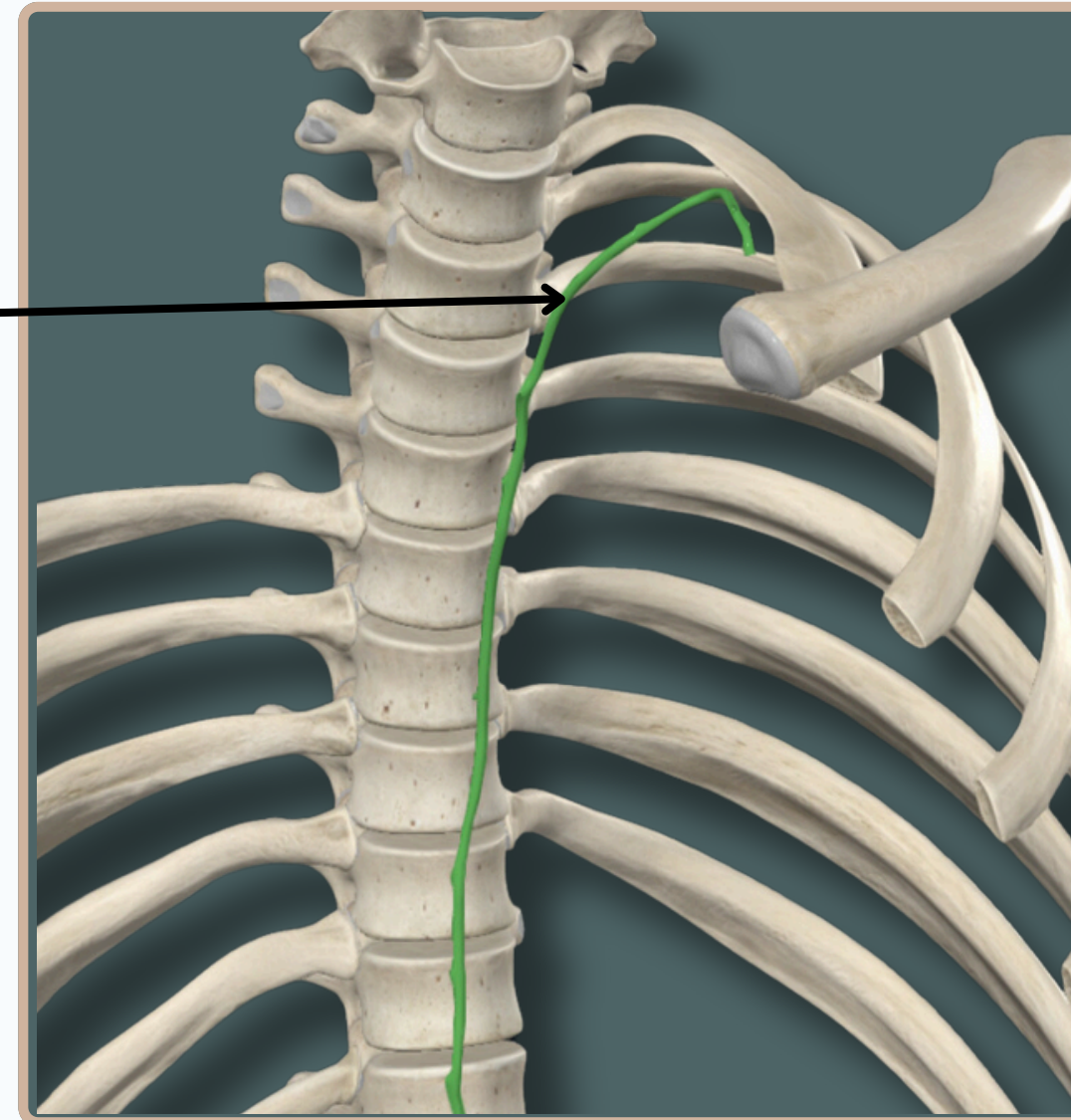
## Thoracic Duct

It is the **main** lymphatic channel of the body

It Receives From The **Entire** Body,

**Except :**

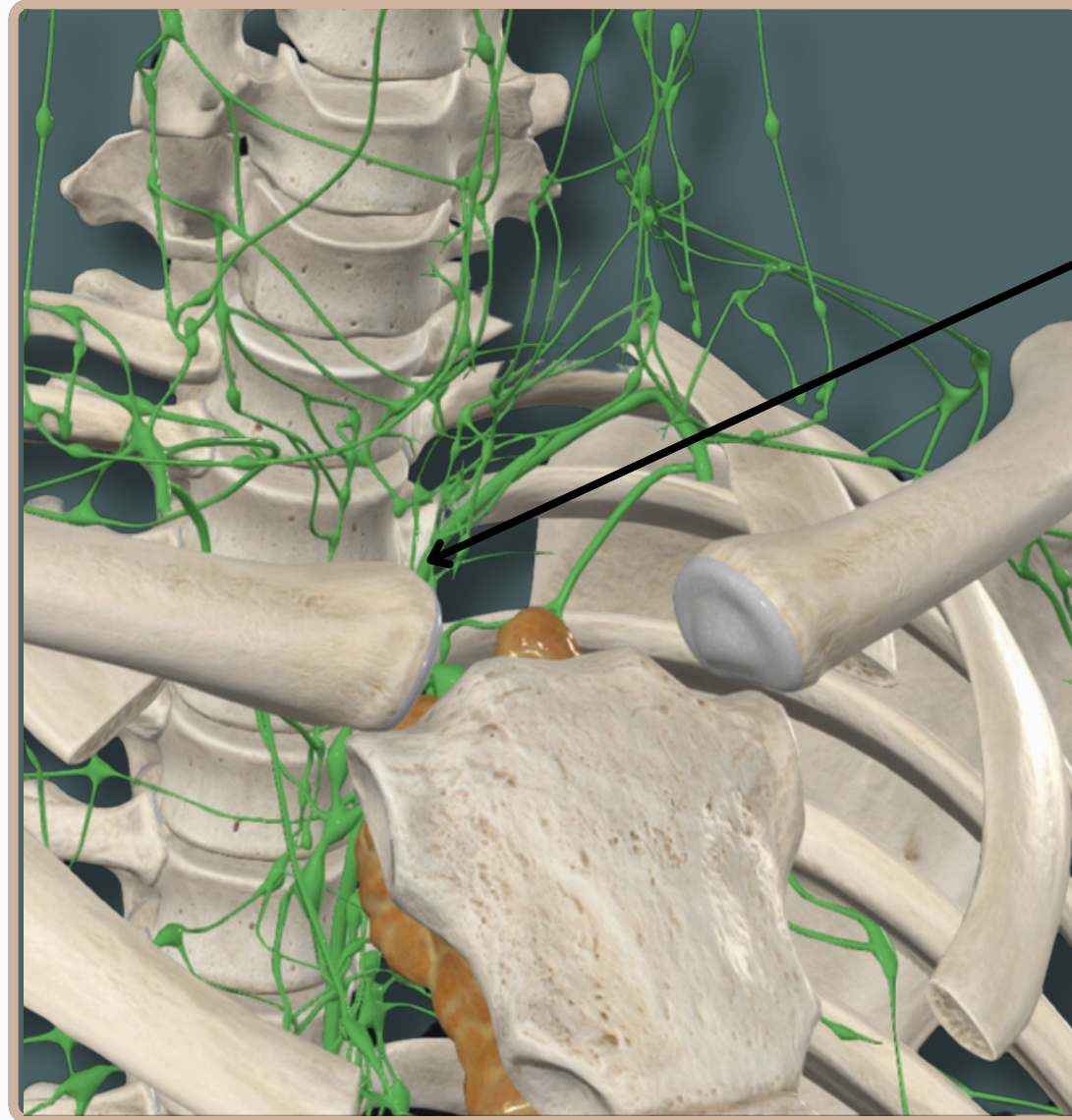
1. **Right** upper limb
2. **Right** side of head & neck
3. **Right** upper thorax



**Anterior View**



# LYMPHATIC SYSTEM

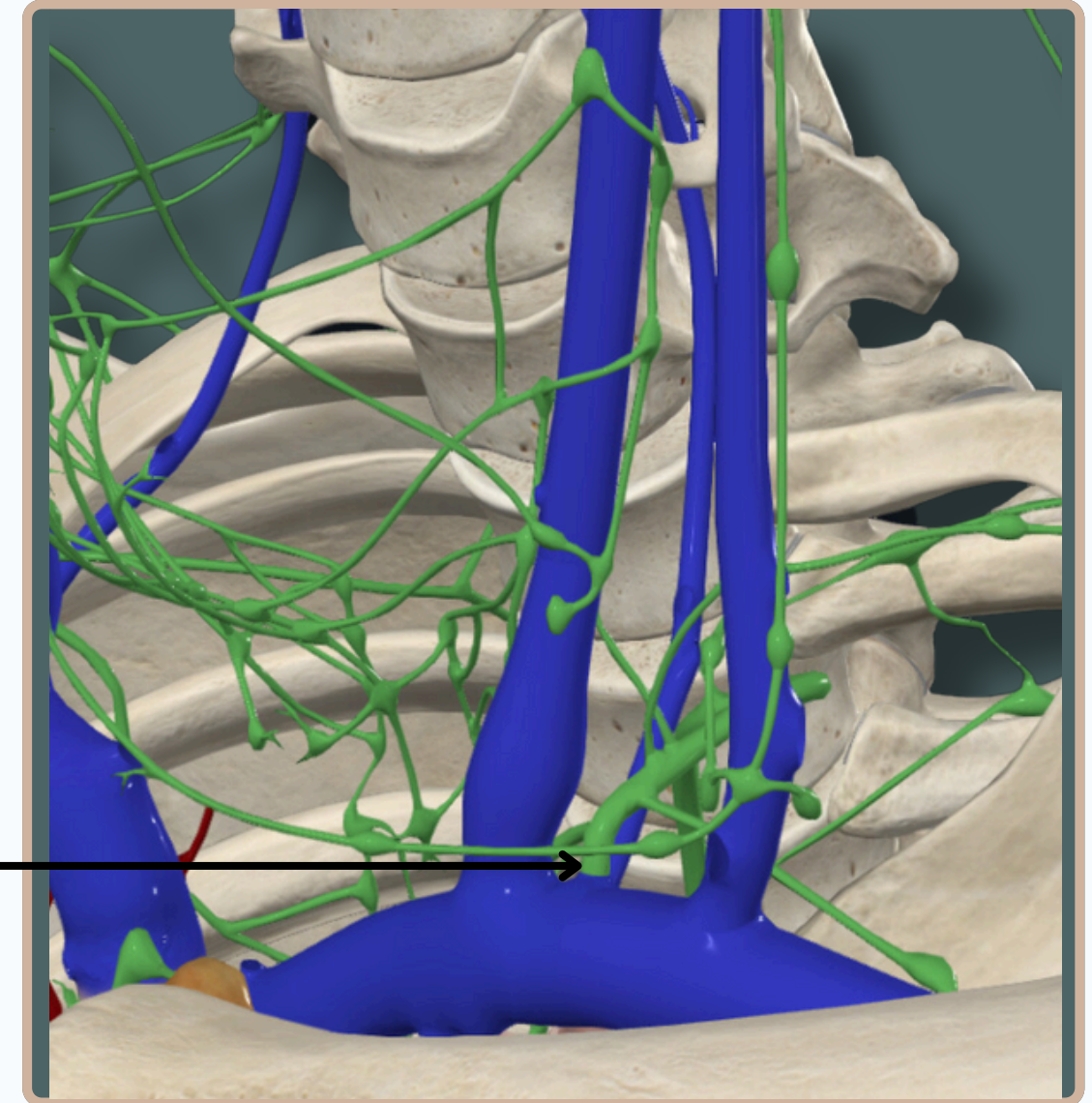


## Thoracic Duct

It deviates from the right to the left side of the esophagus at the level of the **sternal** angle

## Thoracic Duct

it ends at the **junction** of the **left** internal **jugular** and **subclavian** veins

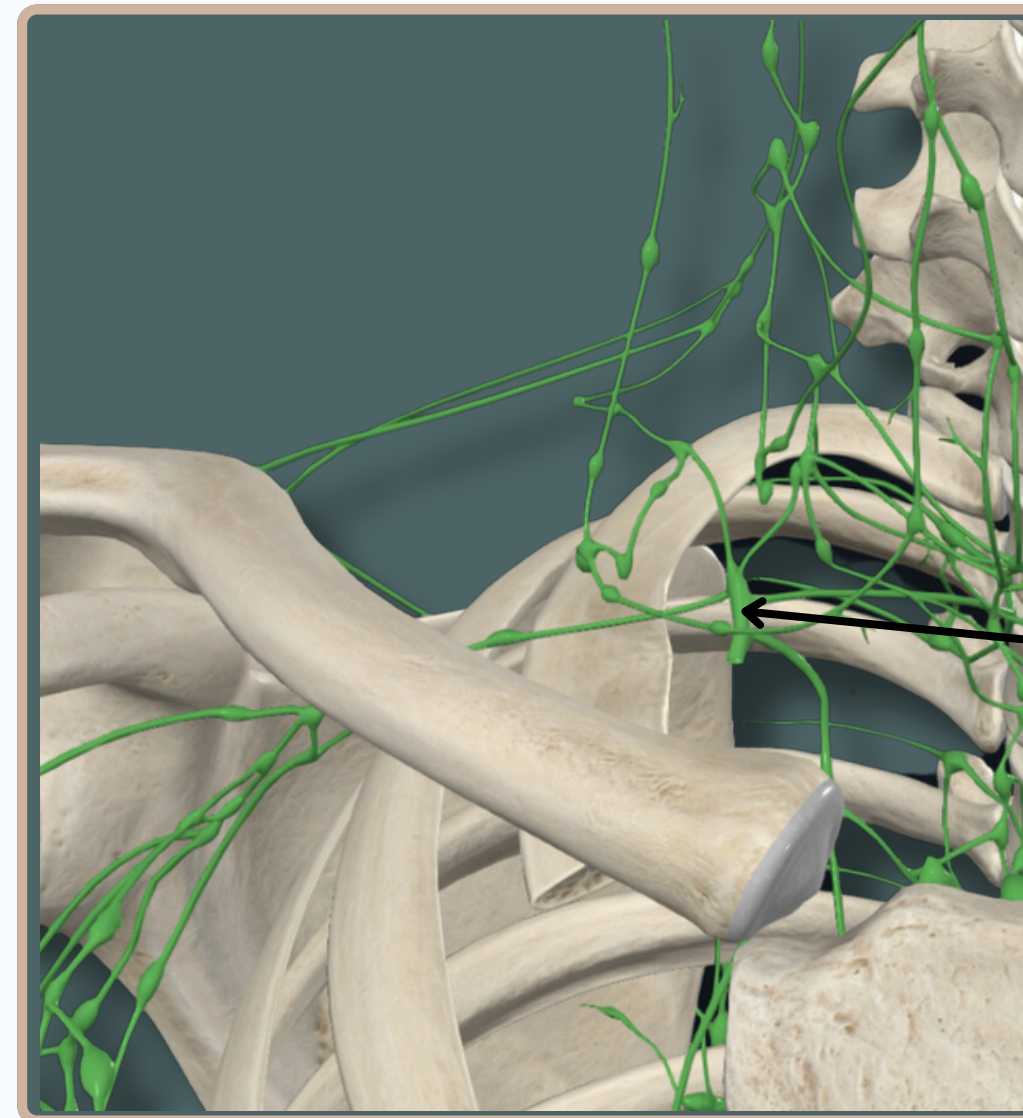


**Anterior View**





# LYMPHATIC SYSTEM



## Right Lymphatic Duct

It Receives From :

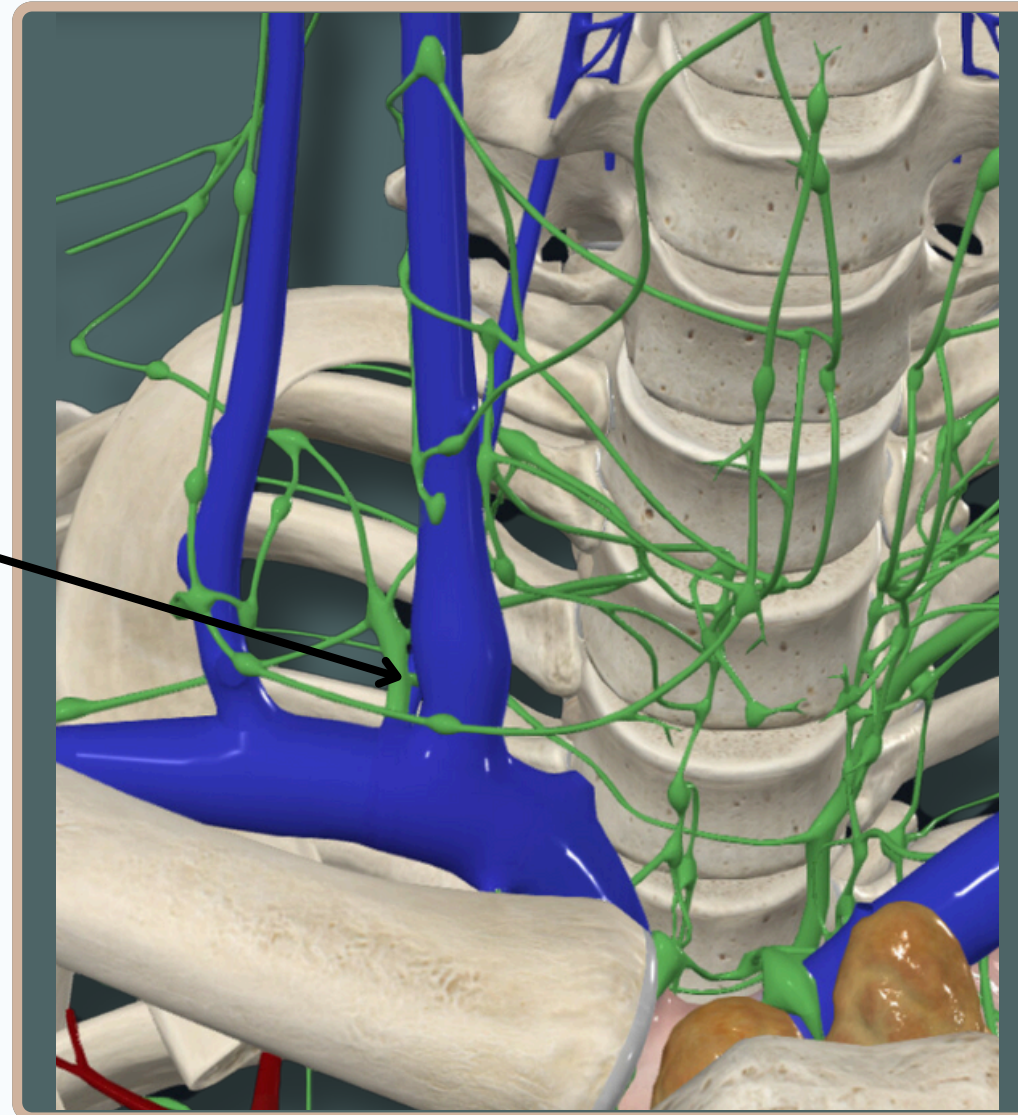
1. **Right** upper limb
2. **Right** side of head & neck
3. **Right** upper thorax

**Anterior View**





**Right Lymphatic Duct**  
ends into the junction of the **right**  
internal **jugular** and **subclavian** veins.

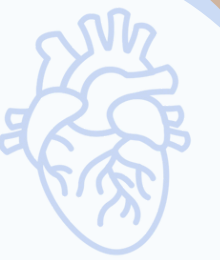

**Anterior View**





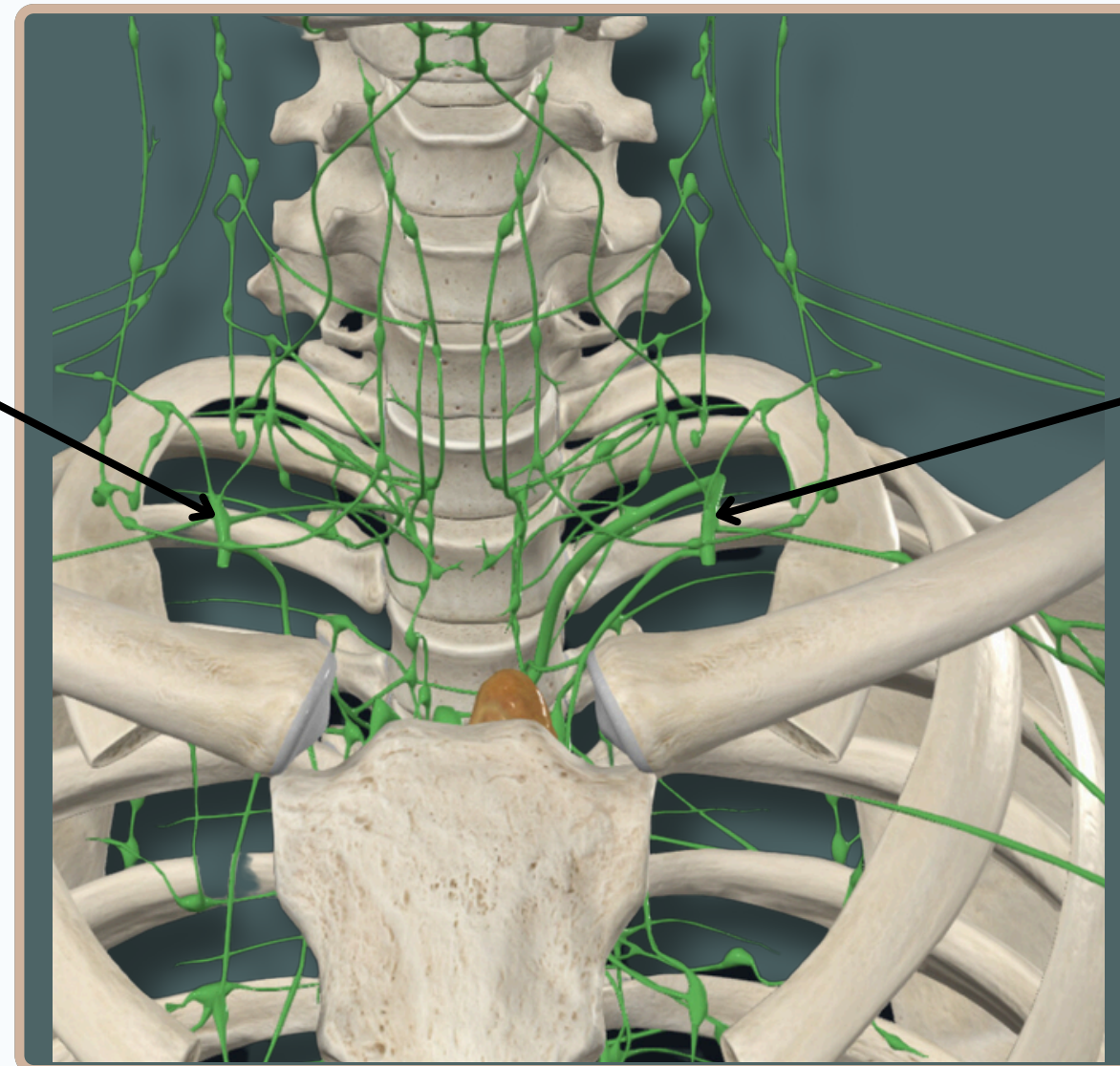
# LYMPHATIC SYSTEM



## Right Lymphatic Duct

It Receives From :

1. **Right** upper limb
2. **Right** side of head & neck
3. **Right** upper thorax



## Thoracic Duct

It is the **main** lymphatic channel of the body

It Receives From The **Entire** Body,

**Except :**

1. **Right** upper limb
2. **Right** side of head & neck
3. **Right** upper thorax

**Anterior View**



# THANK YOU

EDITED BY



SATURN  
MEDIC



ARECH

© ALL COPYRIGHT ARE RESERVED FOR  
SATURN MEDIC AND ARECH

[WWW.SATURNMEDIC.COM](http://WWW.SATURNMEDIC.COM)