

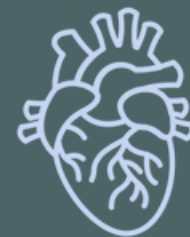ANATOMY OF THORAX REGION

PRACTICAL LECTURE - 4 - THE HEART

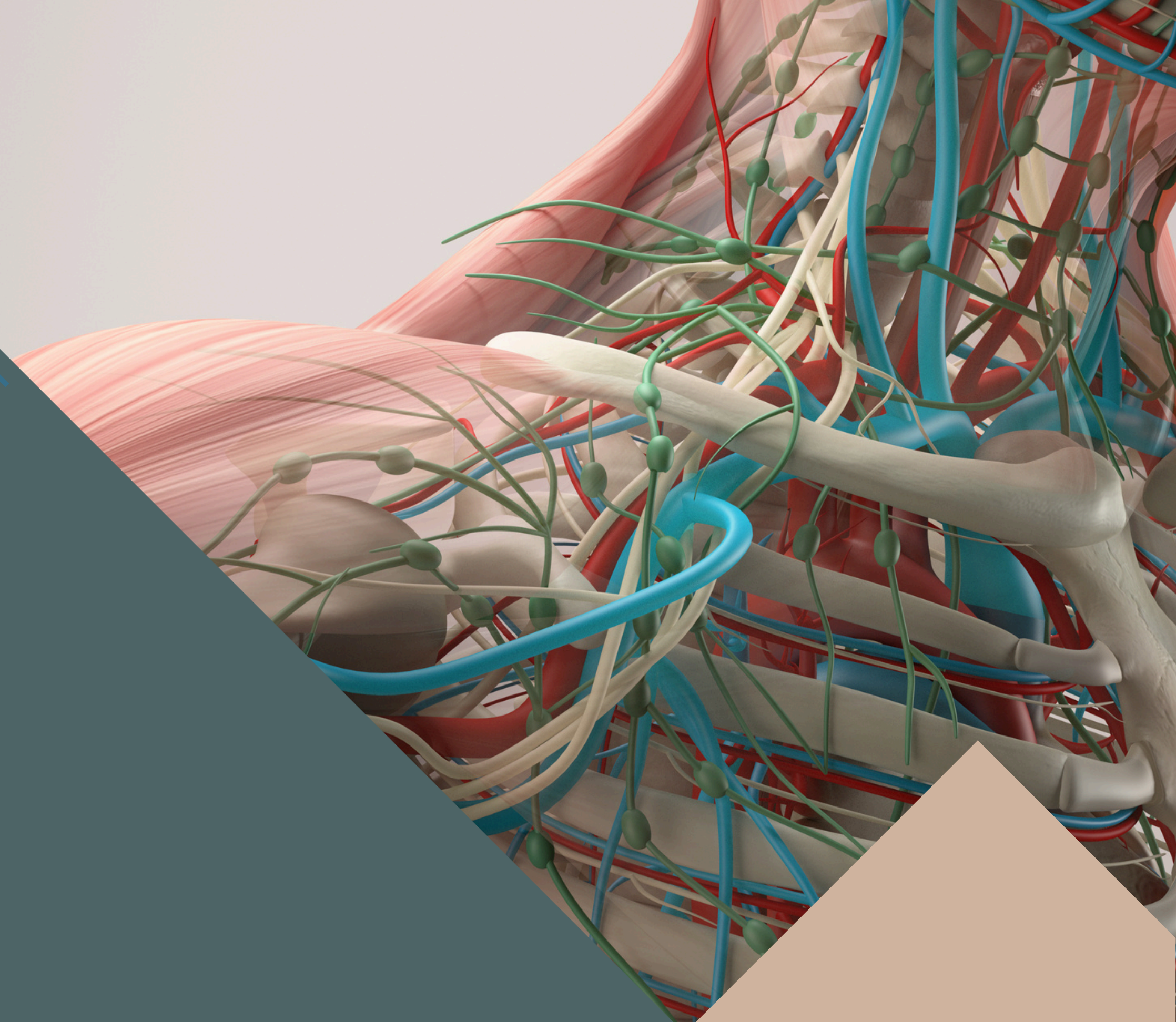
EDITED BY



SATURN
MEDIC



ARECH



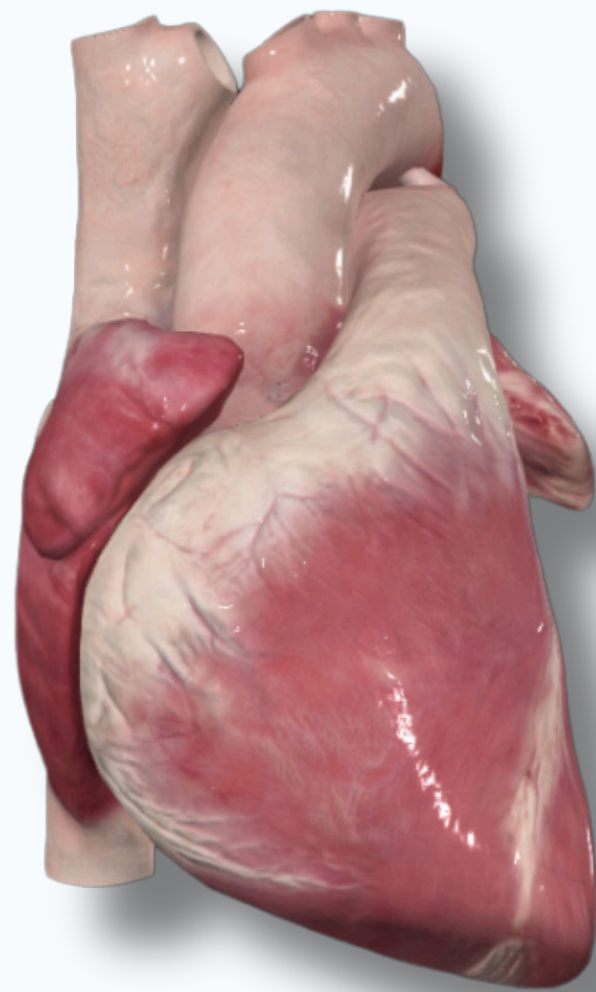
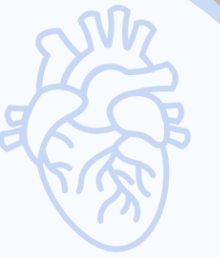© ALL COPYRIGHT ARE RESERVED FOR
SATURN MEDIC AND ARECH

WWW.SATURNMEDIC.COM

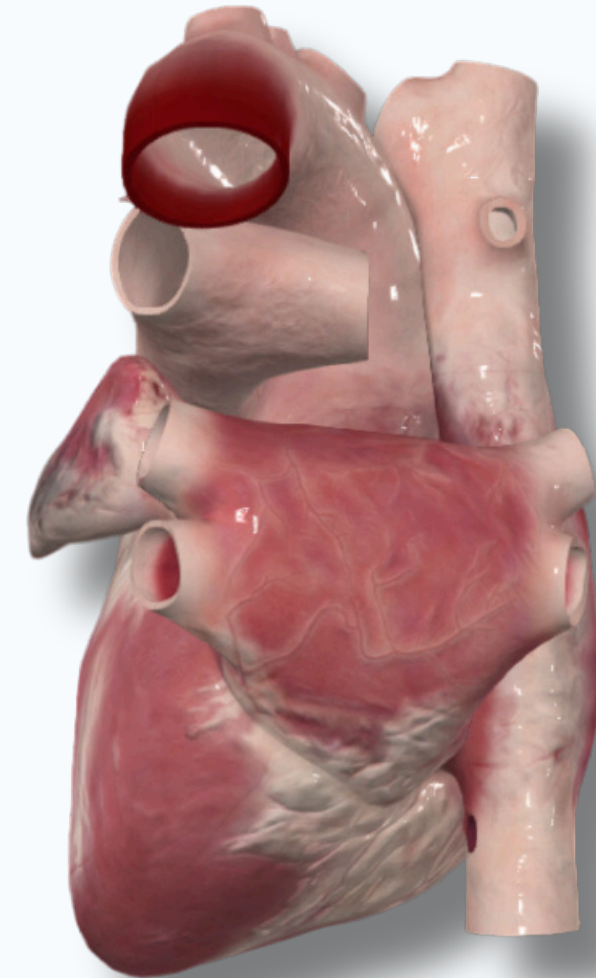


THE HEART

INTRODUCTION



Anterior

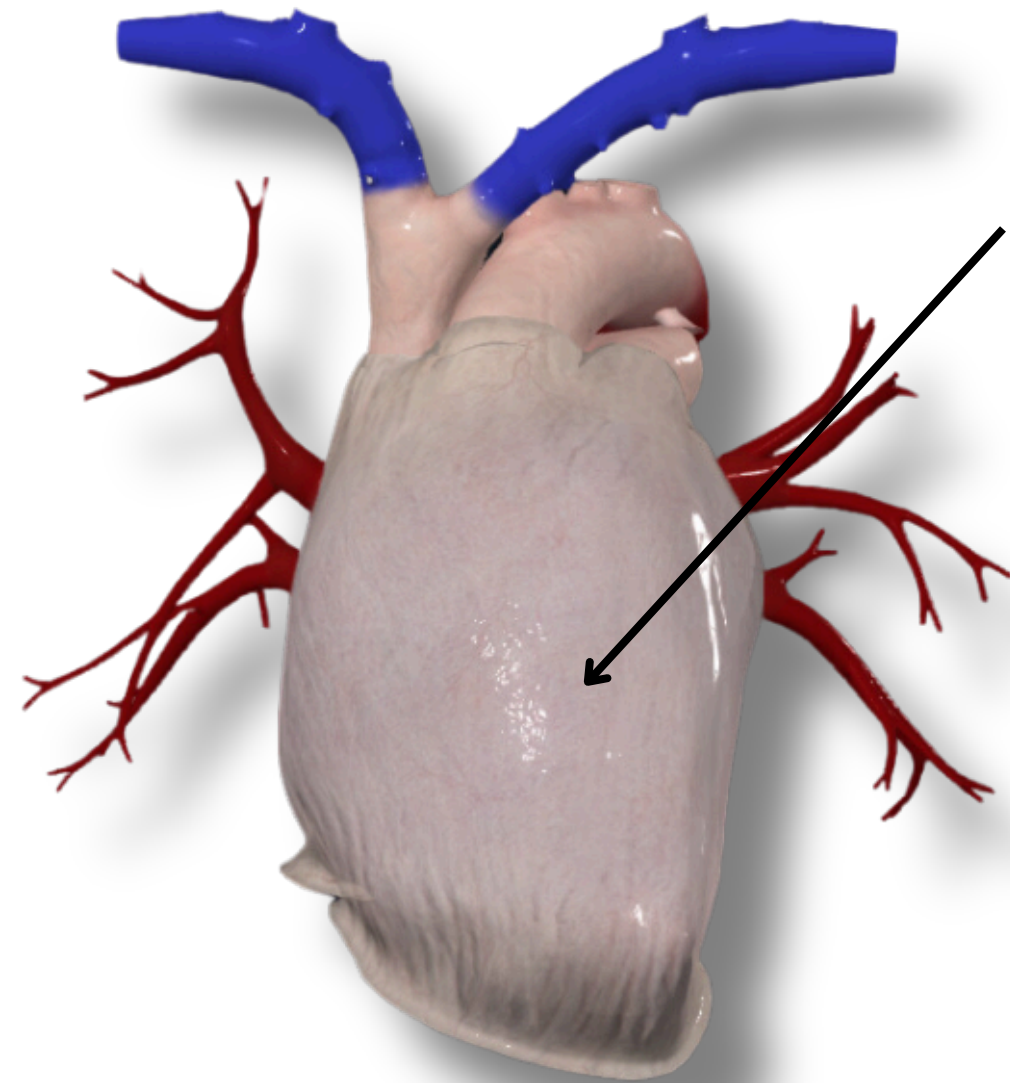
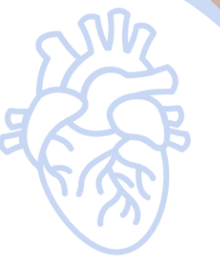

Posterior

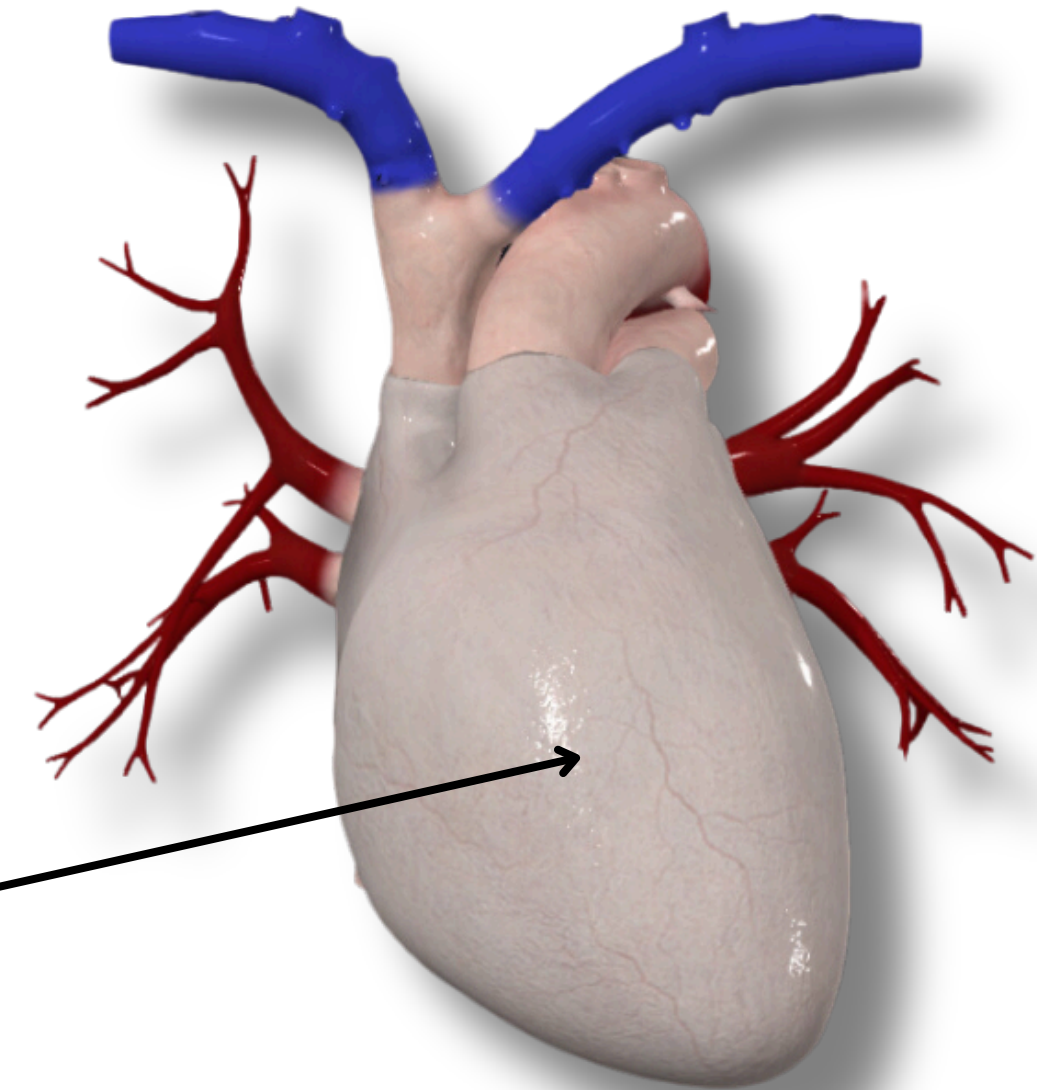


THE HEART

INTRODUCTION



Fibrous Pericardium



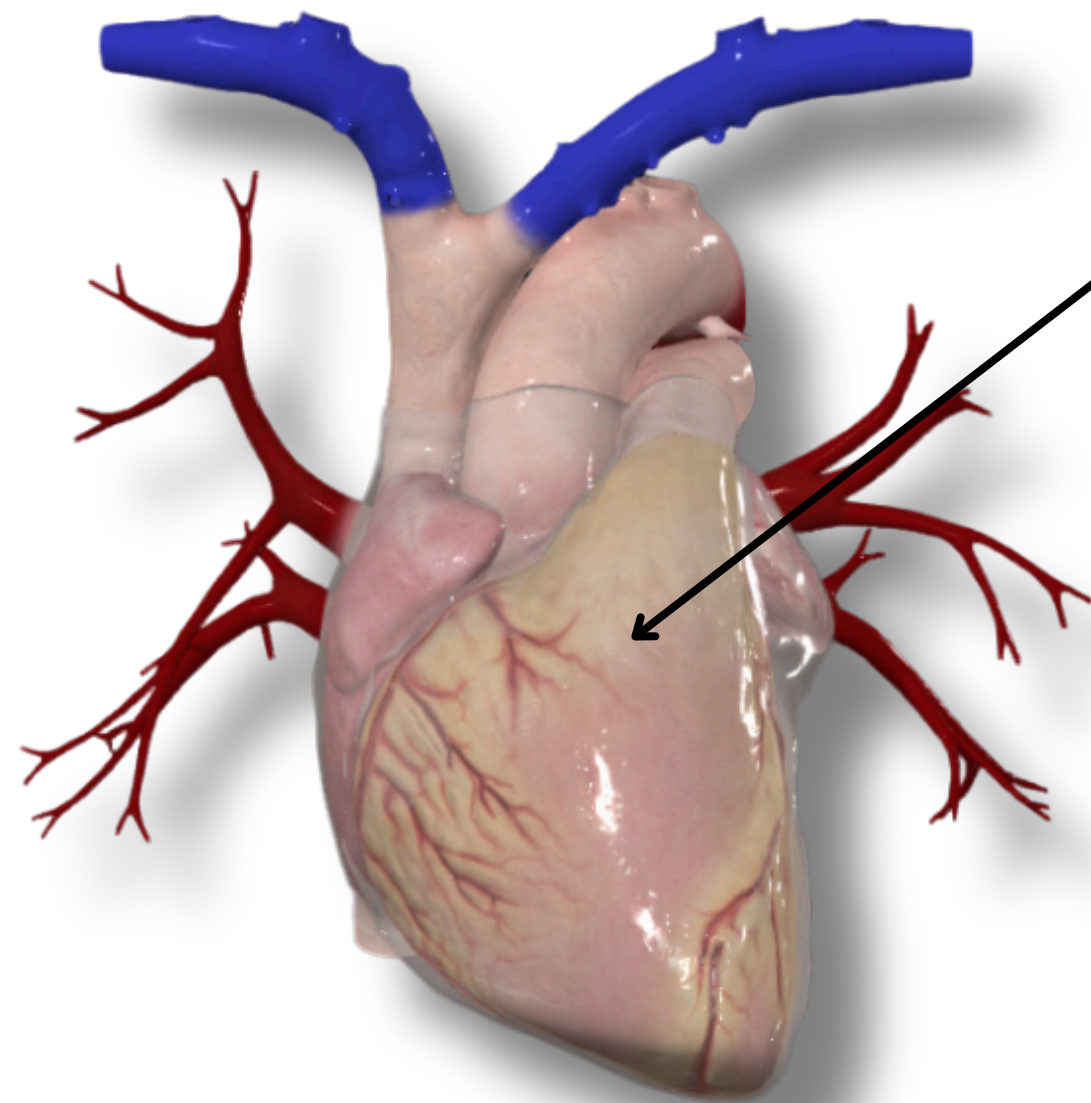
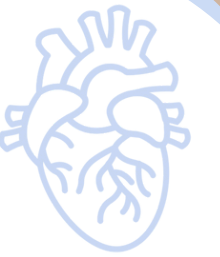Parital Pericardium

Anterior

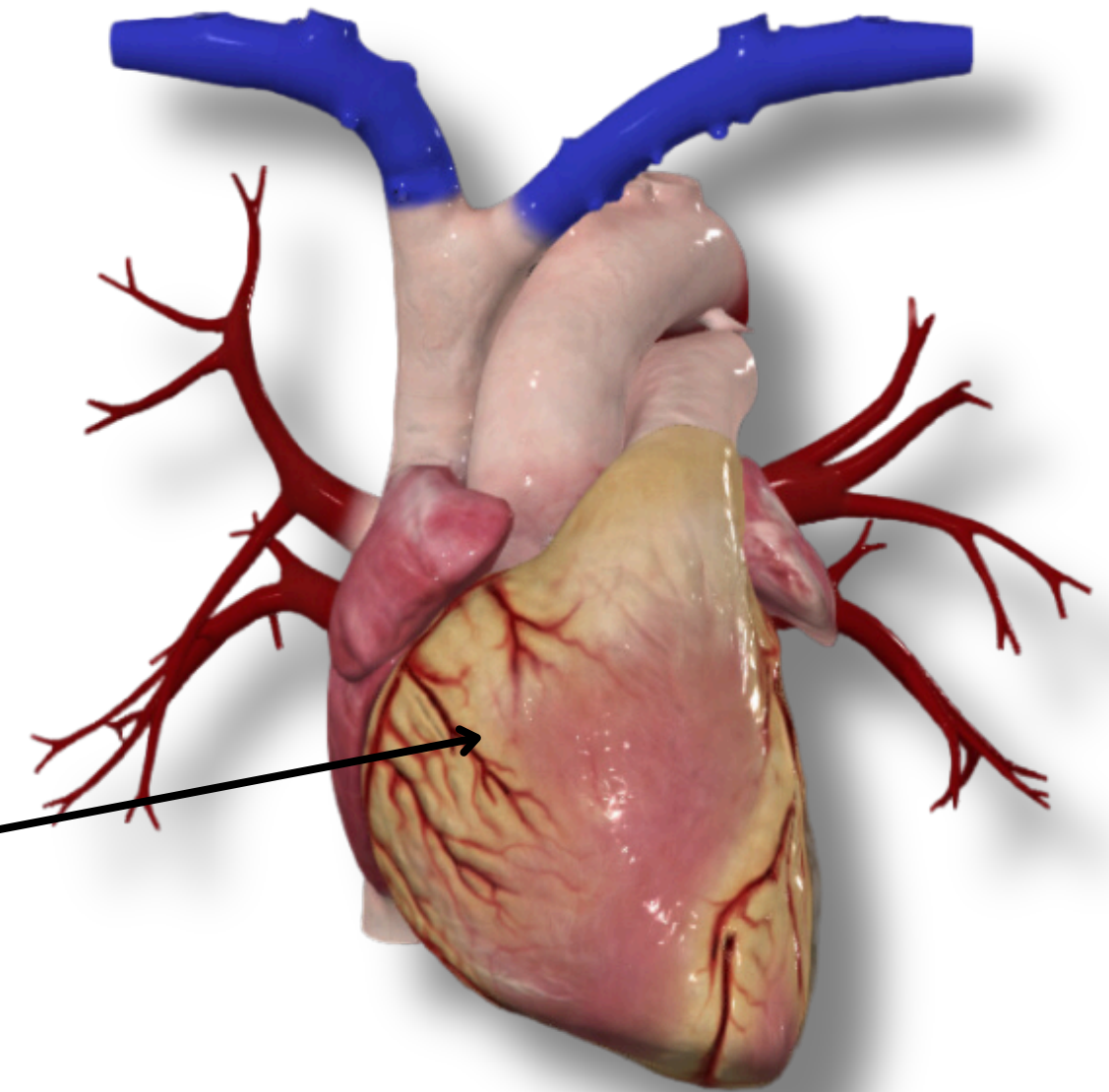


THE HEART

INTRODUCTION



Visceral Pericardium



Epicardial Adipose Tissue

Anterior



THE HEART

INTRODUCTION



**Auricle of
Right Atrium**

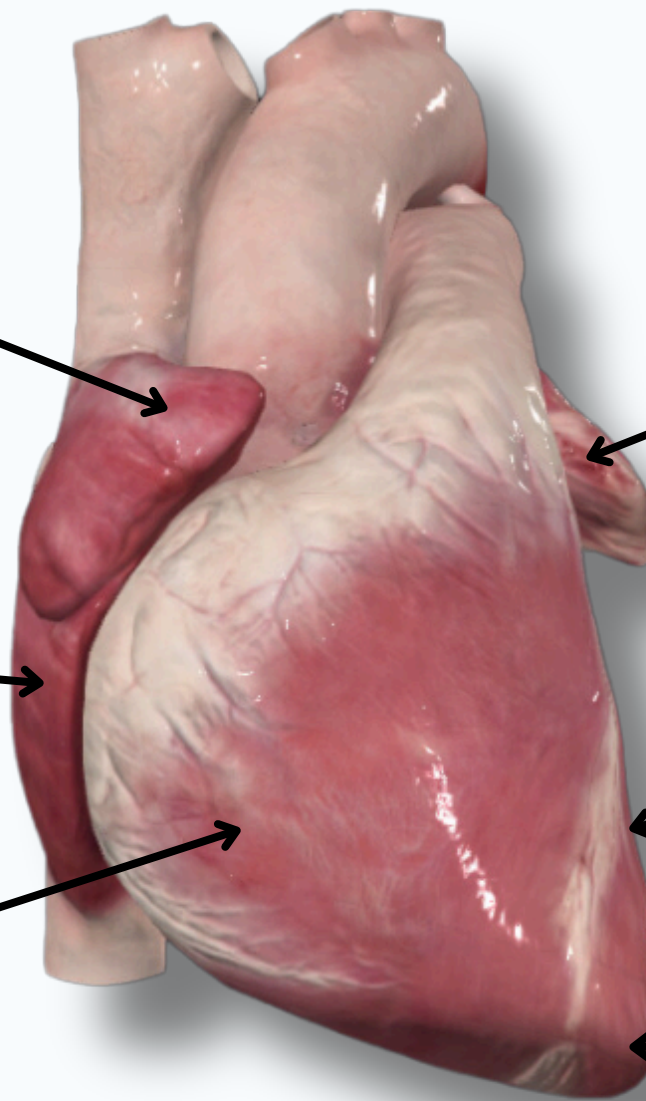
**Auricle of
Left Atrium**

Right Atrium

Left Ventricle

Right Ventricle

Apex of The Heart
Located at The Level of **5th**
Intercostal Space

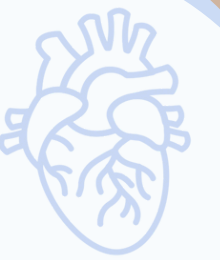

Anterior



THE HEART

INTRODUCTION

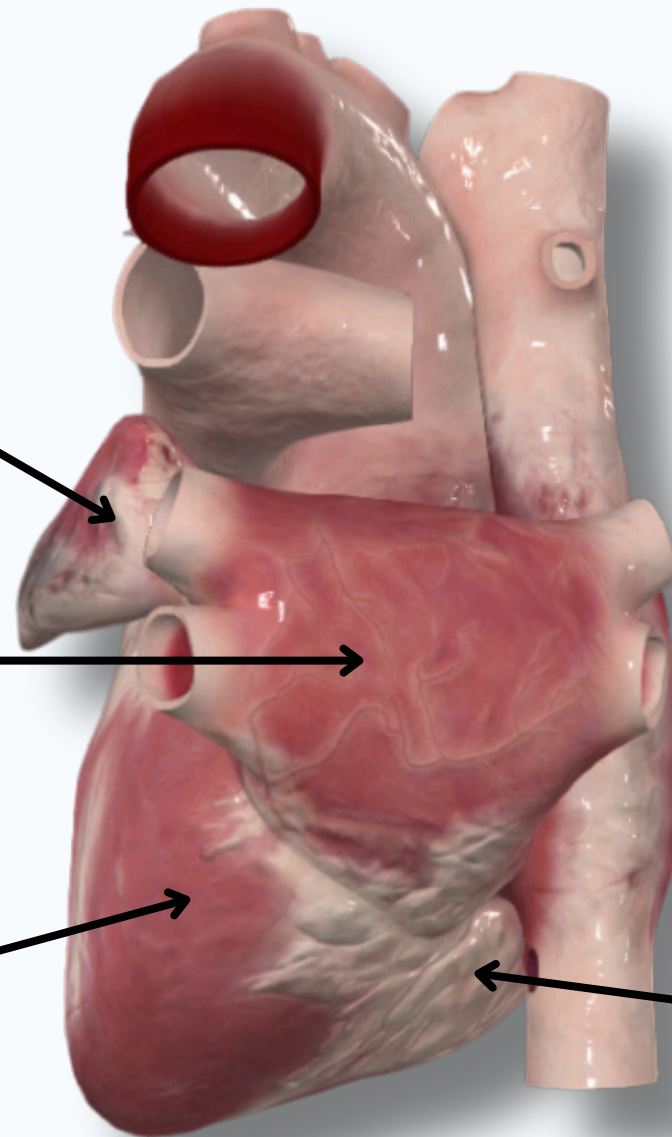


**Auricle of
Left Atrium**

Left Atrium

Left Ventricle

Right Ventricle

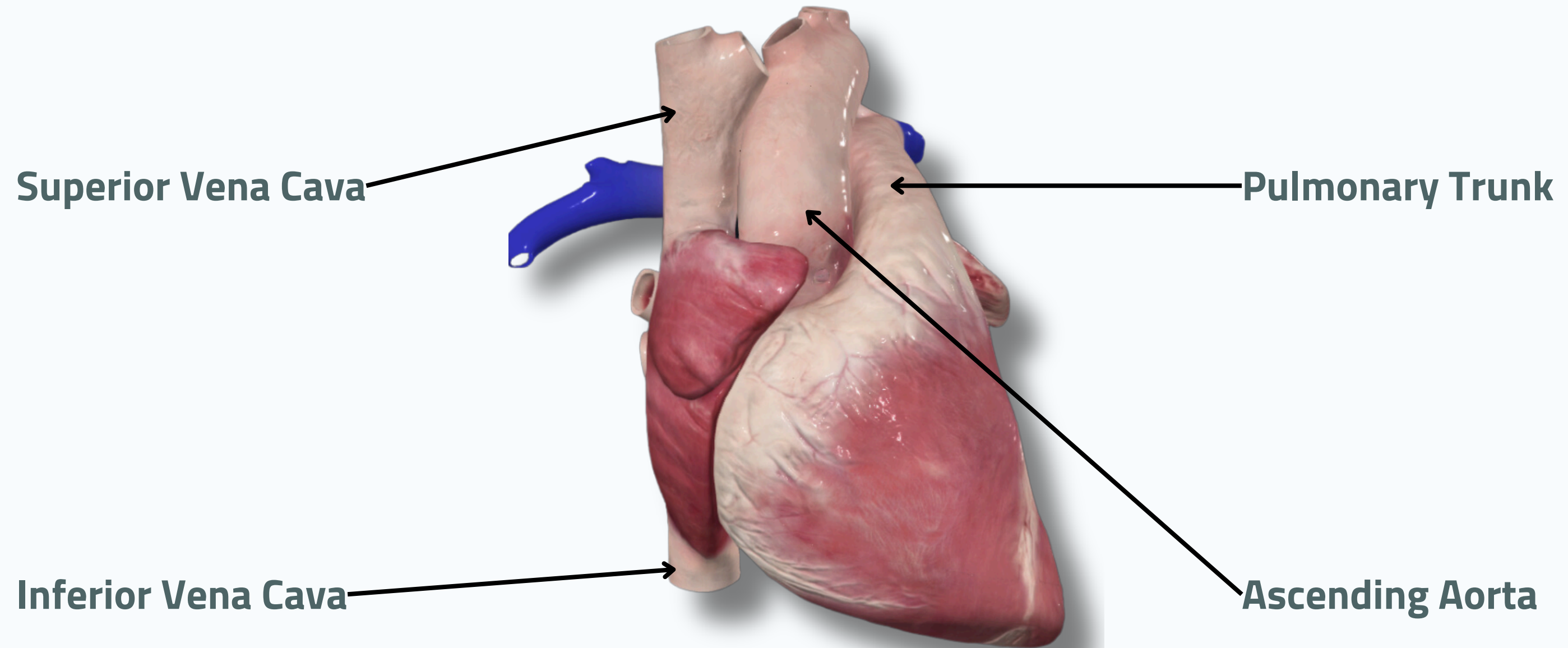


Posterior



THE HEART

INTRODUCTION



Superior Vena Cava

Pulmonary Trunk

Inferior Vena Cava

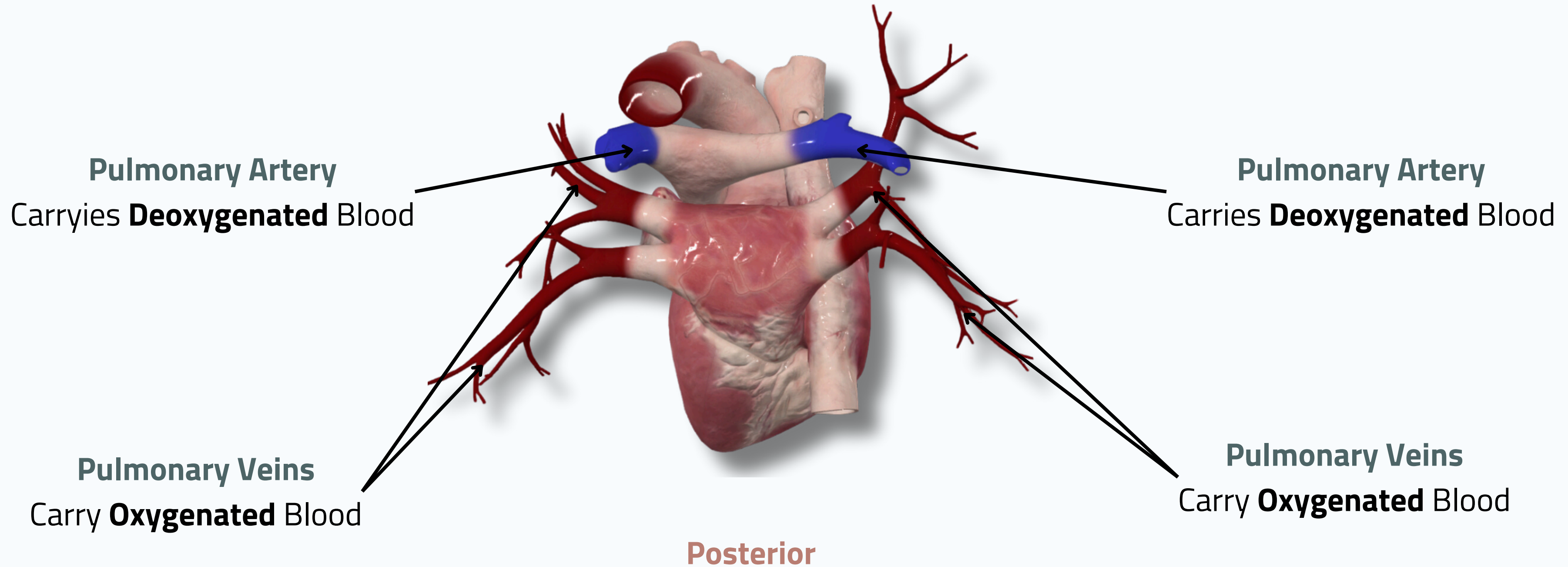
Ascending Aorta

Anterior



THE HEART

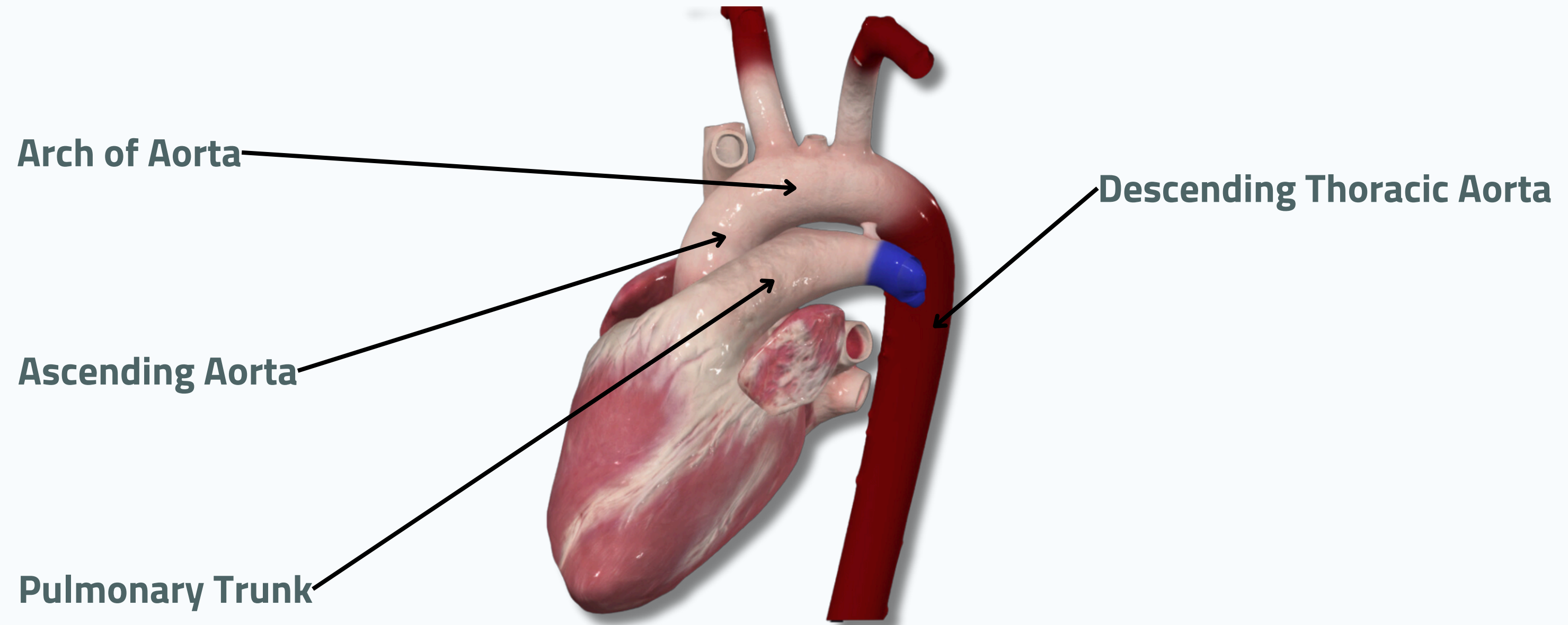
INTRODUCTION





THE HEART

INTRODUCTION



Lateral



THE HEART

INTRODUCTION



Right Common Carotid Artery

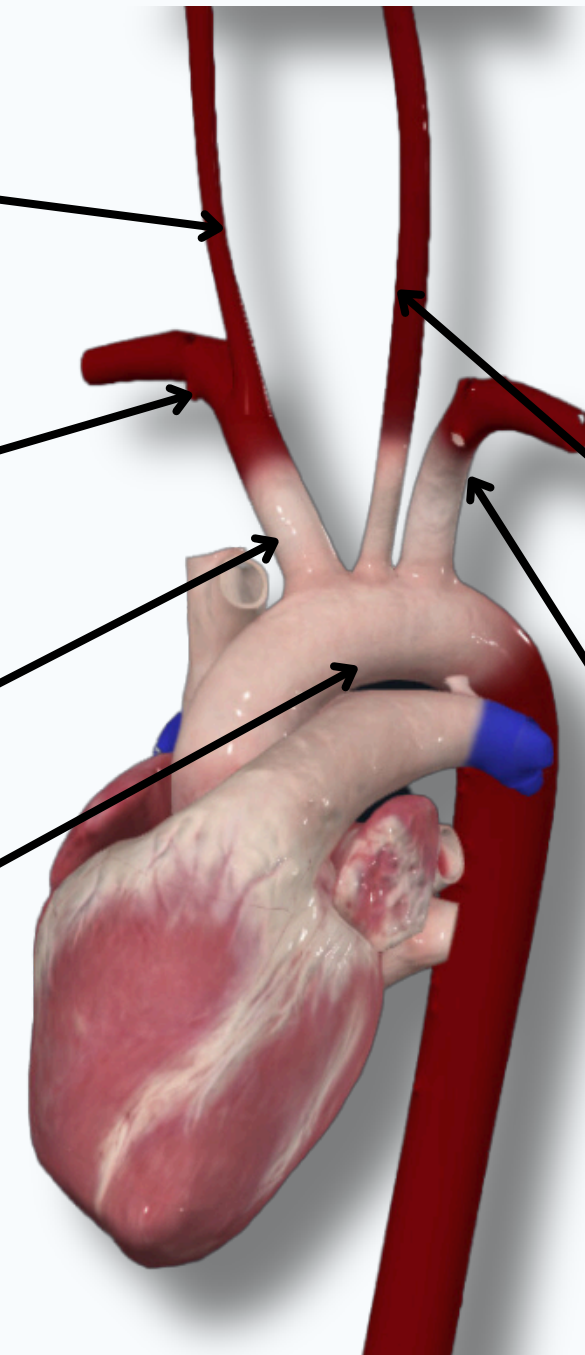
Right Subclavian Artery

Brachiocephalic Trunk

Arch of Aorta

Left Common Carotid Artery

Left Subclavian Artery

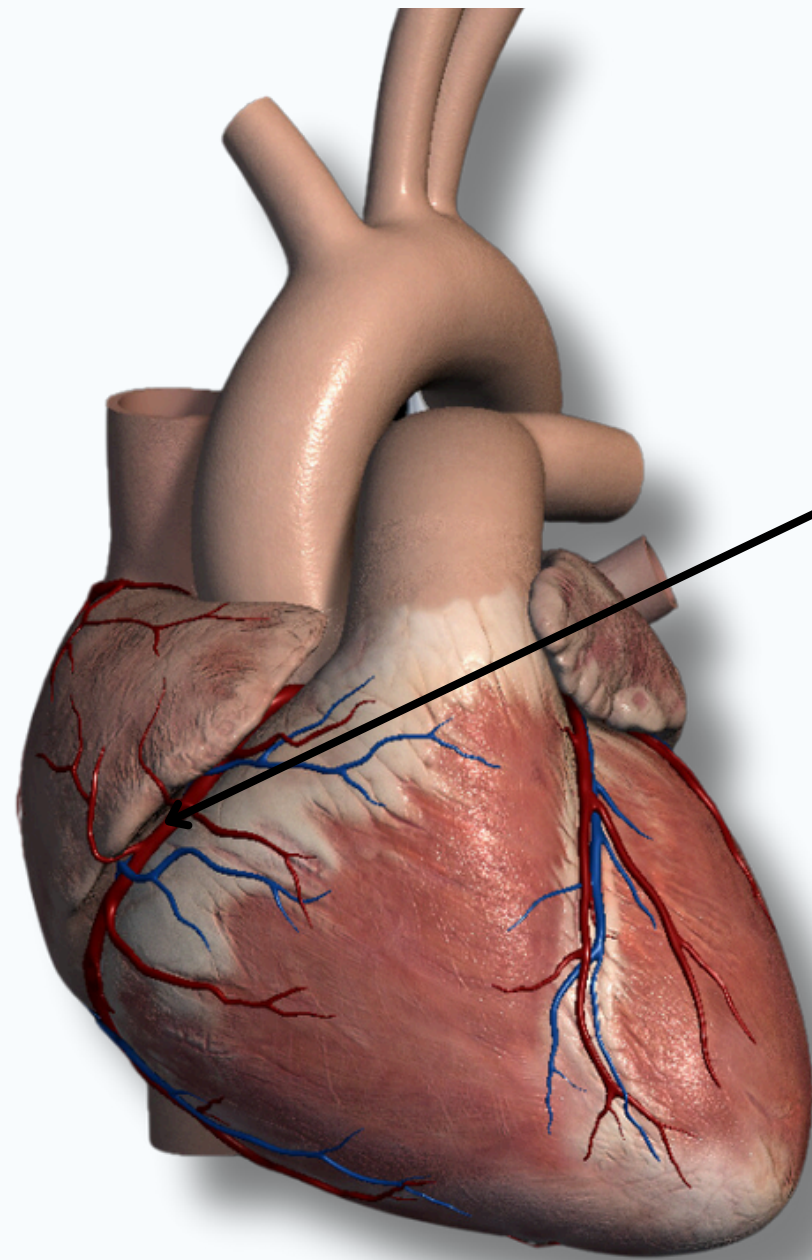


Lateral



THE HEART

BLOOD SUPPLY OF THE HEART

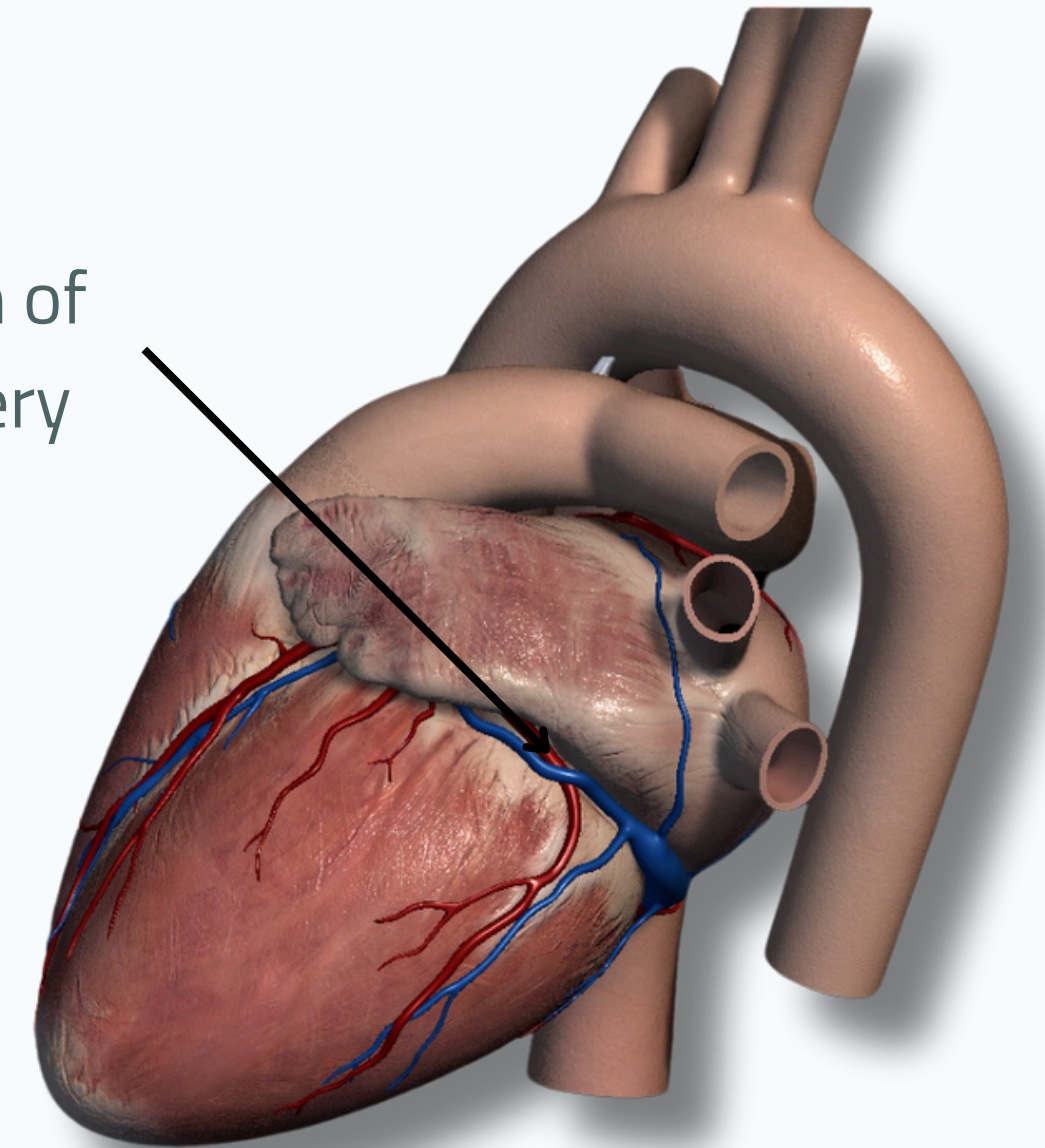


Right Coronary Artery

It arises from the anterior aortic sinus

Anterior

Circumflex Branch of Left Coronary Artery



Posterior



THE HEART

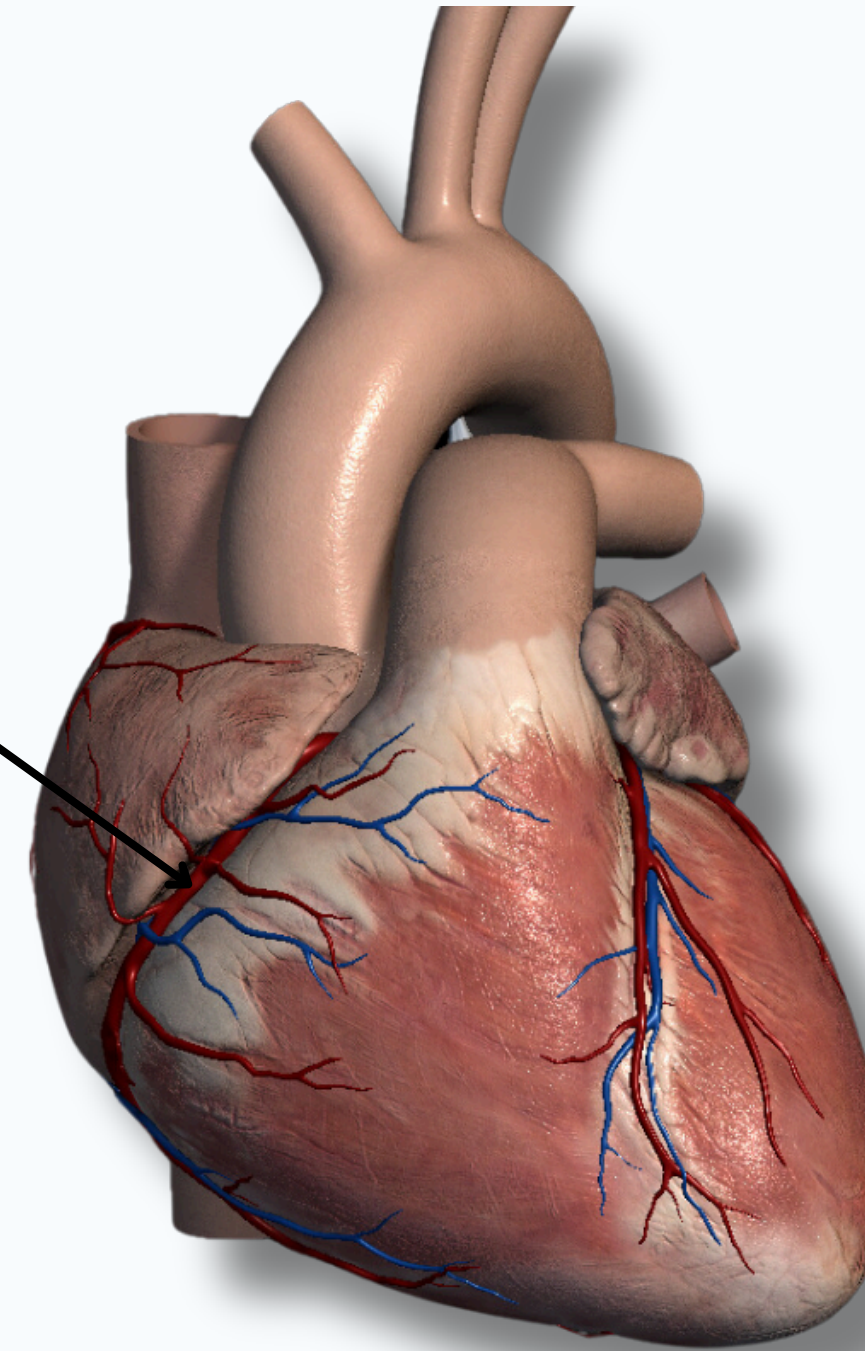


BLOOD SUPPLY OF THE HEART

Right Coronary Artery

Branches Include :-

1. Anterior Atrial branches
2. Anterior Ventricular branches
3. Posterior Atrial & Ventricular branches
4. Posterior Interventricular artery:
in the posterior interventricular sulcus
5. AV nodal branch



Anterior



THE HEART

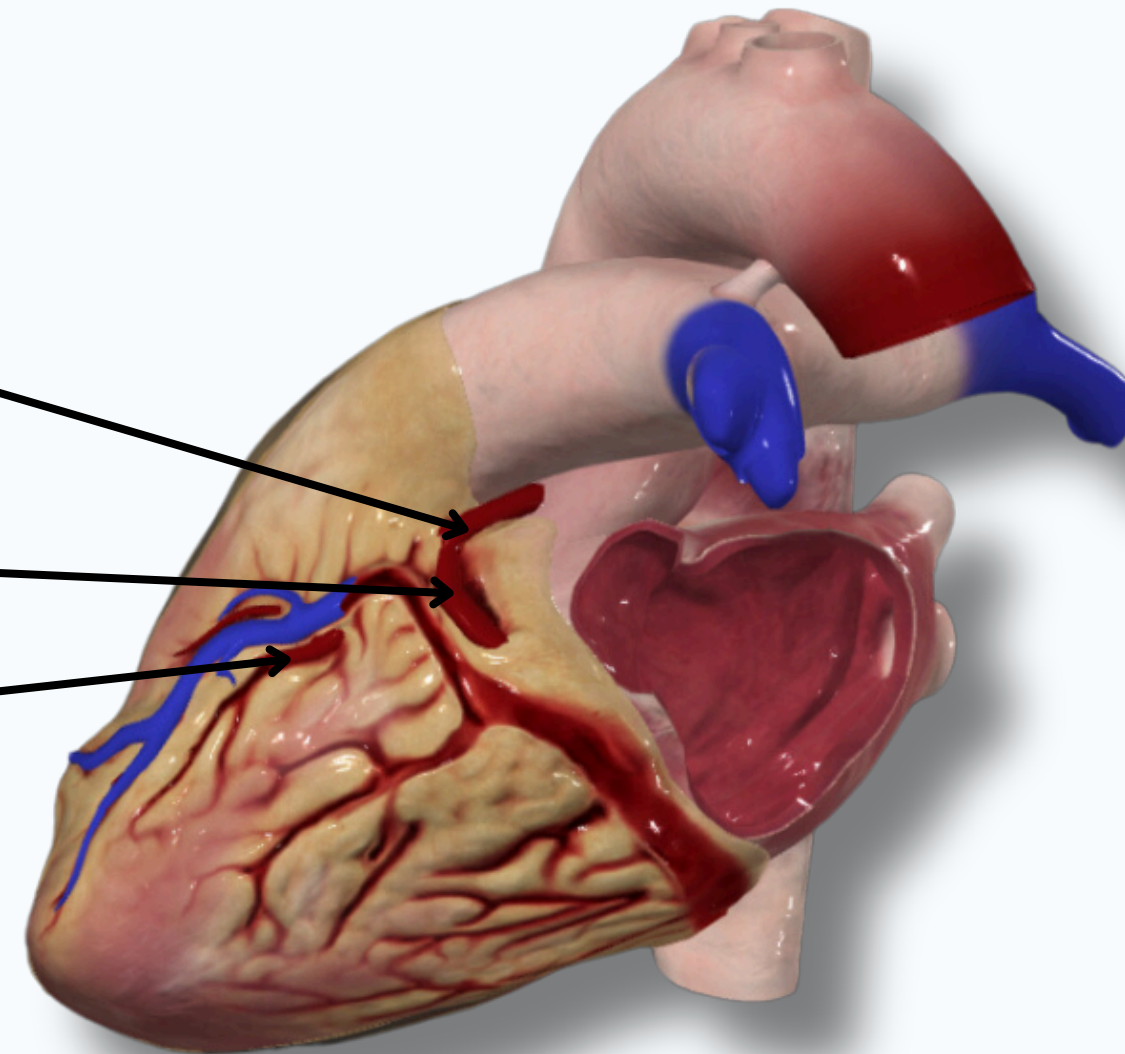


BLOOD SUPPLY OF THE HEART

Left Coronary Artery
Branches Include :-

1.Circumflex Branch

2.Anterior Interventricular



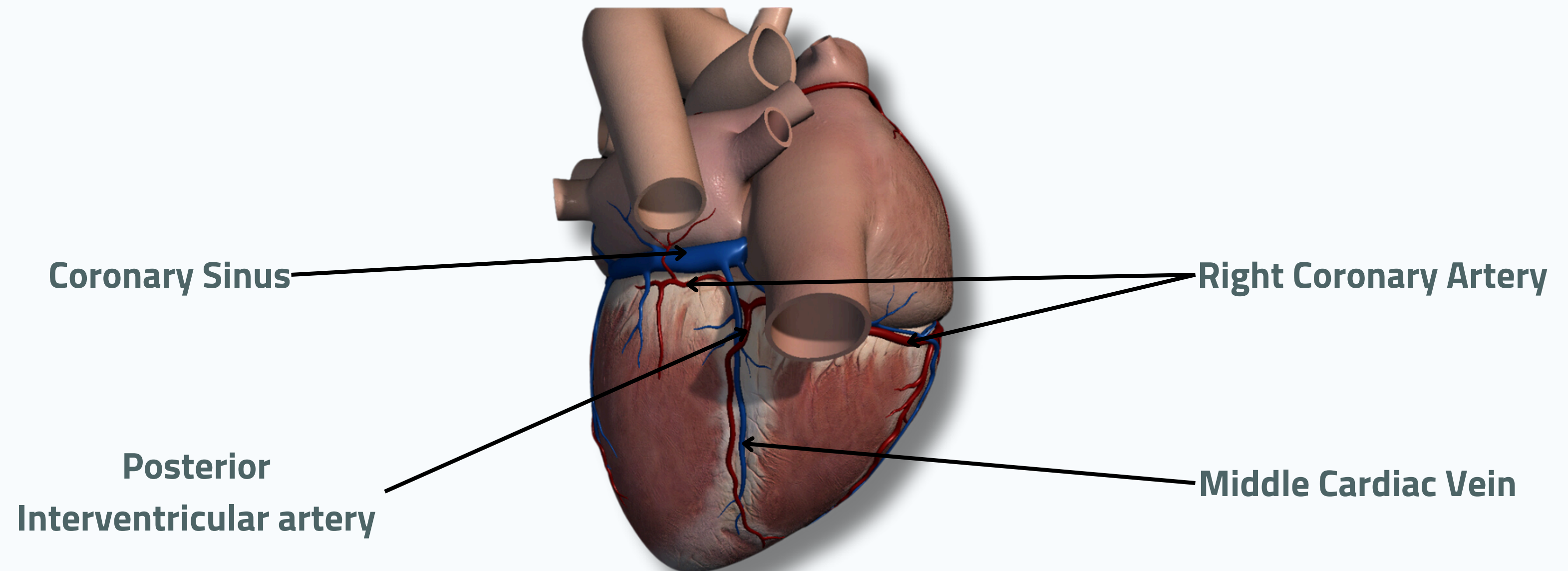
Lateral



THE HEART



BLOOD SUPPLY OF THE HEART



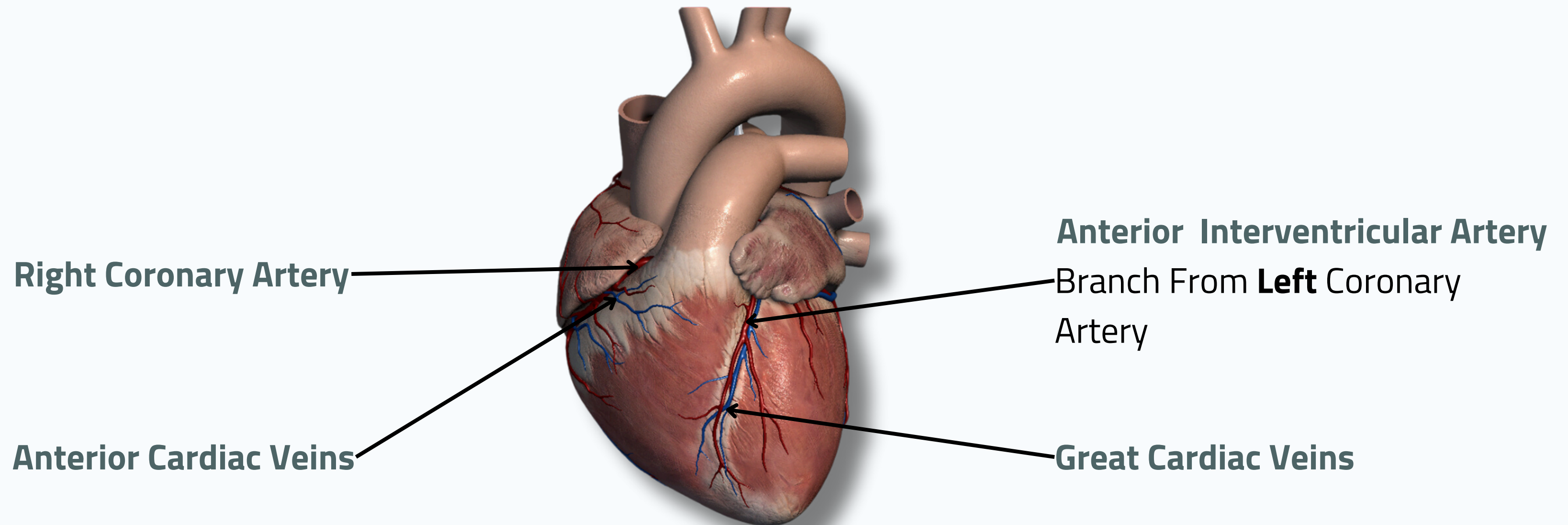
Posterior



THE HEART



BLOOD SUPPLY OF THE HEART



Right Coronary Artery

Anterior Interventricular Artery

Branch From **Left** Coronary Artery

Anterior Cardiac Veins

Great Cardiac Veins

Anterior

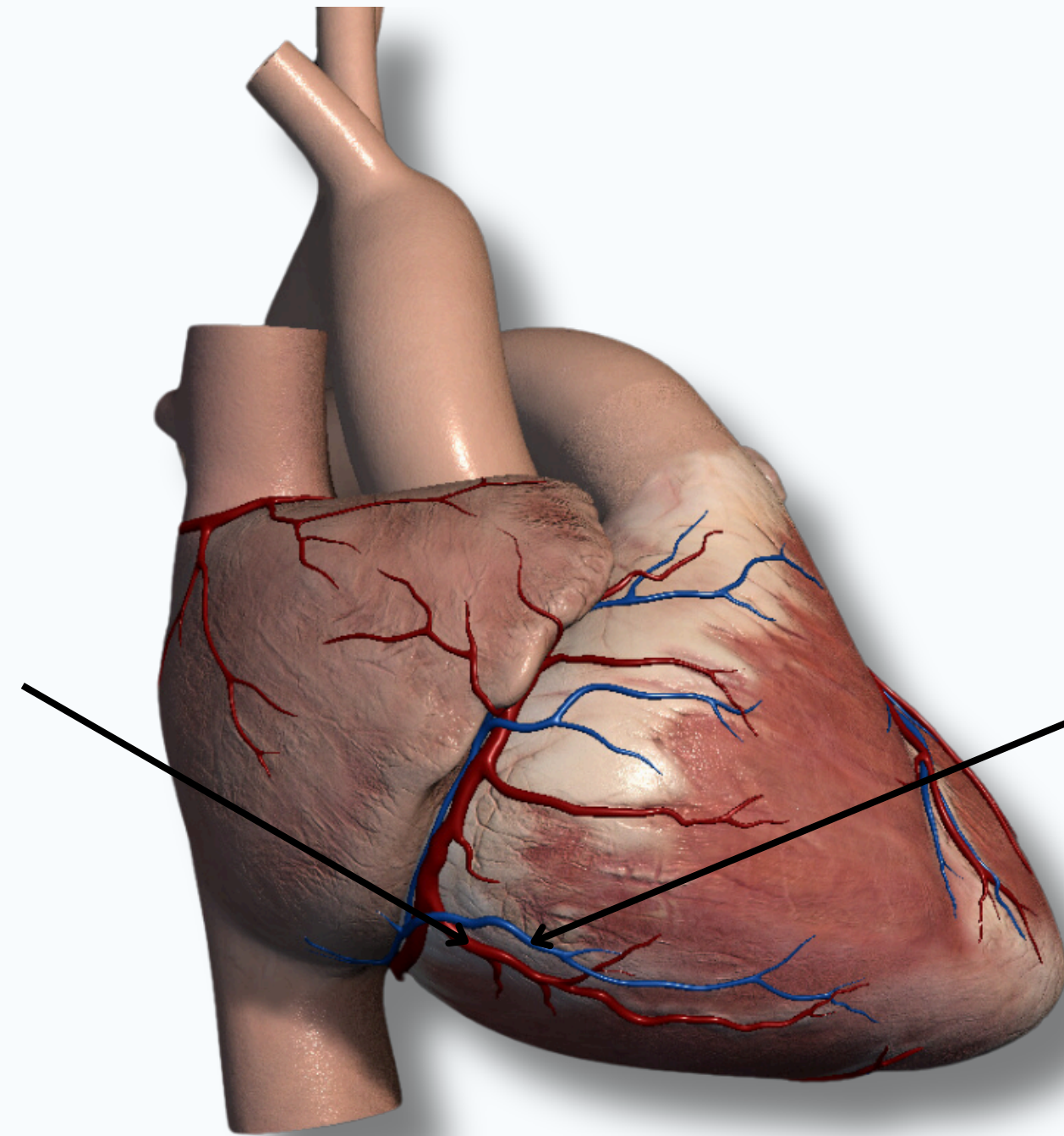


THE HEART



BLOOD SUPPLY OF THE HEART

Right Marginal Artery
Branch From **Right** Coronary
Artery



Small Cardiac Veins

Medial

THANK YOU

EDITED BY



SATURN
MEDIC



ARECH

© ALL COPYRIGHT ARE RESERVED FOR
SATURN MEDIC AND ARECH

WWW.SATURNMEDIC.COM